



**PATIENT**

Lux Medsker

**SPECIES**

Canine

**BREED**

Boxer

**SEX**

Neutered male

**AGE**

8 years

**WEIGHT**

28.2 lbs

**INTERPRETED BY**

Eric Lindquist, DMV  
DABVP, Cert. IVUSS

**IMAGING PERFORMED BY**

Dr. Seyler

**HOSPITAL NAME**

Wilvet South

**REFERRING VET**

Dr. Seyler

**INVOICE**

42677

**DATE**

2/9/23

**PRESENTING CLINICAL SIGNS**

History: P about 3 days ago got into recycling (got into a chicken broth box), does have a history of getting into the trash but usually throws up after and hasn't done that yet. Last 3 days has been lethargic, last 2 days no BM, Yesterday noticed breathing seemed to be a little more difficult for P.

**ULTRASONOGRAPHIC EXAMINATION**

**12 videos were submitted of intercostal views**

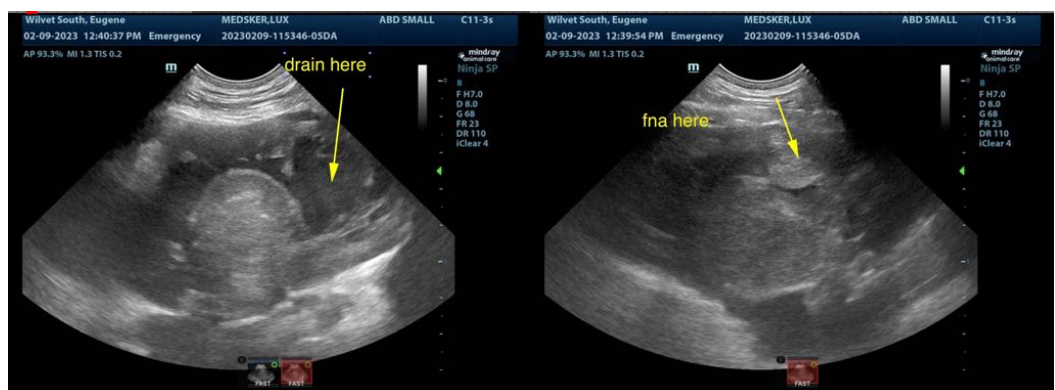
A large cystic, extensive, parenchymal component was noted. This appears to be of lung origin; however, peripheral air was not able to be observed. Approximately 50% of the mass is parenchymal and the rest is fluid filled. The mass appears to impinge upon the heart, yet is not deriving from it.

**ULTRASONOGRAPHIC FINDINGS**

- Cystic, extensive parenchymal component. Appears to be of lung origin. Sarcomatous type mass suspected with a mild potential for penetrating foreign body, abscessation or similar.

**INTERPRETATION OF THE FINDINGS & FURTHER RECOMMENDATIONS**

Ultrasound-guided FNA of the parenchymal portion of the mass and drainage of the cystic portions are recommended. CT evaluation is warranted to assess the extent of the mass. An abdominal sonogram is warranted to assess for comorbidities or related pathology. The prognosis is guarded to poor depending on eventual responsiveness to chemotherapy.



The information and recommendations provided are based on the images presented by the referring veterinarian/sonographer. No evaluation can be communicated regarding pathology that was not visible in the image/video clips provided.

Thank you for this referral. If the clinical or image interpretation does not parallel your findings or if I can be of any further assistance please contact me.

**Eric Lindquist**, DMV, DABVP, Cert. IVUSS, CEO of SonoPath.com  
info@SonoPath.com