



PATIENT

Rebel Cullen

PRESENTING CLINICAL SIGNS

History: asymptomatic marked bacteriuria rods intact culture pending

SPECIES

Canine

ULTRASONOGRAPHIC EXAMINATION OF THE ABDOMEN

Urinary System

The **urinary bladder** was nearly empty at the time of the sonogram. The parenchyma was uniform.

BREED

Doberman Pinscher

The prostate was enlarged with a 1.0 cm cyst at the cranial aspect of the right lobe. A second cyst measured 1.0 cm. Other nodular changes were noted through the prostate.

SEX

Male

The **kidneys** revealed normal size and structure, corticomedullary definition and ratio for this age. The cortices presented largely uniform texture with normal echogenic relationship to liver and spleen. Medullary structure differed distinctly from the cortex and no evidence of pelvic dilation was present. The capsules were acceptably uniform without significant irregularities. The left kidney measured 6.5 cm. The right kidney measured 6.5 cm.

AGE

8 years

ULTRASONOGRAPHIC FINDINGS

BPH prostate with cysts or abscesses. Nodular parenchymal changes. Potentially neoplastic, yet unlikely.

WEIGHT

62.2 lbs

INTERPRETATION OF THE FINDINGS & FURTHER RECOMMENDATIONS

Ultrasound-guided FNA of the abnormal parenchyma and drainage of the cystic portions with culture indicated. Neutering is likely in this patient's best interest.

INTERPRETED BY

Eric Lindquist, DMV
DABVP, Cert. IVUSS

IMAGING PERFORMED BY

Dr. Barnea

HOSPITAL NAME

Tenafly VC

REFERRING VET

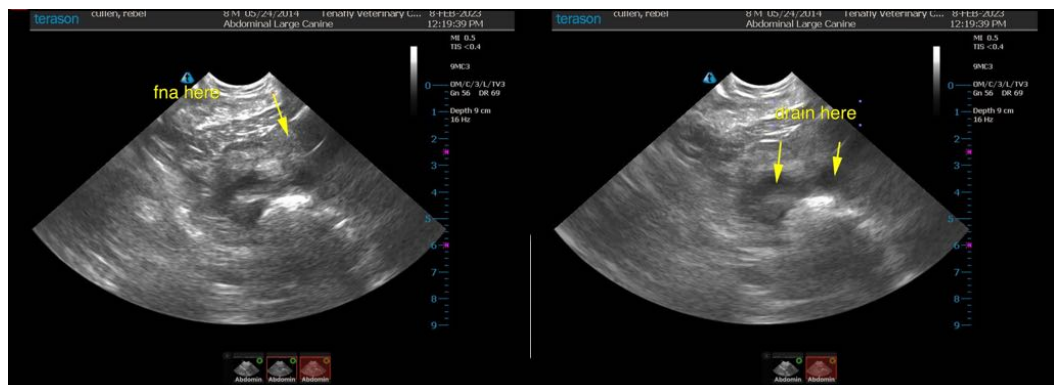
Dr. Barnea

INVOICE

42661

DATE

2/8/23





PATIENT

Rebel Cullen

SPECIES

Canine

BREED

Doberman Pinscher

SEX

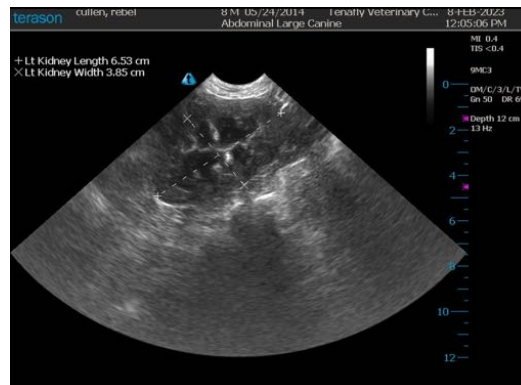
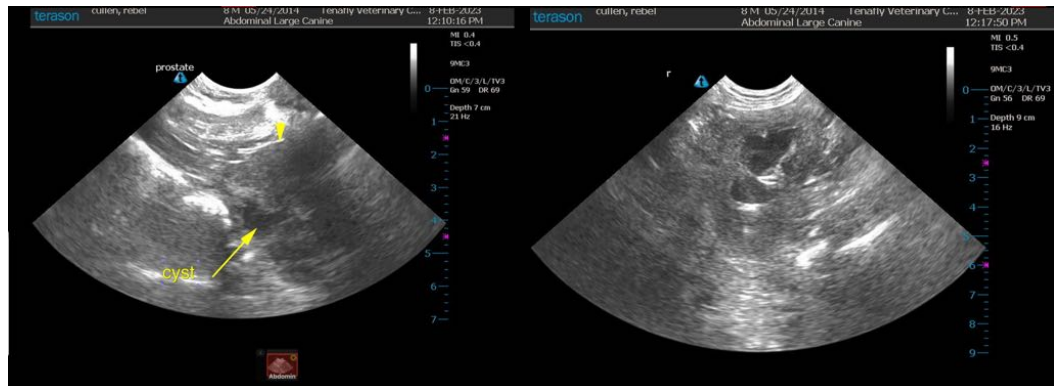
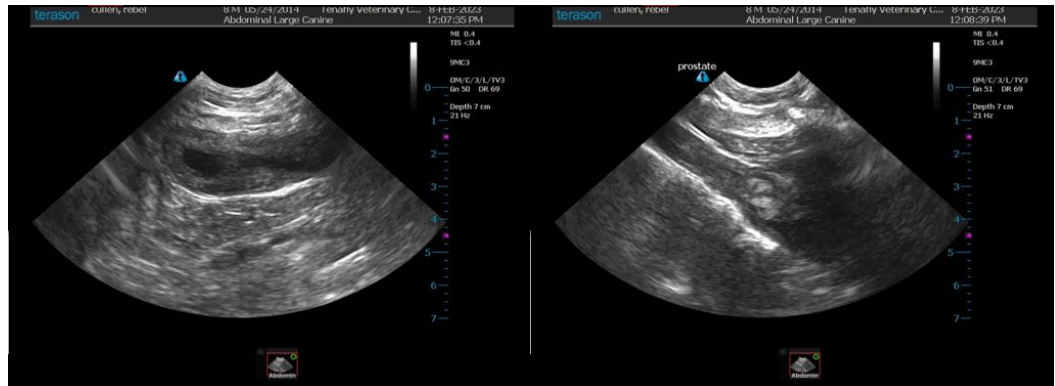
Male

AGE

8 years

WEIGHT

62.2 lbs



INTERPRETED BY

Eric Lindquist, DMV
DABVP, Cert. IVUSS

IMAGING PERFORMED BY

Dr. Barnea

HOSPITAL NAME

Tenafly VC

REFERRING VET

Dr. Barnea

INVOICE

42661

DATE

2/8/23

The information and recommendations provided are based on the images presented by the referring veterinarian/sonographer. No evaluation can be communicated regarding pathology that was not visible in the image/video clips provided.

Thank you for this referral. If the clinical or image interpretation does not parallel your findings or if I can be of any further assistance please contact me.

Eric Lindquist, DMV, DABVP, Cert. IVUSS, CEO of SonoPath.com
info@SonoPath.com