



PATIENT

Harley Capp

SPECIES

Feline

BREED

Domestic Shorthair

SEX

Spayed female

AGE

13 years

WEIGHT

3.9 lbs

INTERPRETED BY

Eric Lindquist, DMV
DABVP, Cert. IVUSS

IMAGING PERFORMED BY

Dr. Roche

HOSPITAL NAME

Fredon AH

REFERRING VET

Dr. Roche

INVOICE

42663

DATE

2/8/23

PRESENTING CLINICAL SIGNS

History: Previously diagnosed as IBD cat, recent decline despite steroids and B12. Poor appetite and watery diarrhea. Did eat wet food prior to scan today not fasted.
Abnormal PE/Chem/CBC/UA Results: BCS 2/9 mod-severe dehydration. Bw pending.

ULTRASONOGRAPHIC EXAMINATION OF THE ABDOMEN

Urinary System

The **urinary bladder**, trigone, and pelvic urethra presented normal thicknesses and normal tone. The ureters were not visible which is normal. No uroliths or sediment were visualized and anechoic urine was present. No evidence of inflammatory or neoplastic changes was noted. Ureteral papillae were normal.

The **kidneys** revealed largely normal size and structure, corticomedullary definition and ratio (cortex 1/3 of medulla) were essentially maintained with some age-related loss of curvilinear patterns regarding the capsule and C/M junction. The cortices presented largely uniform texture with some increased echogenicity expected for his age patient. Medullary structure differed distinctly from that of the cortex and no evidence of pelvic dilation was present. The left kidney measured 3.5 cm. The right kidney measured 3.75 cm.

Adrenal Glands

Both **adrenal glands** were visualized and recognized as having normal shape, size, position and echogenicity for this breed. The phrenic vasculature, glandular echogenicity and detail were unremarkable. Capsule, cortex, and medullary definition were normal for this age patient.

Spleen

The **spleen** presented a smooth homogeneous parenchyma hyperechoic to liver and renal cortical parenchyma. The capsule was smooth without noticeable expansion or deviation from within the spleen or adjacent pathology. The splenic vasculature demonstrated normal volume without signs of congestion or thrombosis. No sonographic evidence of acute or chronic inflammatory, neoplastic, or infarctual changes was noted.

Liver

The **liver** images submitted revealed subjectively normal liver size, contour, and structure. Parenchymal echogenicity was naturally coarse and hypoechoic to the spleen. Vascular and biliary tracts were of normal volume with no evidence of congestion. The gallbladder presented acceptably thin walls with primarily anechoic content. The cystic and common bile ducts were normal. No pathological hepatic lymphadenopathy was evident. No overt structural evidence of inflammatory, infiltrative or regenerative pathology was evident.



PATIENT

Gastrointestinal

Harley Capp

The **gastrointestinal tract** appeared to have subjective mural thickening with hyperperistalsis. Transit of chyme appeared to be normal. Some chyme and shadowing ingesta was noted in the stomach.

SPECIES

Feline

Pancreas

BREED

Domestic Shorthair

The base and limbs of the **pancreas** were observed to be largely isoechoic to surrounding omental fat. Some parenchymal remodeling, however, with mild deviation from curvilinear normalcy was observed. Pancreatic duct and capsular irregularities were present consistent with age related changes. If pain upon imaging (+ Murphy sign) was present or if the patient is focally painful in subxiphoid palpation then low-grade smoldering chronic pancreatitis should be suspected.

SEX

Spayed female

ULTRASONOGRAPHIC FINDINGS

Gastrointestinal thickening and hyperperistalsis.

AGE

13 years

INTERPRETATION OF THE FINDINGS & FURTHER RECOMMENDATIONS

There was no evidence of neoplasia. The prednisone therapy could be suppressing a more significant presentation. However, malassimilation of nutrients is a strong potential in this case. Otherwise, the changes are suspected for this age and patient.

INTERPRETED BY

Eric Lindquist, DMV
DABVP, Cert. IVUSS

IMAGING PERFORMED BY

Dr. Roche

HOSPITAL NAME

Fredon AH

REFERRING VET

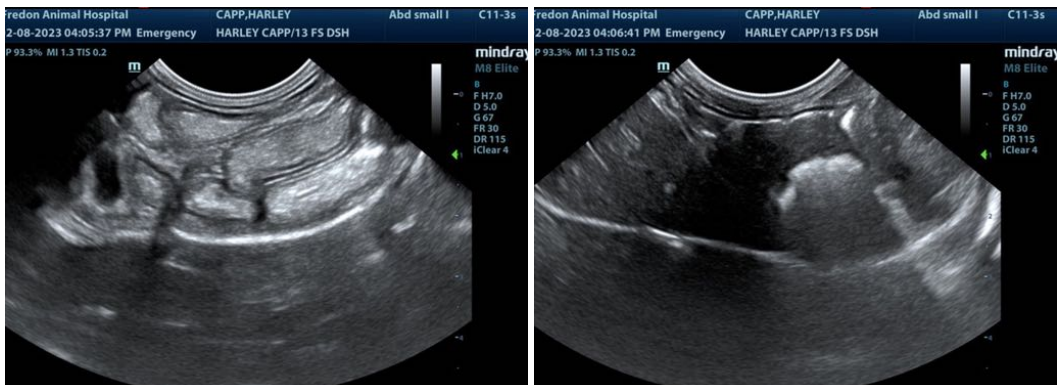
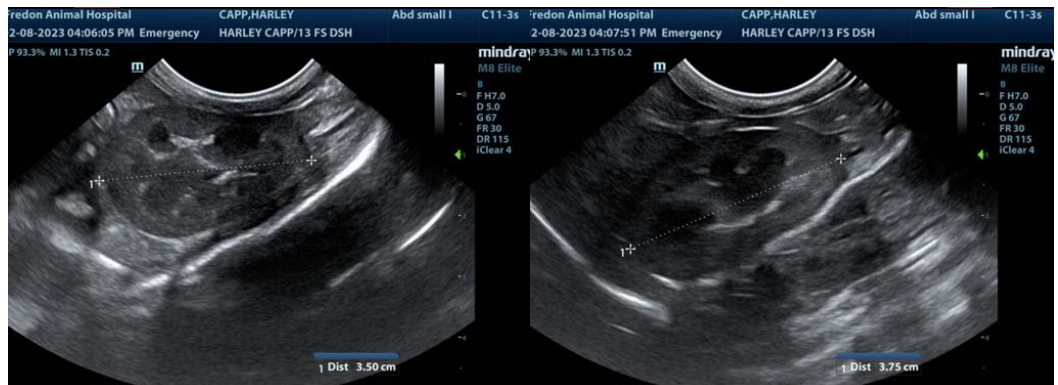
Dr. Roche

INVOICE

42663

DATE

2/8/23





PATIENT

Harley Capp

SPECIES

Feline

BREED

Domestic Shorthair

SEX

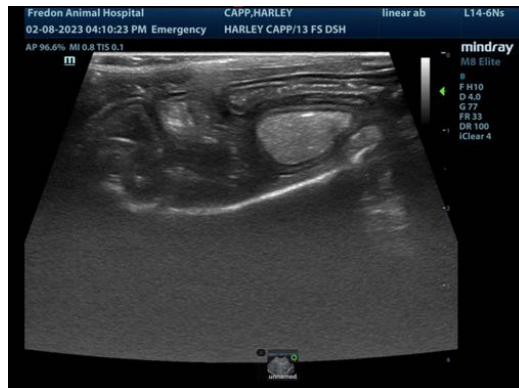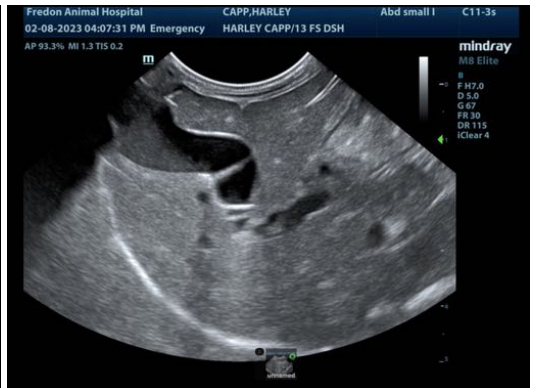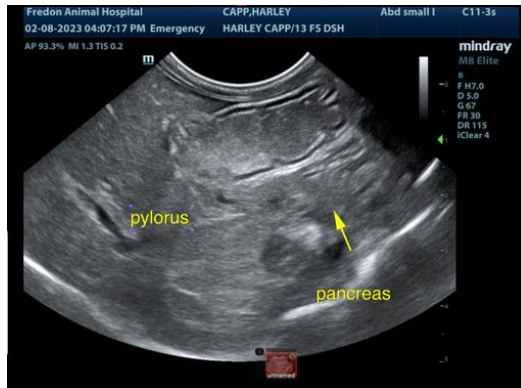
Spayed female

AGE

13 years

WEIGHT

3.9 lbs



INTERPRETED BY

Eric Lindquist, DMV
DABVP, Cert. IVUSS

IMAGING PERFORMED BY

Dr. Roche

HOSPITAL NAME

Fredon AH

REFERRING VET

Dr. Roche

INVOICE

42663

DATE

2/8/23

The information and recommendations provided are based on the images presented by the referring veterinarian/sonographer. No evaluation can be communicated regarding pathology that was not visible in the image/video clips provided.

Thank you for this referral. If the clinical or image interpretation does not parallel your findings or if I can be of any further assistance please contact me.

Eric Lindquist, DMV, DABVP, Cert. IVUSS, CEO of SonoPath.com
info@SonoPath.com