



**PATIENT**

**PRESENTING CLINICAL SIGNS**

Bood Radley McGuire

History: recheck prev u/s on 2/6 showed chronic interstitial nephrosis pattern delayed gastric ileus pattern with structural obstruction

**SPECIES**

Feline

**ULTRASONOGRAPHIC EXAMINATION**

**Gastrointestinal**

**BREED**

Domestic Shorthair

The **gastrointestinal tract** was empty with normal curvilinear patterns. There was no evidence of obstruction. The colon revealed normal stool consistency.

**SEX**

Neutered male

**ULTRASONOGRAPHIC FINDINGS**

Normalized GI tract.

**AGE**

10 years

**INTERPRETATION OF THE FINDINGS & FURTHER RECOMMENDATIONS**

There was no evidence of pathology.

**WEIGHT**

8.4 lbs

**INTERPRETED BY**

Eric Lindquist, DMV  
DABVP, Cert. IVUS

**IMAGING PERFORMED BY**

Jenn

**HOSPITAL NAME**

Rockaway AH

**REFERRING VET**

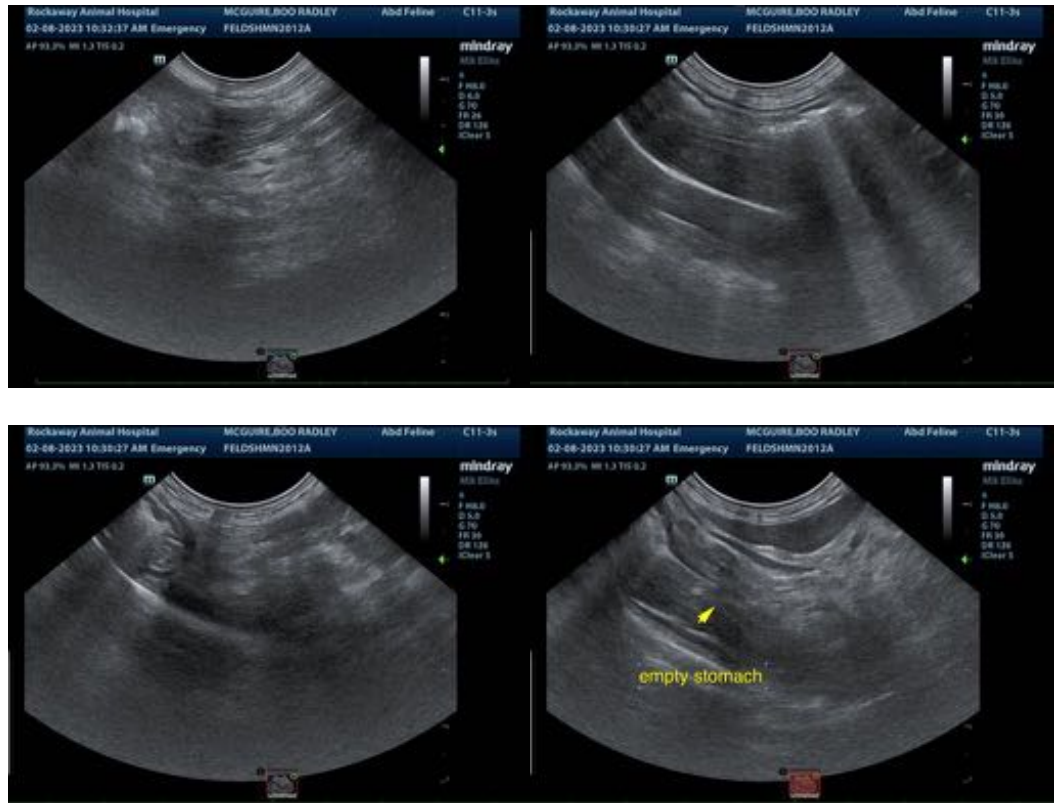
Dr. Maniar

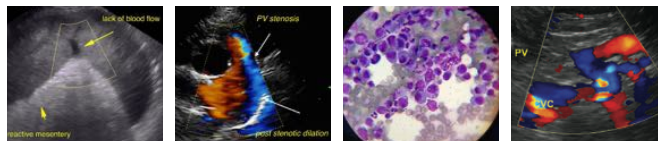
**INVOICE**

42647

**DATE**

2/8/23





**PATIENT**

Bood Radley McGuire

The information and recommendations provided are based on the images presented by the referring veterinarian/sonographer. No evaluation can be communicated regarding pathology that was not visible in the image/video clips provided.

**SPECIES**

Feline

Thank you for this referral. If the clinical or image interpretation does not parallel your findings or if I can be of any further assistance please contact me.

**BREED**

Domestic Shorthair

**Eric Lindquist**, DMV, DABVP, Cert. IVUSS, CEO of SonoPath.com  
info@SonoPath.com

**SEX**

Neutered male

**AGE**

10 years

**WEIGHT**

8.4 lbs

**INTERPRETED BY**

Eric Lindquist, DMV  
DABVP, Cert. IVUSS

**IMAGING  
PERFORMED BY**

Jenn

**HOSPITAL NAME**

Rockaway AH

**REFERRING VET**

Dr. Maniar

**INVOICE**

42647

**DATE**

2/8/23