



**PATIENT**

Shake N Bake Manor

**SPECIES**

Canine

**BREED**

Boston Terrier

**SEX**

Neutered male

**AGE**

11 years

**WEIGHT**

10.8 kg

**INTERPRETED BY**

Eric Lindquist, DMV  
DABVP, Cert. IVUSS

**IMAGING PERFORMED BY**

Mark van Campen

**HOSPITAL NAME**

Mississippi AH

**REFERRING VET**

Dr. vanCampen

**INVOICE**

95923

**DATE**

2/8/22

**PRESENTING CLINICAL SIGNS**

Has improved greatly on medications prescribed. On trazodone for scan. Seems to cough more when trazodone used for calming.

Abnormal PE/Chem/CBC/UA Results: CBC, chem WNL, UTI last week.

**ULTRASONOGRAPHIC EXAMINATION OF THE HEART**

The echocardiogram in this patient demonstrated persistent mitral and tricuspid insufficiency. However, improved volume was noted in the left atrium and left ventricle as well as contractility noted post therapy. There was no pericardial or pleural effusion was noted. Slight left atrial dilation was present. Periodic arrhythmia was noted on this exam.

CANINE CARDIAC PARAMETERS	MR VMAX (m/s)	TR VMAX (m/s)	LA/AO (Boon method)	LA/AO (Heart Base; Swe)	FS (%)	EF (%)	EPSS (cm)
NORMAL PARAMETER	4.5-5.5	<2.7	1.3	<1.6	28-40	40-100	<0.6
PATIENT	5.72	2.13	1.3	1.9	64	93	0.1
CANINE CARDIAC PARAMETERS	HR (BPM)	AV VMAX (m/s)	PV MAX (m/s)	BODY WEIGHT (kg)	LA (2D short axis Base view) (cm)	LVIDd (Avg; 2D and m-mode short axis) (cm)	LVIDs (Avg; 2D and m-mode short axis) (cm)
NORMAL PARAMETER	50-100	0.7-1.7	0.7-1.6				
PATIENT				10.8 kg	3.4	3.07	

**ULTRASONOGRAPHIC FINDINGS**

Stabilized advanced B2 valvular disease.

**INTERPRETATION OF THE FINDINGS & FURTHER RECOMMENDATIONS**

I recommend to continue the current protocol as long as the patient is stable without coughing and basal respiratory rate is < 20/minute. A recheck echocardiogram is recommended in 3 months. The patient has responded well to therapy. Recheck is recommended earlier if clinical signs reinitiate.



**PATIENT**

Shake N Bake Manor

**SPECIES**

Canine

**BREED**

Boston Terrier

**SEX**

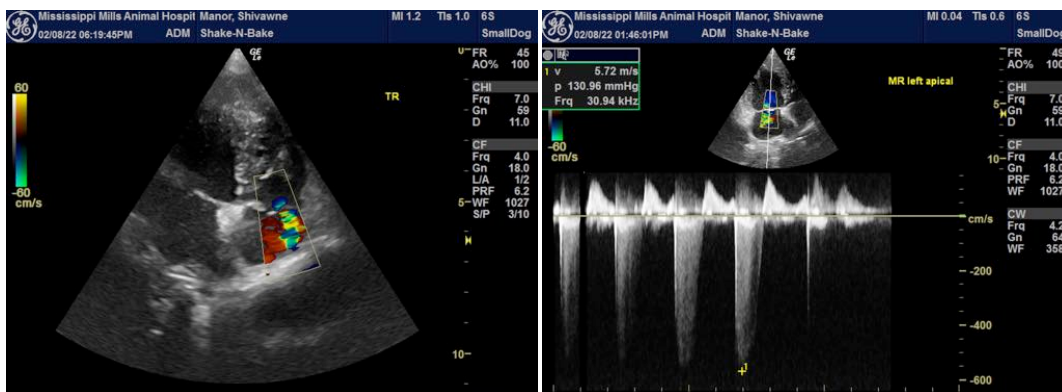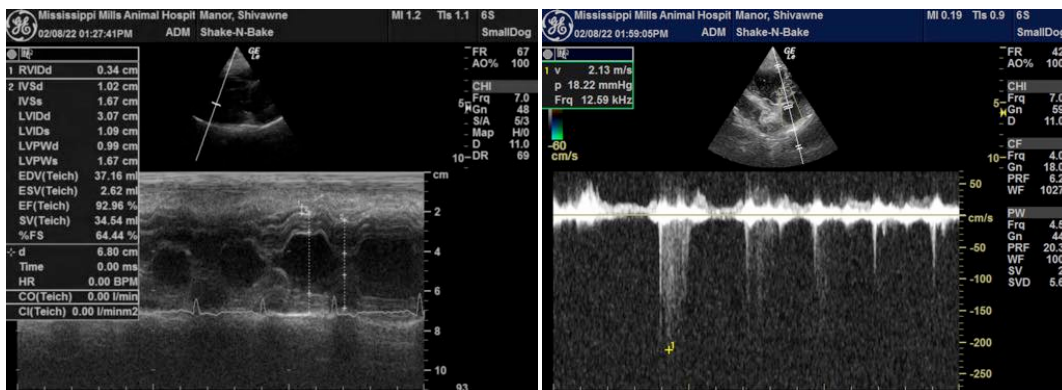
Neutered male

**AGE**

11 years

**WEIGHT**

10.8 kg



**INTERPRETED BY**

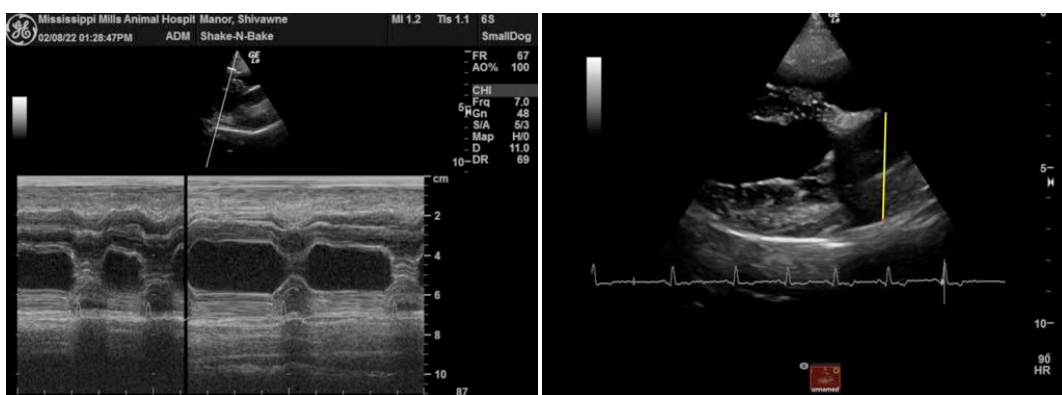
Eric Lindquist, DMV  
DABVP, Cert. IVUSS

**IMAGING PERFORMED BY**

Mark van Campen

**HOSPITAL NAME**

Mississippi AH



**REFERRING VET**

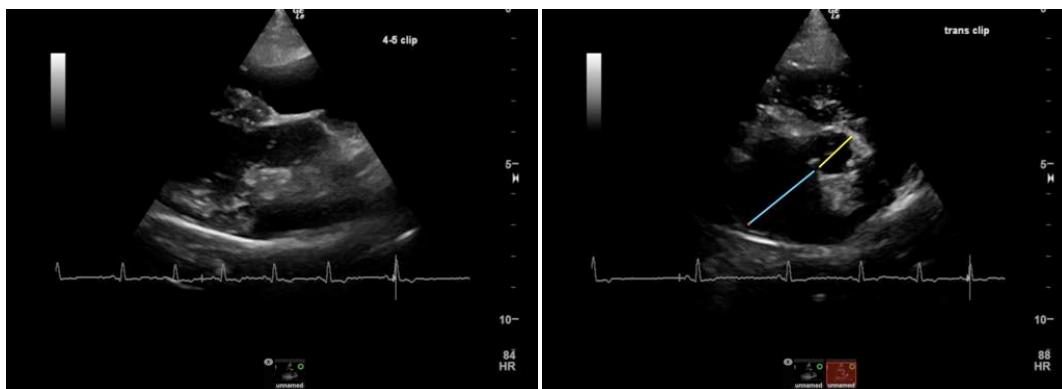
Dr. vanCampen

**INVOICE**

95923

**DATE**

2/8/22





**PATIENT**

Shake N Bake Manor

**SPECIES**

Canine

**BREED**

Boston Terrier

**SEX**

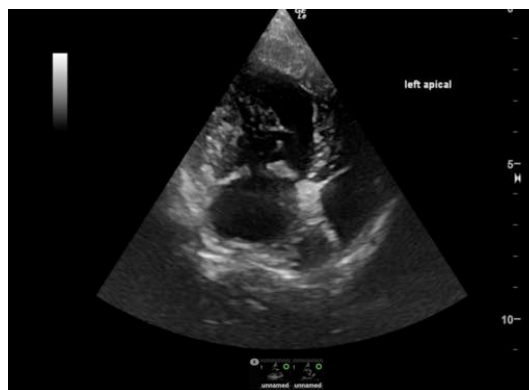Neutered male

**AGE**

11 years

**WEIGHT**

10.8 kg



The information and recommendations provided are based on the images presented by the referring veterinarian/sonographer. No evaluation can be communicated regarding pathology that was not visible in the image/video clips provided.

Thank you for this referral. If the clinical or image interpretation does not parallel your findings or if I can be of any further assistance please contact me.

**Eric Lindquist, DMV, DABVP, Cert. IVUSS, CEO of SonoPath.com**  
info@SonoPath.com

**INTERPRETED BY**

Eric Lindquist, DMV  
DABVP, Cert. IVUSS

**IMAGING PERFORMED BY**

Mark van Campen

**HOSPITAL NAME**

Mississippi AH

**REFERRING VET**

Dr. vanCampen

**INVOICE**

95923

**DATE**

2/8/22