



**PATIENT**

Sebastian Sheets

**PRESENTING CLINICAL SIGNS**

PU/PD, getting up in the middle of the night. LDDT in July consistent with Cushing's. No current meds.

**SPECIES**

Canine

**ULTRASONOGRAPHIC EXAMINATION OF THE ABDOMEN**

**Urinary System**

The **urinary bladder**, trigone, and pelvic urethra presented normal thicknesses and normal tone. The ureters were not visible which is normal. No uroliths or sediment were visualized and anechoic urine was present. No evidence of inflammatory or neoplastic changes was noted. Ureteral papillae were normal.

**BREED**

Yorkshire Terrier

**SEX**

Neutered male

The **kidneys** revealed normal size and structure, corticomedullary definition and ratio for this age. The cortices presented largely uniform texture with normal echogenic relationship to liver and spleen. Medullary structure differed distinctly from the cortex and no evidence of pelvic dilation was present. The capsules were acceptably uniform without significant irregularities. The left kidney measured 3.71 cm. The right kidney measured 3.6 cm.

**AGE**

6 years

**Adrenal Glands**

**WEIGHT**

11.9 lbs

Both **adrenal glands** were visualized and recognized as having normal shape, size, position and echogenicity for this breed. The phrenic vasculature, glandular echogenicity and detail were unremarkable. Capsule, cortex, and medullary definition were normal for this age patient. The right adrenal gland measured 1.3 x 0.65 cm at the cranial pole and 0.45 cm at the caudal pole. The left adrenal gland measured 1.82 x 0.5 cm at the cranial pole and 0.59 cm at the caudal pole.

**INTERPRETED BY**

Eric Lindquist, DMV  
DABVP, Cert. IVUSS

**Spleen**

The **spleen** presented a smooth homogeneous parenchyma hyperechoic to liver and renal cortical parenchyma. The capsule was smooth without noticeable expansion or deviation from within the spleen or adjacent pathology. The splenic vasculature demonstrated normal volume without signs of congestion or thrombosis. No sonographic evidence of acute or chronic inflammatory, neoplastic, or infarctual changes was noted.

**IMAGING PERFORMED BY**

Shari Reffi, CVT

**HOSPITAL NAME**

Millburn

**Liver**

**REFERRING VET**

Dr. Turowsky

Exam of the cranial abdomen demonstrated excessive **liver** size and swollen contour. Mild, coarse architecture was noted with increased portal markings and minor parenchymal remodeling is suggestive of an inflammatory component. Minor excessive GB debris was noted with the presence gall bladder dilation and precipitate without the overt formation of mucocele but this may be an issue in the future. This type of liver presentation typically is associated with slow and gradual SAP elevations with low-grade ALT rise. USG-FNA sampling is encouraged if more aggressive LE profiles are present such as ALT > 200 or rapid rise in SAP. These presentations are usually reactive hepatopathies owing to other disease processes either endocrine (Diabetes, Hypothyroidism, Cushing's disease), "antigen surveillance" from the gut/pancreas, or idiopathic breed predisposed progressions.

**INVOICE**

95906

**DATE**

2/8/22



**PATIENT**

**Gastrointestinal**

Sebastian Sheets

Examination of the **gastrointestinal tract** revealed a stomach and intestine free of stasis, of normal wall thickness, acceptable curvilinear mural detail, and peristaltic activity. Small and large intestine demonstrated normal luminal chyme and stool consistency respectively. No obstructive or overt infiltrative disease was noted. No associated abnormal lymphatic activity was noted.

**SPECIES**

Canine

**BREED**

Yorkshire Terrier

**Pancreas**

The base and limbs of the **pancreas** were observed to be largely isoechoic to surrounding omental fat. Pancreatic duct and capsular contour were acceptably normal and parenchyma respected normal curvilinear patterns. No overt evidence of active inflammatory or neoplastic disease was noted.

**SEX**

Neutered male

**ULTRASONOGRAPHIC FINDINGS**

Benign hepatopathy, structurally normal adrenal glands.

**AGE**

6 years

**INTERPRETATION OF THE FINDINGS & FURTHER RECOMMENDATIONS**

**WEIGHT**

There was no evidence of significant disease.

11.9 lbs

**INTERPRETED BY**

Eric Lindquist, DMV  
DABVP, Cert. IVUSS

**IMAGING PERFORMED BY**

Shari Reffi, CVT

**HOSPITAL NAME**

Millburn

**REFERRING VET**

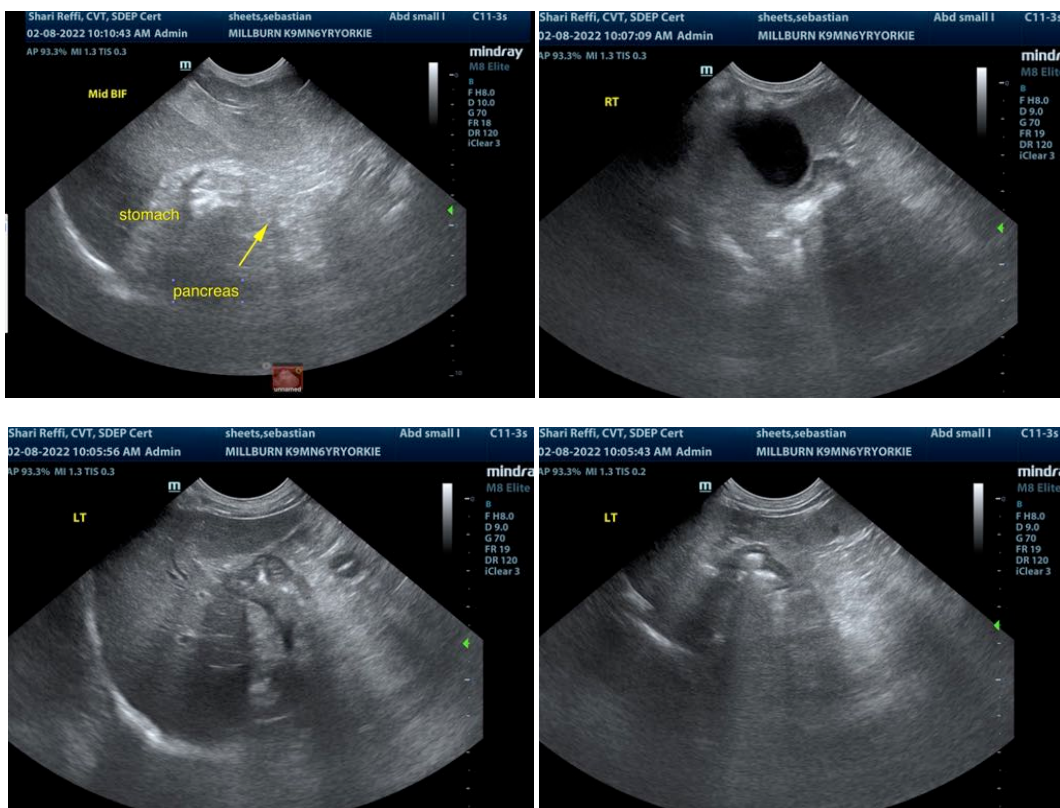
Dr. Turowsky

**INVOICE**

95906

**DATE**

2/8/22





**PATIENT**

Sebastian Sheets

**SPECIES**

Canine

**BREED**

Yorkshire Terrier

**SEX**

Neutered male

**AGE**

6 years

**WEIGHT**

11.9 lbs

**INTERPRETED BY**

Eric Lindquist, DMV  
DABVP, Cert. IVUSS

**IMAGING PERFORMED BY**

Shari Reffi, CVT

**HOSPITAL NAME**

Millburn

**REFERRING VET**

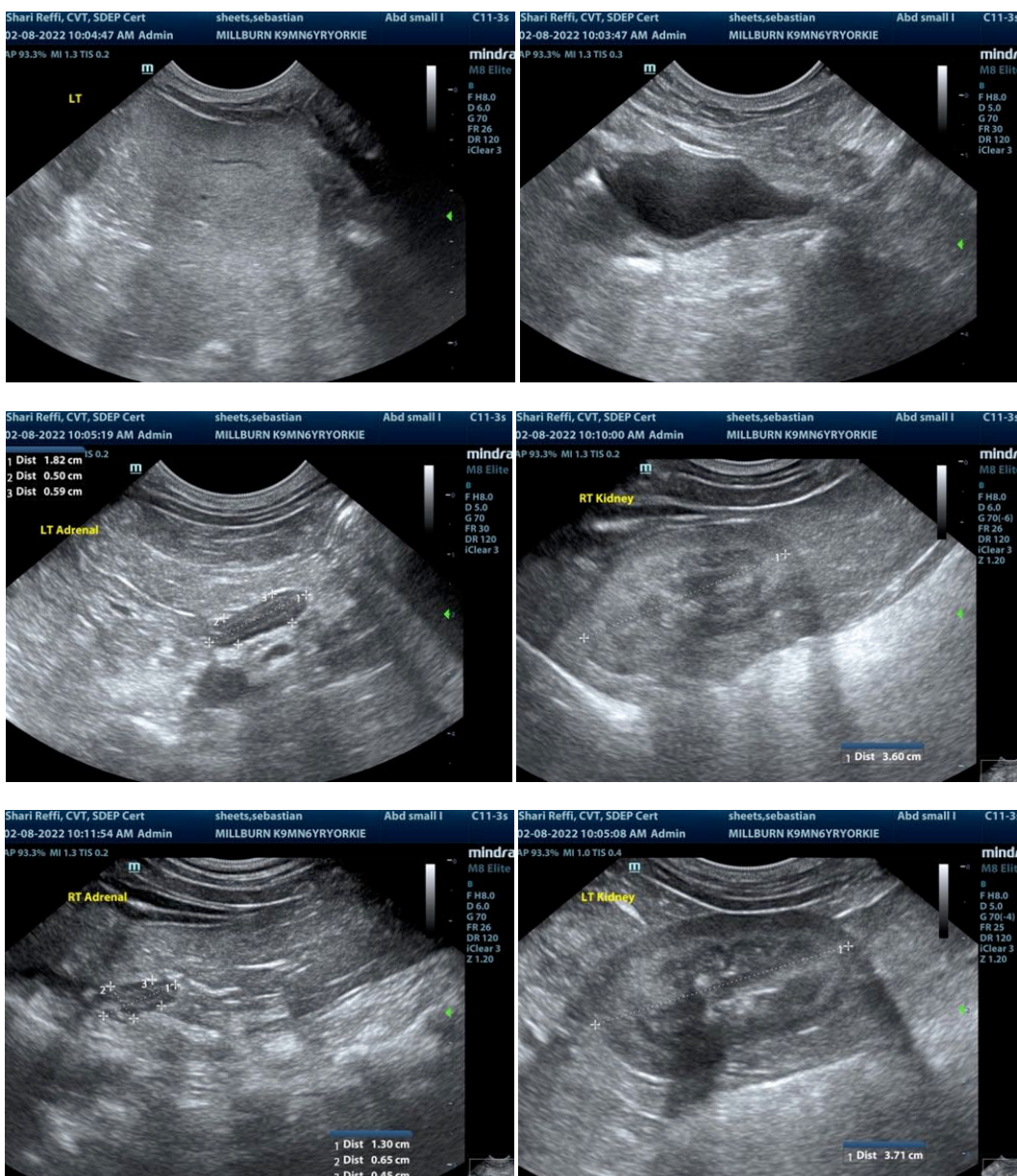
Dr. Turowsky

**INVOICE**

95906

**DATE**

2/8/22



The information and recommendations provided are based on the images presented by the referring veterinarian/sonographer. No evaluation can be communicated regarding pathology that was not visible in the image/video clips provided.

Thank you for this referral. If the clinical or image interpretation does not parallel your findings or if I can be of any further assistance please contact me.

Eric Lindquist, DMV, DABVP, Cert. IVUSS, CEO of SonoPath.com  
Info@SonoPath.com