



PATIENT

Rocky Kruzell

SPECIES

Canine

BREED

Boxer Mix

SEX

Neutered male

AGE

8 years

WEIGHT

47 lbs

INTERPRETED BY

Eric Lindquist, DMV
DABVP, Cert. IVUSS

IMAGING PERFORMED BY

Sammy Burmeister

HOSPITAL NAME

Faith AC

REFERRING VET

Dr. Faith

INVOICE

95923

DATE

2/8/22

PRESENTING CLINICAL SIGNS

History of a palpable prostate that has increased and decreased in size. He is a rescue but we are unsure of where he was neutered so we ran a testosterone panel, due to owner describing intact male behaviors, which came back normal. Radiographs showed a possible narrowing of the colon and patient is experiencing difficulty when it comes to passing stool. He has also begun to show signs of a painful back end and abdomen.

ULTRASONOGRAPHIC EXAMINATION OF THE ABDOMEN

Urinary System

The **urinary bladder**, trigone, and pelvic urethra presented normal thicknesses and normal tone. The ureters were not visible which is normal. No uroliths or sediment were visualized and anechoic urine was present. No evidence of inflammatory or neoplastic changes was noted. Ureteral papillae were normal.

The prostate was enlarged, irregular, nodular and mineralized with enhanced surrounding mesentery. The prostate measured approximately 3.0 cm. Parenchymal cysts were also noted with echogenic debris. The iliac lymph nodes were enlarged, nodular and cystic measuring up to 2.0 x 1.5 cm.

The **kidneys** revealed normal size and structure, corticomedullary definition and ratio for this age. The cortices presented largely uniform texture with normal echogenic relationship to liver and spleen. Medullary structure differed distinctly from the cortex and no evidence of pelvic dilation was present. The capsules were acceptably uniform without significant irregularities. The left kidney measured 5.0 cm.

Adrenal Glands

Both **adrenal glands** were visualized and recognized as having normal shape, size, position and echogenicity for this breed. The phrenic vasculature, glandular echogenicity and detail were unremarkable. Capsule, cortex, and medullary definition were normal for this age patient.

Spleen

The **spleen** presented a smooth homogeneous parenchyma hyperechoic to liver and renal cortical parenchyma. The capsule was smooth without noticeable expansion or deviation from within the spleen or adjacent pathology. The splenic vasculature demonstrated normal volume without signs of congestion or thrombosis. No sonographic evidence of acute or chronic inflammatory, neoplastic, or infarctual changes was noted.

Liver

The **liver** images from right and left intercostal as well as subcostal views revealed subjectively normal liver size, contour, and structure. Some age-related parenchymal remodeling was noted but likely not clinically significant at this time. Vascular and biliary tracts were of normal volume and no evidence of congestion was noted. The gallbladder presented some dependent debris with essentially normal contour. The cystic and common bile ducts were normal. No overt evidence of active inflammatory,



PATIENT

Rocky Kruzel

infiltrative or regenerative pathology was noted but should be paired with current or past LE elevations regarding any clinical significance to this presentation. The hepatic lymph nodes were unremarkable.

SPECIES

Canine

Gastrointestinal

Examination of the **gastrointestinal tract** revealed a stomach and intestine free of stasis, of normal wall thickness, acceptable curvilinear mural detail, and peristaltic activity. Small and large intestine demonstrated normal luminal chyme and stool consistency respectively. No obstructive or overt infiltrative disease was noted. No associated abnormal lymphatic activity was noted.

BREED

Boxer Mix

Pancreas

SEX

Neutered male

The base and limbs of the **pancreas** were observed to be largely isoechoic to surrounding omental fat. Pancreatic duct and capsular contour were acceptably normal and parenchyma respected normal curvilinear patterns. No overt evidence of active inflammatory or neoplastic disease was noted.

AGE

8 years

ULTRASONOGRAPHIC FINDINGS

WEIGHT

47 lbs

Mineralized irregular and cystic prostate. Strongly consistent with prostatic carcinoma with iliac lymphadenopathy.

INTERPRETATION OF THE FINDINGS & FURTHER RECOMMENDATIONS

INTERPRETED BY

Eric Lindquist, DMV
DABVP, Cert. IVUSS

There is a minor potential for trailing. Ultrasound-guided drainage of the cystic portions and FNA of the parenchyma is warranted to palliatively treat and definitively diagnose the suspected prostatic carcinoma. Otherwise, ultrasound-guided traumatic catheterization could be considered.

IMAGING PERFORMED BY

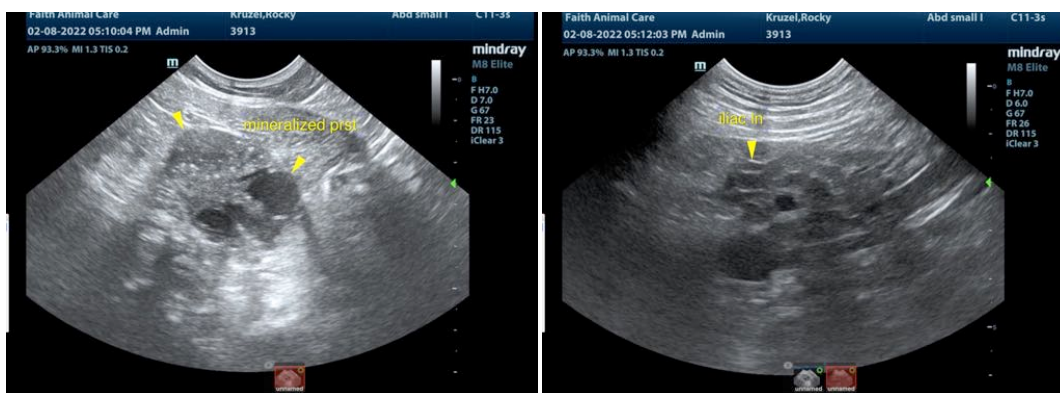
Sammy Burmeister

HOSPITAL NAME

Faith AC

REFERRING VET

Dr. Faith



INVOICE

95923

DATE

2/8/22



PATIENT

Rocky Kruzel

SPECIES

Canine

BREED

Boxer Mix

SEX

Neutered male

AGE

8 years

WEIGHT

47 lbs

INTERPRETED BY

Eric Lindquist, DMV
DABVP, Cert. IVUSS

IMAGING PERFORMED BY

Sammy Burmeister

HOSPITAL NAME

Faith AC

REFERRING VET

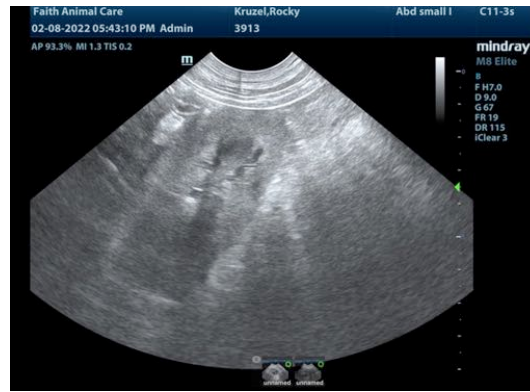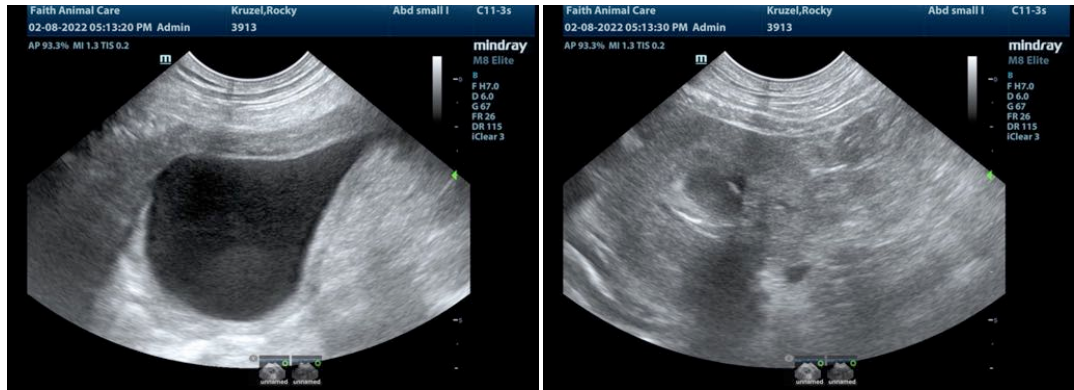
Dr. Faith

INVOICE

95923

DATE

2/8/22



The information and recommendations provided are based on the images presented by the referring veterinarian/sonographer. No evaluation can be communicated regarding pathology that was not visible in the image/video clips provided.

Thank you for this referral. If the clinical or image interpretation does not parallel your findings or if I can be of any further assistance please contact me.

Eric Lindquist, DMV, DABVP, Cert. IVUSS, CEO of SonoPath.com
info@SonoPath.com