

## PATIENT

Trixie Rider

## PRESENTING CLINICAL SIGNS

History: Grade 4/5 murmur. Echo prior to Dental  
 Abnormal PE/Chem/CBC/UA Results: BP 147/88(122), 151/105(129), 157/101(122)

## SPECIES

Canine

## ULTRASONOGRAPHIC EXAMINATION OF THE HEART

## BREED

Chihuahua

## SEX

Spayed female

## AGE

9 years

## WEIGHT

5 lbs

The echocardiogram in this patient demonstrated normal **left atrial** size based on 3 different LA measurement methods. Chamber volumes and echogenicity were normal. The cranial and caudal **mitral** valve leaflets presented vegetative thickening consistent with endocardiosis. Doppler indicated measurable insufficiency. The **left ventricle** presented thicknesses with linear contour and was not dilated nor restricted. The **myocardium** presented normal echogenicity without subjective evidence of significant fibrotic or ischemic disease. **Contractility** of the ventricular walls was adequate and in normal range for this patient evidenced by the fractional shortening measurement and subjective evaluation of the different regions of the myocardium. The **left ventricular outflow** tract demonstrated normal laminar flow and subjective structural integrity. The **right atrium** and auricle revealed normal size, structure and content. No evidence of masses was noted or chamber overload. **Tricuspid** valvular assessment demonstrated adequate linear morphology. The **right ventricle** was of normal size (1/3 diameter of LV), chordae structure, myocardial echogenicity and thickness. **Pulmonic** tract assessment revealed normal valve structure, laminar flow, and diameter (approx.1:1 pa/ao ratio). No visible **pericardial** or free pleura fluid was noted. No echographically detectable evidence of infiltrative disease was visible. The cranial **mediastinum and pericardial regions** were free of masses in the visible window.

## INTERPRETED BY

Eric Lindquist, DMV  
 DABVP, Cert. IVUSS

## IMAGING PERFORMED BY

JK

## HOSPITAL NAME

Hamburg VC

## REFERRING VET

Dr. Martens

CANINE CARDIAC PARAMETERS	MR VMAX (m/s)	TR VMAX (m/s)	LA/AO (Boon method)	LA/AO (Heart Base;)	FS (%)	EF (%)	EPSS (cm)
NORMAL PARAMETER	4.5-5.5	<2.7	1.3	<1.6	28-40	40-100	<0.6
PATIENT			1.2	1.3	50	90	0.1
CANINE CARDIAC PARAMETERS	HR (BPM)	AV VMAX (m/s)	PV MAX (m/s)	BODY WEIGHT	LA (2D short axis Base view) (cm)	LVIDd (Avg; 2D and m-mode short axis) (cm)	LVIDs (Avg; 2D and m-mode short axis) (cm)
NORMAL PARAMETER	50-100	0.7-1.7	0.7-1.6	BELOW	BELOW	BELOW	BELOW
PATIENT	110	1.5	0.6	5 lbs	2.2	1.6	

## INVOICE

42625

## DATE

2/7/23



**PATIENT**

Trixie Rider

**ULTRASONOGRAPHIC FINDINGS**

Stage B1 valvular disease, compensated.

**SPECIES**

Canine

**INTERPRETATION OF THE FINDINGS & FURTHER RECOMMENDATIONS**

The heart is stable without clinical disease. No overt contraindication for anesthesia of brief to moderate duration. I suggest Torbutrol premed, Propofol induction, Isoflor maintenance or similar protocol if anesthesia is desired. Blood pressure recommended if not already performed and target white coat negative systolic pressure of < 160 mmHg. If higher than this ACE-inhibitor is suggested to reach this level. Recheck echocardiogram is recommended in 6 months, earlier if murmur grade increases or clinical signs initiate.

**BREED**

Chihuahua

**SEX**

Spayed female

**AGE**

9 years

**WEIGHT**

5 lbs

**INTERPRETED BY**

Eric Lindquist, DMV  
DABVP, Cert. IVUSS

**IMAGING PERFORMED BY**

JK

**HOSPITAL NAME**

Hamburg VC

**REFERRING VET**

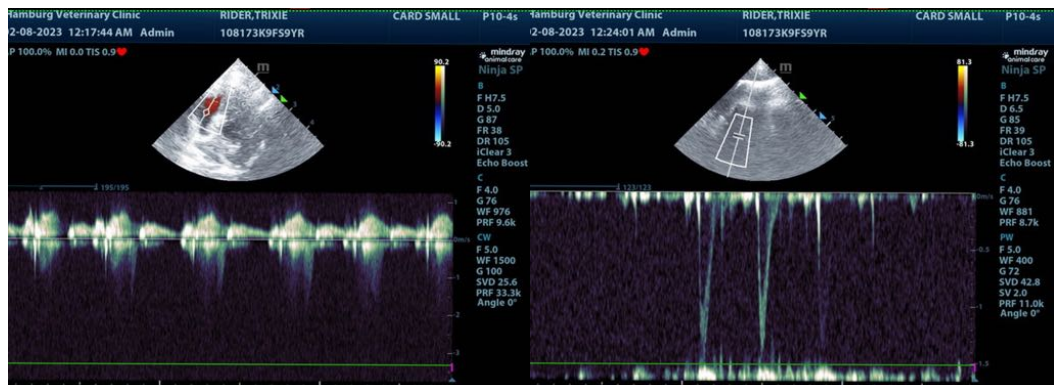
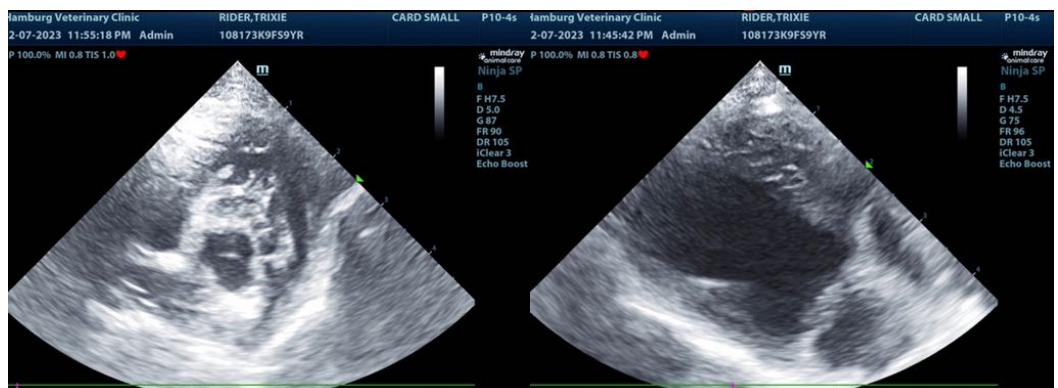
Dr. Martens

**INVOICE**

42625

**DATE**

2/7/23





**PATIENT**

Trixie Rider

**SPECIES**

Canine

**BREED**

Chihuahua

**SEX**

Spayed female

**AGE**

9 years

**WEIGHT**

5 lbs

**INTERPRETED BY**

Eric Lindquist, DMV  
DABVP, Cert. IVUSS

**IMAGING PERFORMED BY**

JK

**HOSPITAL NAME**

Hamburg VC

**REFERRING VET**

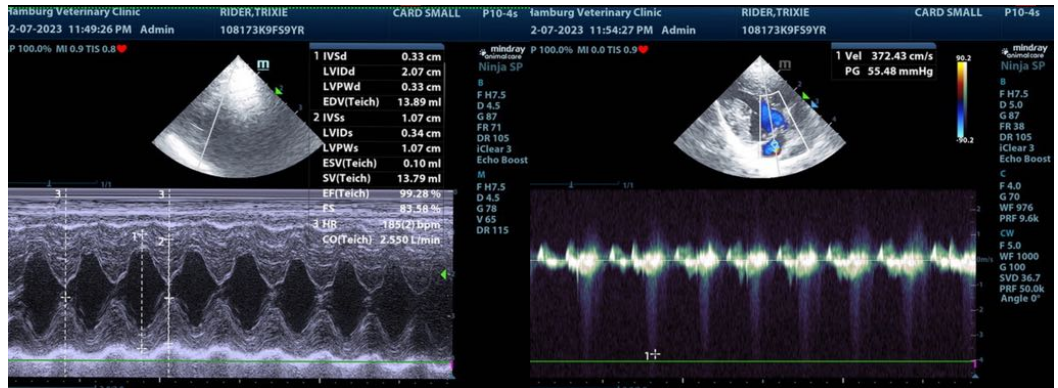
Dr. Martens

**INVOICE**

42625

**DATE**

2/7/23



The information and recommendations provided are based on the images presented by the referring veterinarian/sonographer. No evaluation can be communicated regarding pathology that was not visible in the image/video clips provided.

Thank you for this referral. If the clinical or image interpretation does not parallel your findings or if I can be of any further assistance please contact me.

**Eric Lindquist, DMV, DABVP, Cert. IVUSS, CEO of SonoPath.com**  
info@SonoPath.com