SonoPath

Clinical Sonography & Telecytology

EDUCATIONAL TELECONSULTATION SERVICES™

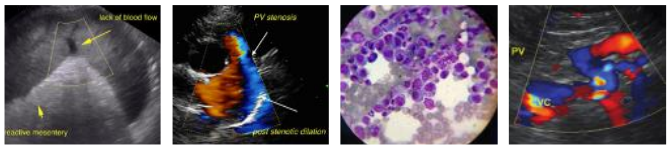

SonoPath.com™
1-800-838-4268 info@sonopath.com

PATIENT

Emily Netboy

SPECIES

Canine

BREED

Mini Schnauzer

SEX

Spayed Female

AGE

7 Years

WEIGHT

9 kg

INTERPRETED BY

Eric Lindquist, DMV DABVP, Cert. IVUSS

IMAGING PERFORMED BY

Dr. Callihan

HOSPITAL NAME

Animal Emergency Care

REFERRING VET

Dr. Licciardi

INVOICE

13804

DATE

2/7/22

PRESENTING CLINICAL SIGNS

History: S: Patient presents for: CRF since 4/2020. Has been doing well on SQF q 3 days. 3 weeks ago, numbers started to increase again (Creatinine up from 2's to 5 with BUN of 70) but was doing well. Yesterday bloodwork -- Crea 6.4, BUN 84. Vomiting started yesterday. Per owner has had multiple urine cultures, all "pansensitive E.coli and Enterococcus- we do not have information on timing of most recent culture or when last round of antibiotics was completed. Current meds: IV Crystalloids, Amlodipine, Cerenia, Clavacillin

Abnormal PE/Chem/CBC/UA Results: -Most recent UA showed USG 1.016, no bacteria, quiet sediment but proteinuria 100mg/dL -she is hypertensive in hospital with systolic bp (Doppler) in 180-200 range - Reviewed prior bloodwork: 5/2021 BUN/Crea 42/2.3 11/2021 BUN/Crea 60/3.3 1/19/2022 BUN/Crea 70/5.1

ULTRASONOGRAPHIC EXAMINATION OF THE ABDOMEN

Urinary System

The **urinary bladder**, trigone, and pelvic urethra presented normal thicknesses and normal tone. The ureters were not visible which is normal. No uroliths or sediment were visualized and anechoic urine was present. No evidence of inflammatory or neoplastic changes were noted. Ureteral papillae were normal. The pelvic urethra was imaged 2.0 cm beyond the cystourethral junction.

The **right kidney** revealed loss of corticomedullary definition. Dorsal cortical infarct with active inflammation noted with active inflammation indicative of recent infarct. Other infarcts also noted at the caudal pole. Pyelectasia was noted in the right kidney with areas of pinpoint mineralization. This is likely subacute on chronic nephritis. Cortical cyst noted. The right kidney measured 4.0 cm.

The **left kidney** revealed normal size and structure, corticomedullary definition and ratio for this age. The cortices presented largely uniform texture with normal echogenic relationship to liver and spleen. Medullary structure differed distinctly from the cortex. The capsules were acceptably uniform without significant irregularities. Pyelectasia was noted in the left kidney. No evidence of active inflammation. The left kidney measured 4.23 cm.

Adrenal Glands

The **left adrenal gland** was visualized and recognized as having normal shape, size, position and echogenicity for this breed. The phrenic vasculature, glandular echogenicity and detail were unremarkable. Capsule, cortex, and medullary definition were normal for this age patient. The left adrenal gland measured 0.62 cm.

The region of the **right adrenal gland** was unremarkable.

Spleen

The **spleen** was enlarged and folded upon itself cranially. Minor heterogeneous changes noted, likely reactive state.

Liver

The **liver** itself was unremarkable. The **gallbladder** was mildly over distended with mild suspended and dependent debris, yet not to the level of emerging mucocele, yet sludge appears to be mildly excessive. No adjunctive inflammation was noted.

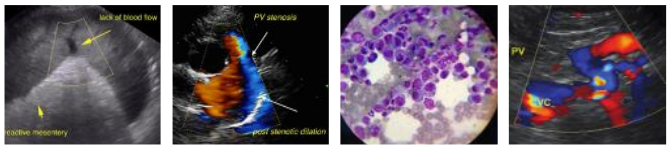

SonoPath.com
1-800-838-4268 info@sonopath.com

PATIENT

Emily Netboy

SPECIES

Canine

BREED

Mini Schnauzer

SEX

Spayed Female

AGE

7 Years

WEIGHT

9 kg

INTERPRETED BY

Eric Lindquist, DMV DABVP, Cert. IVUSS

IMAGING PERFORMED BY

Dr. Callihan

HOSPITAL NAME

Animal Emergency Care

REFERRING VET

Dr. Licciardi

INVOICE

13804

DATE

2/7/22

Gastrointestinal

Examination of the **gastrointestinal tract** revealed a stomach and intestine free of stasis, of normal wall thickness, acceptable curvilinear mural detail, and peristaltic activity. Small and large intestine demonstrated normal luminal chyme and stool consistency respectively. No obstructive or overt infiltrative disease was noted. No associated abnormal lymphatic activity was noted.

Pancreas

The base and limbs of the **pancreas** were observed to be largely isoechoic to surrounding omental fat. Pancreatic duct and capsular contour were acceptably normal and parenchyma respected normal curvilinear patterns. No overt evidence of active inflammatory or neoplastic disease was noted.

ULTRASONOGRAPHIC FINDINGS

- Chronic degenerative renal disease, interstitial nephrosis pattern with active inflammatory events on the right kidney owing to pyelonephritis or calculus passage
- Mild gallbladder debris
- Reactive spleen with minor heterogeneous changes
- Geriatric abdomen otherwise

INTERPRETATION OF THE FINDINGS & FURTHER RECOMMENDATIONS

No obstructive disease noted at this time. I recommend urine culture and sensitivity, blood pressure measurements and 72-hour IV fluid protocol. Right renal palpation recommended to assess for any pain. Prognosis is guarded. Subjectively, the kidneys appear near end stage. However, the active inflammatory process, primarily in the right kidney, is likely pushing the patient further into renal failure.

For an additional charge, internal medicine consult can be utilized through Sonopath.com. You can select the internal medicine drop down at http://spa.sonopath.com/.

One of the world's top internists & SonoPath associate Dr. Remo Lobetti BVSc, MMedVet, PhD, DECVIM can evaluate your case through SonoPath. https://sonopath.com/resources/sonopath-services/internal-medicine-teleconsultation-services

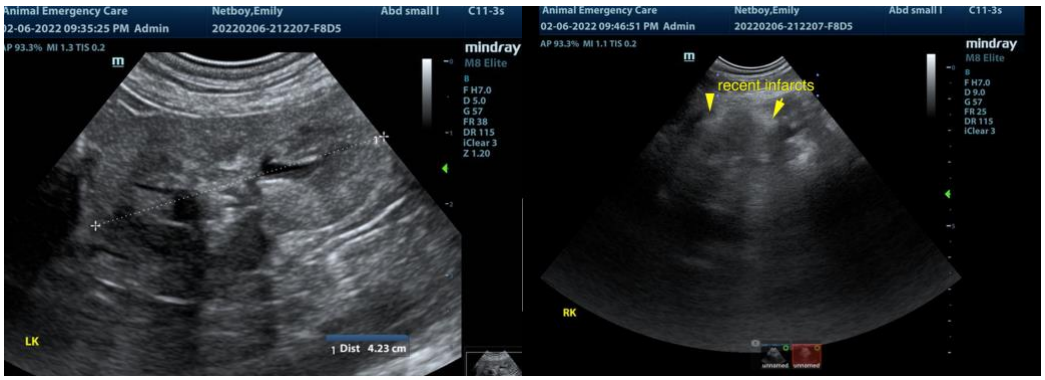

SonoPath

Clinical Sonography & Telecytology

EDUCATIONAL TELECONSULTATION SERVICES™

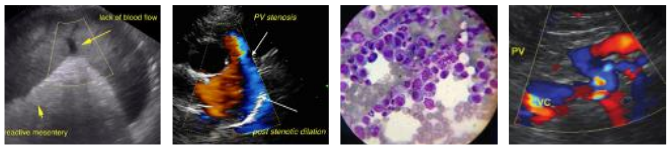

SonoPath.com™
1-800-838-4268 info@sonopath.com

PATIENT

Emily Netboy

SPECIES

Canine

BREED

Mini Schnauzer

SEX

Spayed Female

AGE

7 Years

WEIGHT

9 kg

INTERPRETED BY

Eric Lindquist, DMV
DABVP, Cert. IVUSS

IMAGING PERFORMED BY

Dr. Callihan

HOSPITAL NAME

Animal Emergency Care

REFERRING VET

Dr. Licciardi

INVOICE

13804

DATE

2/7/22

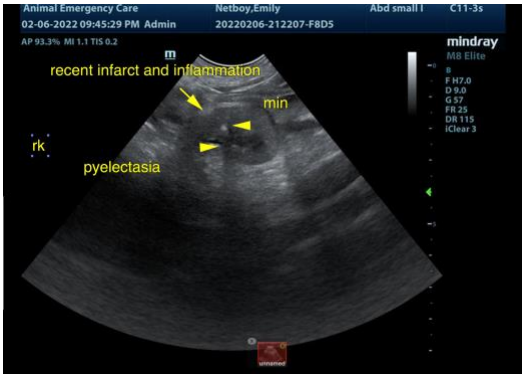

SonoPath

Clinical Sonography & Telecytology

EDUCATIONAL TELECONSULTATION SERVICES™

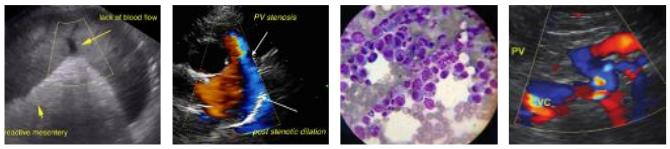

SonoPath.com™
1-800-838-4268 info@sonopath.com

PATIENT

Emily Netboy

SPECIES

Canine

BREED

Mini Schnauzer

SEX

Spayed Female

AGE

7 Years

WEIGHT

9 kg

INTERPRETED BY

Eric Lindquist, DMV
DABVP, Cert. IVUSS

IMAGING PERFORMED BY

Dr. Callihan

HOSPITAL NAME

Animal Emergency Care

REFERRING VET

Dr. Licciardi

INVOICE

13804

DATE

2/7/22

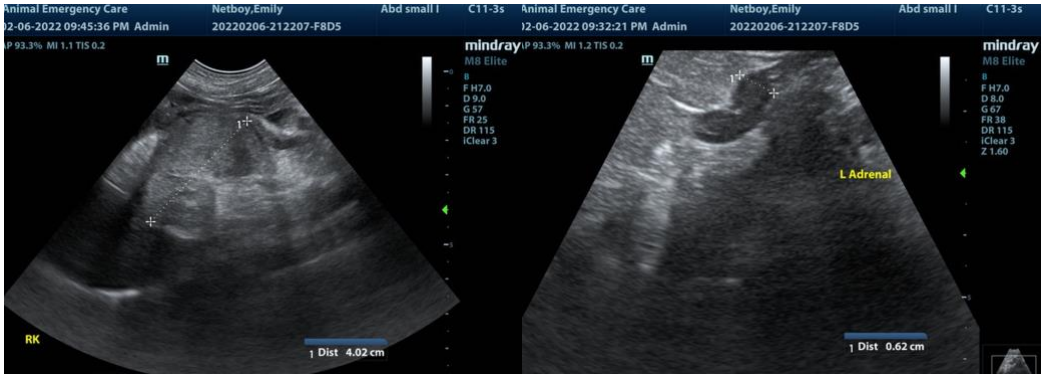

The information and recommendations provided are based on the images presented by the referring veterinarian. No evaluation can be communicated regarding pathology that was not visible in the image/video clips provided.

Thank you for this referral. If the clinical or image interpretation does not parallel your findings or if I can be of any further assistance please contact me.

Eric Lindquist, DMV, DABVP, Cert. IVUSS, CEO of SonoPath.com
info@SonoPath.com