



PATIENT

Violet Hiller

SPECIES

Canine

BREED

Mixed

SEX

Spayed Female

AGE

13 Years

WEIGHT

5.2 kg

INTERPRETED BY

Eric Lindquist, DMV,
DABVP (Canine &
Feline), Cert. IVUSS

IMAGING PERFORMED BY

Vincent Ravancho, CVT

HOSPITAL NAME

Bond Vet Montclair

REFERRING VET

Dr. Bedoya

INVOICE

35736

DATE

2/6/26

PRESENTING CLINICAL SIGNS

- Pre-op Echocardiogram
- Marked dental dz
- Grade IV/VI HM
- Current Medications: Clindamycin
- Abnormal PE/Chem/CBC/UA Results: Anemia, Leukocytosis, Hypoglycemia, increased TP, Low albumin, low Globulin, Increased ALP, Normal proBNP

ULTRASONOGRAPHIC EXAMINATION OF THE HEART

CANINE CARDIAC PARAMETERS	MR VMAX (m/s)	TR VMAX (m/s)	LA/AO (M-Mode)	LA/AO (Heart Base; Swe)	FS (%)	EF (%)	EPSS (cm)
NORMAL PARAMETER	4.5-5.5	<2.7	1.3	Up to 1.6	28-40	40-100	<0.6
PATIENT	5.70	--	1.3	1.2	50	90	0.1
CANINE CARDIAC PARAMETERS	HR (BPM)	AV VMAX (m/s)	PV MAX (m/s)	BODY WEIGHT (kg)	LAD LA MAX 4 Chamber	LVIDd Avg; 2D and m-mode short axis (cm)	LVIDs Avg; 2D and m-mode short axis (cm)
NORMAL PARAMETER	50-100	0.7-1.7	0.7-1.6				
PATIENT	110	1.20	1.20	5.2	2.4	2.5	--

Cardiac Presentation

The echocardiogram in this patient demonstrated normal **left atrial** size based on 3 different LA measurement methods. Chamber volumes and echogenicity were normal. The cranial and caudal **mitral** valve leaflets presented vegetative thickening consistent with endocardiosis. Doppler indicated measurable insufficiency. The **left ventricle** presented thicknesses with linear contour and was not dilated nor restricted. The **myocardium** presented normal echogenicity without subjective evidence of significant fibrotic or ischemic disease. **Contractility** of the ventricular walls was adequate and in normal range for this patient evidenced by the fractional shortening measurement and subjective evaluation of the different regions of the myocardium. The **left ventricular outflow** tract demonstrated normal laminar flow and subjective structural integrity. The **right atrium** and auricle revealed normal size, structure and content. No evidence of masses was noted or chamber overload.



PATIENT

Violet Hiller

SPECIES

Canine

BREED

Mixed

SEX

Spayed Female

AGE

13 Years

WEIGHT

5.2 kg

INTERPRETED BY

Eric Lindquist, DMV,
DABVP (Canine &
Feline), Cert. IVUSS

IMAGING PERFORMED BY

Vincent Ravancho, CVT

HOSPITAL NAME

Bond Vet Montclair

REFERRING VET

Dr. Bedoya

INVOICE

35736

DATE

2/6/26

Trivial tricuspid insufficiency was noted. The **right ventricle** was of normal size (1/3 diameter of LV), chordae structure, myocardial echogenicity and thickness. **Pulmonic** tract assessment revealed normal valve structure, laminar flow, and diameter (approx.1:1 pa/ao ratio). No visible **pericardial** or free pleura fluid was noted. No echographically detectable evidence of infiltrative disease was visible. The cranial **mediastinum and pericardial regions** were free of masses in the visible window.

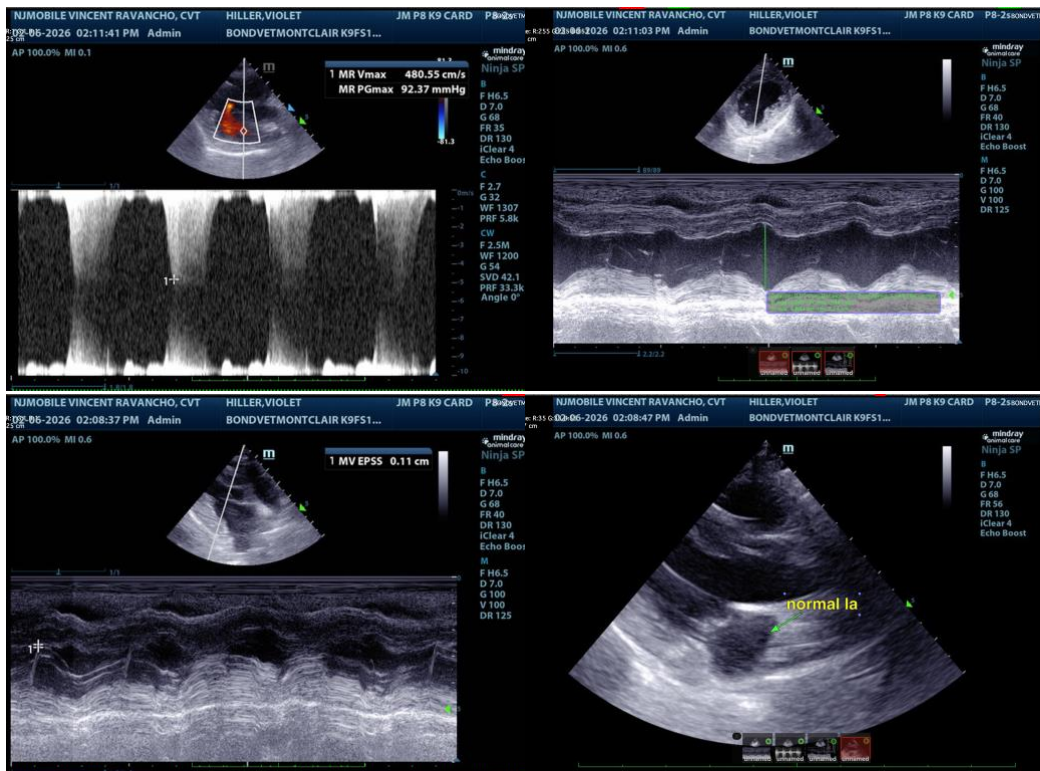
ULTRASONOGRAPHIC FINDINGS

- Stage B-1 valvular disease

INTERPRETATION OF THE FINDINGS & FURTHER RECOMMENDATIONS

Given the clinical history of anemia, hypoglycemia and low albumin, abdominal sonogram is recommended if not already performed. No contraindication to anesthetic procedure currently from a cardiac standpoint.

The heart is stable without clinical disease. No overt contraindication for anesthesia of brief to moderate duration. I suggest Torbutrol premed, Propofol induction, Isoflo maintenance or similar protocol if anesthesia is desired. Blood pressure recommended if not already performed and target white coat negative systolic pressure of < 160 mmHg. If higher than this ACE-inhibitor is suggested to reach this level. Recheck echocardiogram is recommended in 6 months, earlier if murmur grade increases or clinical signs initiate.





PATIENT

Violet Hiller

SPECIES

Canine

BREED

Mixed

SEX

Spayed Female

AGE

13 Years

WEIGHT

5.2 kg

INTERPRETED BY

Eric Lindquist, DMV,
 DABVP (Canine &
 Feline), Cert. IVUSS

IMAGING PERFORMED BY

Vincent Ravancho, CVT

HOSPITAL NAME

Bond Vet Montclair

REFERRING VET

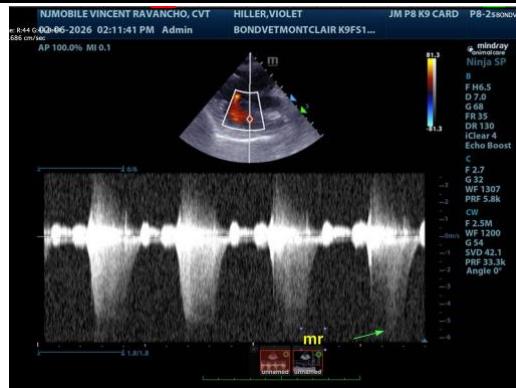
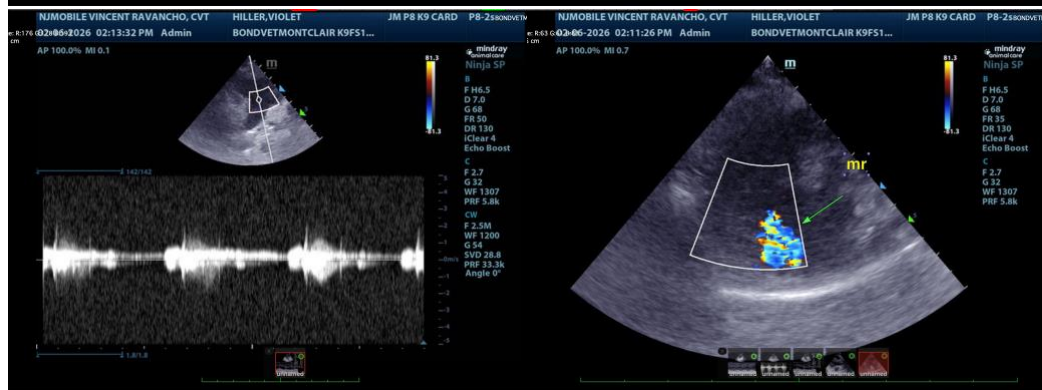
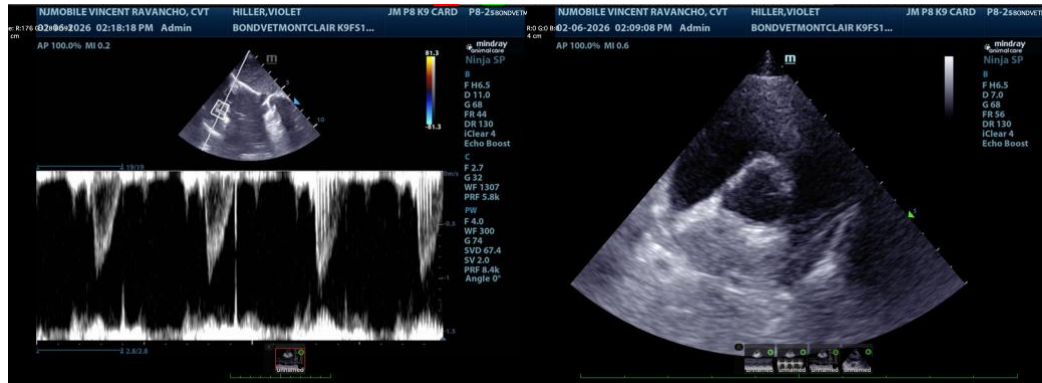Dr. Bedoya

INVOICE

35736

DATE

2/6/26



The information and recommendations provided are based on the images presented by the referring veterinarian/sonographer. No evaluation can be communicated regarding pathology that was not visible in the image/video clips provided.

Thank you for this referral. If the clinical or image interpretation does not parallel your findings or if I can be of any further assistance please contact me.

Eric Lindquist, DMV, DABVP(CFM), Cert. IVUSS,
 CEO, Owner, Founder -- SonoPath.com
info@SonoPath.com