



**PATIENT**

Stuart Simmonds

**SPECIES**

Feline

**BREED**

Ragdoll

**SEX**

Intact Male

**AGE**

9 Months

**WEIGHT**

8 Pounds

**INTERPRETED BY**

Eric Lindquist, DMV,  
DABVP(CFM), Cert.  
IVUSS

**IMAGING PERFORMED BY**

Rebecca Hamilton

**HOSPITAL NAME**

Wyckoff VH

**REFERRING VET**

Dr. Eisenberg

**INVOICE**

35732

**DATE**

2/6/26

**PRESENTING CLINICAL SIGNS**

Undescended testicle

**ULTRASONOGRAPHIC EXAMINATION OF THE ABDOMEN**

**Urinary System**

The **urinary bladder**, trigone, and pelvic urethra presented normal thicknesses and normal tone. The ureters were not visible which is normal. No uroliths or sediment were visualized and anechoic urine was present. No evidence of inflammatory or neoplastic changes were noted. Ureteral papillae were normal. The pelvic urethra was imaged 3.0 cm beyond the cystourethral junction.

A 1.5 cm retained **testicle** is present dorsal to the bladder trigone/cystourethral junction in the intrabdominal space.

The **kidneys** revealed normal size and structure, corticomedullary definition and ratio for this age. The cortices presented largely uniform texture with normal echogenic relationship to liver and spleen. Medullary structure differed distinctly from the cortex, and no evidence of pelvic dilation was present. The capsules were acceptably uniform without significant irregularities. The left kidney measured 4.3 cm. The right kidney measured 4.0 cm.

**Adrenal Glands**

The **left adrenal gland** was visualized and recognized as having normal shape, size, position and echogenicity for this breed. The phrenic vasculature, glandular echogenicity and detail were unremarkable. Capsule, cortex, and medullary definition were normal for this age patient. The left adrenal gland measured 0.29 cm.

The region of the **right adrenal gland** revealed no evident pathology.

**Spleen**

The **spleen** presented a smooth homogeneous parenchyma hyperechoic to liver and renal cortical parenchyma. The capsule was smooth without noticeable expansion or deviation from within the spleen or adjacent pathology. The splenic vasculature demonstrated normal volume without signs of congestion or thrombosis. No sonographic evidence of acute or chronic inflammatory, neoplastic, or infarctual changes were noted. The spleen was folded upon itself.

**Liver**

The **liver** images submitted revealed subjectively normal liver size, contour, and structure. Parenchymal echogenicity was naturally coarse and hypoechoic to the spleen. Vascular and biliary tracts were of normal volume with no evidence of congestion. The gallbladder presented acceptably thin walls with primarily anechoic content. The cystic and common bile ducts were normal. No pathological hepatic lymphadenopathy was evident. No overt structural evidence of inflammatory, infiltrative or regenerative pathology was evident. Portal vein to vena cava ratio was 1:1. No evidence of portosystemic shunting.

**Gastrointestinal**



**PATIENT**

Stuart Simmonds

**SPECIES**

Feline

**BREED**

Ragdoll

**SEX**

Intact Male

**AGE**

9 Months

**WEIGHT**

8 Pounds

**INTERPRETED BY**

Eric Lindquist, DMV,  
DABVP(CFM), Cert.  
IVUSS

**IMAGING PERFORMED BY**

Rebecca Hamilton

**HOSPITAL NAME**

Wyckoff VH

**REFERRING VET**

Dr. Eisenberg

**INVOICE**

35732

**DATE**

2/6/26

There was some residual chyme and gas noted in the **stomach**, yet not pathological. The luminal content within the stomach measured 2.0 cm, with acoustic shadowing. This may be consistent with hairball accumulation, foreign body, or residual ingesta, depending on patient's feeding history prior to the sonogram. Transit of chyme into the small intestine was normal. Curvilinear patterns were maintained throughout the GI tract. No evidence of pathology. Small and large intestine demonstrated normal luminal chyme and stool consistency respectively. No obstructive or overt infiltrative disease was noted. No associated abnormal lymphatic activity was noted.

**Pancreas**

The base and limbs of the **pancreas** were observed to be largely isoechoic to surrounding omental fat. Pancreatic duct and capsular contour were acceptably normal and parenchyma respected normal curvilinear patterns. No overt evidence of active inflammatory or neoplastic disease was noted.

**Free Abdomen**

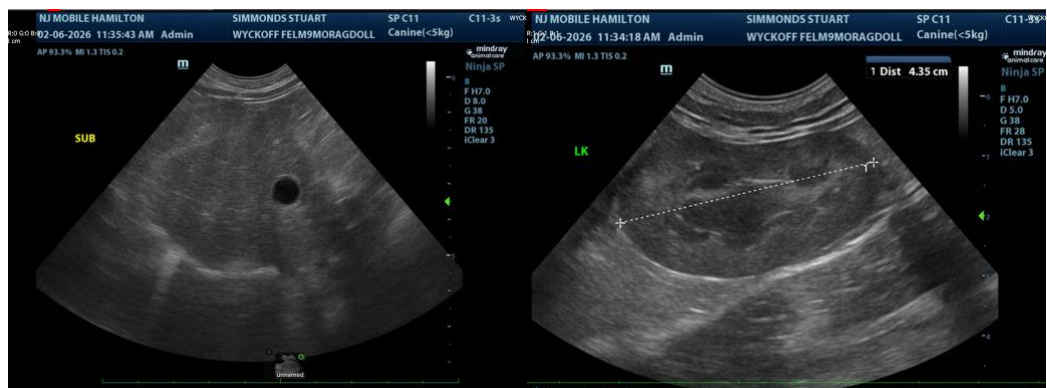
Mesenteric **lymph nodes** were present, measuring up to 8.0 mm.

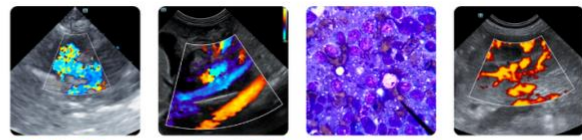
**ULTRASONOGRAPHIC FINDINGS**

- Full stomach with shadowing material- hairball accumulation, foreign matter, or retained ingesta are all possible.
- Retained testicle dorsal to the urinary bladder trigone/cystourethral junction in the intraabdominal space.
- Splenic folding

**INTERPRETATION OF THE FINDINGS & FURTHER RECOMMENDATIONS**

Surgical intervention is recommended with laparotomy focusing on the dorsal aspect of the caudal urinary bladder for retriever of the retained testicle.





**PATIENT**

Stuart Simmonds

**SPECIES**

Feline

**BREED**

Ragdoll

**SEX**

Intact Male

**AGE**

9 Months

**WEIGHT**

8 Pounds

**INTERPRETED BY**

Eric Lindquist, DMV,  
 DABVP(CFM), Cert.  
 IUUSS

**IMAGING PERFORMED BY**

Rebecca Hamilton

**HOSPITAL NAME**

Wyckoff VH

**REFERRING VET**

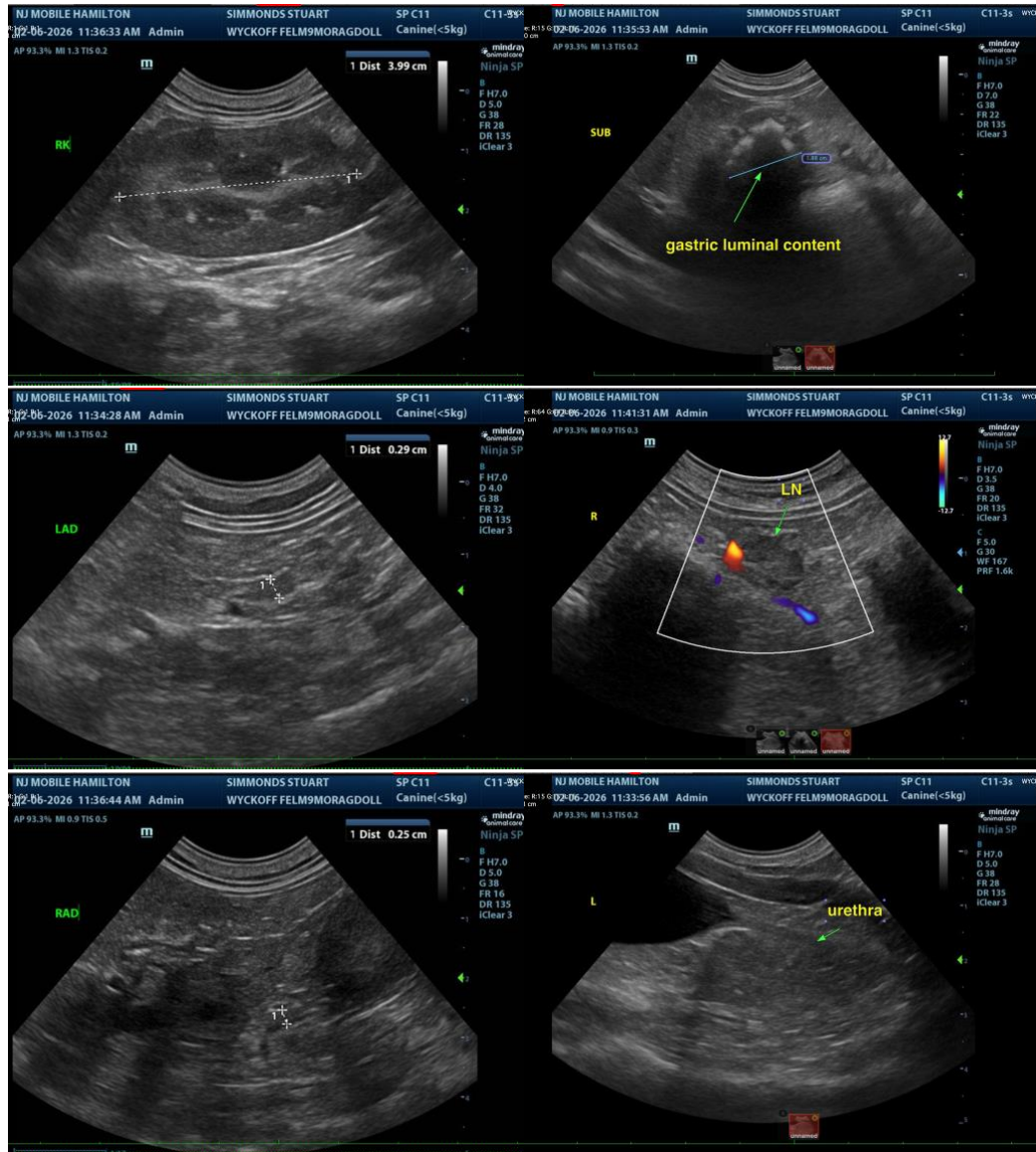
Dr. Eisenberg

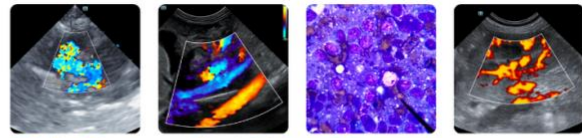
**INVOICE**

35732

**DATE**

2/6/26





**PATIENT**

Stuart Simmonds

**SPECIES**

Feline

**BREED**

Ragdoll

**SEX**

Intact Male

**AGE**

9 Months

**WEIGHT**

8 Pounds

**INTERPRETED BY**

Eric Lindquist, DMV,  
DABVP(CFM), Cert.  
IVUSS

**IMAGING  
PERFORMED BY**

Rebecca Hamilton

**HOSPITAL NAME**

Wyckoff VH

**REFERRING VET**

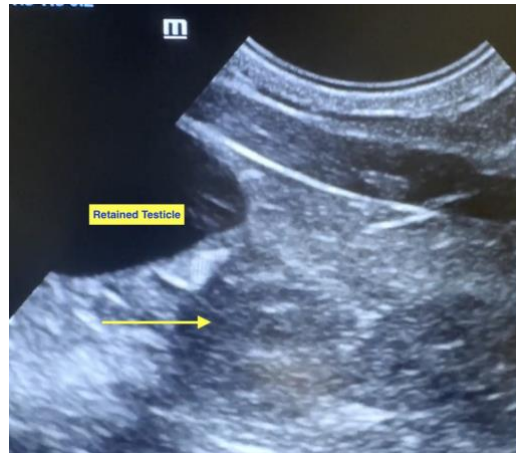
Dr. Eisenberg

**INVOICE**

35732

**DATE**

2/6/26



**The information and recommendations provided are based on the images presented by the referring veterinarian/sonographer. No evaluation can be communicated regarding pathology that was not visible in the image/video clips provided.**

Thank you for this referral. If the clinical or image interpretation does not parallel your findings or if I can be of any further assistance please contact me.

**Eric Lindquist**, DMV, DABVP(CFM), Cert. IVUSS,  
CEO, Owner, Founder -- SonoPath.com  
[info@SonoPath.com](mailto:info@SonoPath.com)