



PATIENT

Sammy Illescas

SPECIES

Canine

BREED

Miniature Schnauzer

SEX

Neutered male

AGE

11 years

WEIGHT

19.8 lbs

INTERPRETED BY

Eric Lindquist, DMV
DABVP, Cert. IVUSS

IMAGING PERFORMED BY

Heather

HOSPITAL NAME

Animal Care Center of
Flanders

REFERRING VET

Dr. Hallihan

INVOICE

71364

DATE

2/6/26

PRESENTING CLINICAL SIGNS

- Heart murmur Grade III/VI. Cough induced syncope episode noted on 2/2/26
- Medications: Midazolam 5mg/ml - Amin 0.2 ml IV for scan
- Radiographs attached. 2/6/26: BP = 160 systolic ECG evaluated 2 February 2026: a 6-lead ECG is submitted for review Findings • Average Heart Rate: 173 bpm • Rhythm: Sinus rhythm with widened QRS complexes suggestive of ventricular enlargement and mildly increased P wave amplitude suggestive of right atrial enlargement. • Other : No pathologic arrhythmias are noted.

ULTRASONOGRAPHIC EXAMINATION OF THE HEART

The echocardiogram in this patient demonstrated enlarged **left atrial** size based on 3 different LA measurement methods. Chamber volumes and echogenicity were normal. The cranial and caudal **mitral** valve leaflets presented vegetative thickening consistent with endocardiosis. Prolapse of the anterior mitral valve leaflet was noted. Doppler indicated measurable insufficiency. The **left ventricle** presented normal thicknesses with linear contour and was not dilated nor restricted. The **myocardium** presented normal echogenicity without subjective evidence of significant fibrotic or ischemic disease.

Contractility of the ventricular walls was adequate and in normal range for this patient evidenced by the fractional shortening measurement and subjective evaluation of the different regions of the myocardium. The **left ventricular outflow** tract demonstrated normal laminar flow and subjective structural integrity. The **right atrium** and auricle revealed normal size, structure and content. No evidence of masses was noted or chamber overload. **Tricuspid** insufficiency was noted. The **right ventricle** was of normal size (1/3 diameter of LV), chordae structure, myocardial echogenicity and thickness. **Pulmonic** tract assessment revealed normal valve structure, laminar flow, and diameter (approx.1:1 pa/ao ratio). No visible **pericardial** or free pleura fluid was noted. No echographically detectable evidence of infiltrative disease was visible. The cranial **mediastinum and pericardial regions** were free of masses in the visible window. Periodic arrhythmia was noted in this patient. Slight B lines were noted.

CANINE CARDIAC PARAMETERS	MR VMAX (m/s)	TR VMAX (m/s)	LA/AO	LA/AO (Heart Base)	FS (%)	EF (%)	EPSS (cm)
NORMAL PARAMETER	4.5-5.5	<2.7	1.3	<1.6	28-40	40-100	<0.6
PATIENT	5.5	-	1.7	1.9	50	80	0.1
CANINE CARDIAC PARAMETERS	HR (BPM)	AV VMAX (m/s)	PV MAX (m/s)	BODY WEIGHT	LA 2D short axis Base view (cm)	LVIDd Avg; 2D and m-mode short axis (cm)	LVIDs Avg; 2D and m-mode short axis (cm)
NORMAL PARAMETER	50-100	0.7-1.7	0.7-1.6	BELOW	BELOW	BELOW	BELOW
PATIENT	-	1.2	-	19.8 lbs	4.7	3.8	



PATIENT

Sammy Illescas

SPECIES

Canine

BREED

Miniature Schnauzer

SEX

Neutered male

AGE

11 years

WEIGHT

19.8 lbs

INTERPRETED BY

Eric Lindquist, DMV
DABVP, Cert. IVUSS

IMAGING PERFORMED BY

Heather

HOSPITAL NAME

Animal Care Center of
Flanders

REFERRING VET

Dr. Hallihan

INVOICE

71364

DATE

2/6/26

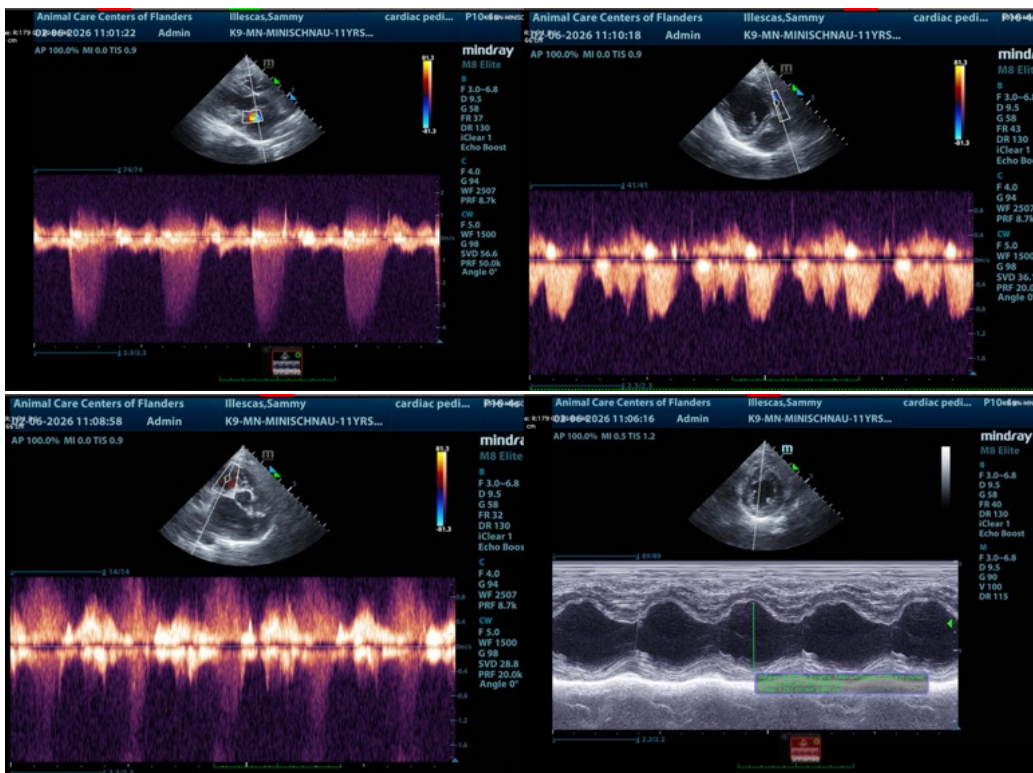
ULTRASONOGRAPHIC FINDINGS

Advanced stage B2-B2+ valvular disease.

INTERPRETATION OF THE FINDINGS & FURTHER RECOMMENDATIONS

There is concern for emerging left-sided heart failure. I recommend initiating Pimobendan at 0.3 mg/kg b.i.d., ace inhibitor at 0.5 mg/kg s.i.d. progressing to b.i.d. and Spironolactone at 1-2 mg/kg b.i.d. If any evidence of pulmonary edema develops then Lasix therapy can be added; however, it was not present on radiographs at this time. Recheck echocardiogram in 1-3 months depending upon clinical progression. If any cough is present then cough suppressants such as Hycodan or similar is indicated.

The heart is in a somewhat precarious state with volume overload and a heart that is working to compensate for the valvular insufficiency. Target respiratory rate is < 20 resp/minute after therapy. After initiating therapy, I recommend recheck on the clinical exam, BUN, Creatinine, USG, Chest radiographs & Blood pressure in 5-7 days. Recheck echo in 1 month. Earlier if clinical decompensation is occurring. I do not recommend anesthesia at this time until stabilization has occurred on the recommended medications. Repeat preanesthetic echo is ideal if anesthesia is eventually necessary.





PATIENT

Sammy Illescas

SPECIES

Canine

BREED

Miniature Schnauzer

SEX

Neutered male

AGE

11 years

WEIGHT

19.8 lbs

INTERPRETED BY

Eric Lindquist, DMV
DABVP, Cert. IVUSS

**IMAGING
PERFORMED BY**

Heather

HOSPITAL NAME

Animal Care Center of
Flanders

REFERRING VET

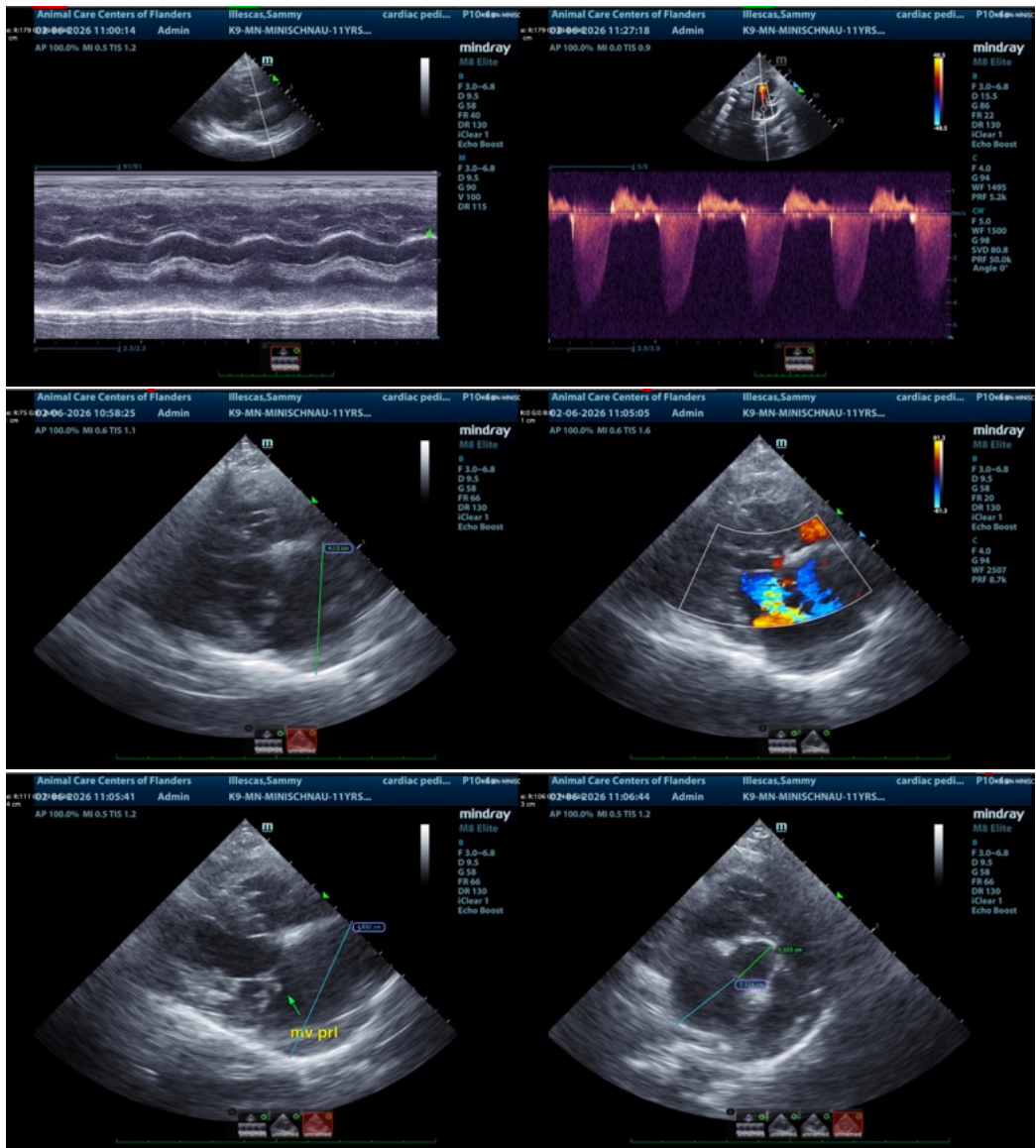
Dr. Hallihan

INVOICE

71364

DATE

2/6/26



The information and recommendations provided are based on the images presented by the referring veterinarian/sonographer. No evaluation can be communicated regarding pathology that was not visible in the image/video clips provided.

Thank you for this referral. If the clinical or image interpretation does not parallel your findings or if I can be of any further assistance please contact me.

Eric Lindquist, DMV, DABVP (CFM), Cert. IVUSS, CEO of SonoPath.com

info@SonoPath.com