



PATIENT

Sadie Brackett

SPECIES

Canine

BREED

Yorkie Poo

SEX

Spayed female

AGE

13 years

WEIGHT

7.9 lbs

INTERPRETED BY

Eric Lindquist, DMV
DABVP, Cert. IVUSS

IMAGING PERFORMED BY

Darice Ackerson
Gordon

HOSPITAL NAME

Clover Croft VH

REFERRING VET

Dr. Harris

INVOICE

71366

DATE

2/6/26

PRESENTING CLINICAL SIGNS

- No murmur, enlarged heart

ULTRASONOGRAPHIC EXAMINATION OF THE HEART

Multiple long axis and short axis views as well as oblique views were submitted for evaluation. Globally the heart presented normal volumes and contractility. There was no evidence of volume overload or pressure overload noted. The hepatic veins were not dilated. The visible valvular structures appear to be normal. There was no pericardial or pleural effusion noted.

CANINE CARDIAC PARAMETERS	MR VMAX (m/s)	TR VMAX (m/s)	LA/AO	LA/AO (Heart Base)	FS (%)	EF (%)	EPSS (cm)
NORMAL PARAMETER	4.5-5.5	<2.7	1.3	<1.6	28-40	40-100	<0.6
PATIENT	NM	NM	NM	1.3	35	NM	NM
CANINE CARDIAC PARAMETERS	HR (BPM)	AV VMAX (m/s)	PV MAX (m/s)	BODY WEIGHT	LA 2D short axis Base view (cm)	LVIDd Avg; 2D and m-mode short axis (cm)	LVIDs Avg; 2D and m-mode short axis (cm)
NORMAL PARAMETER	50-100	0.7-1.7	0.7-1.6	BELOW	BELOW	BELOW	BELOW
PATIENT	80	NM	1.1	7.9 lbs	NM	1.5	-

ULTRASONOGRAPHIC FINDINGS

Structurally unremarkable heart, subjectively normal chamber size, structure and function.

INTERPRETATION OF THE FINDINGS & FURTHER RECOMMENDATIONS

There was no evidence of pathology.



PATIENT

Sadie Brackett

SPECIES

Canine

BREED

Yorkie Poo

SEX

Spayed female

AGE

13 years

WEIGHT

7.9 lbs

INTERPRETED BY

Eric Lindquist, DMV
DABVP, Cert. IVUSS

IMAGING PERFORMED BY

Darice Ackerson
Gordon

HOSPITAL NAME

Clover Croft VH

REFERRING VET

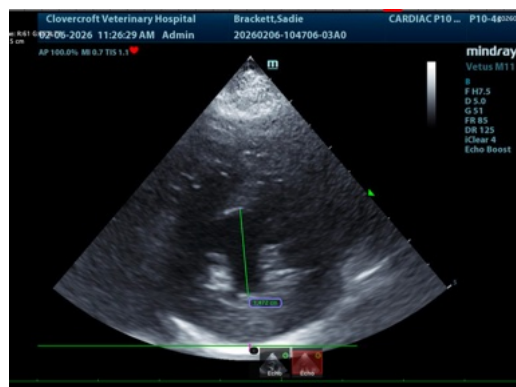
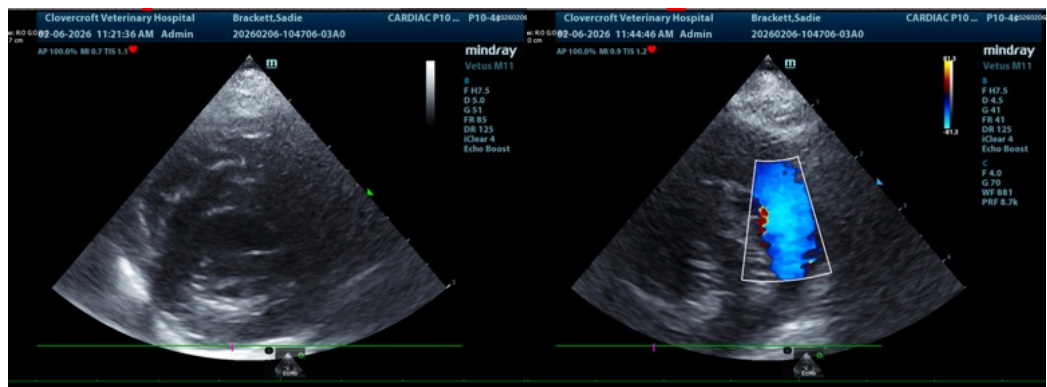
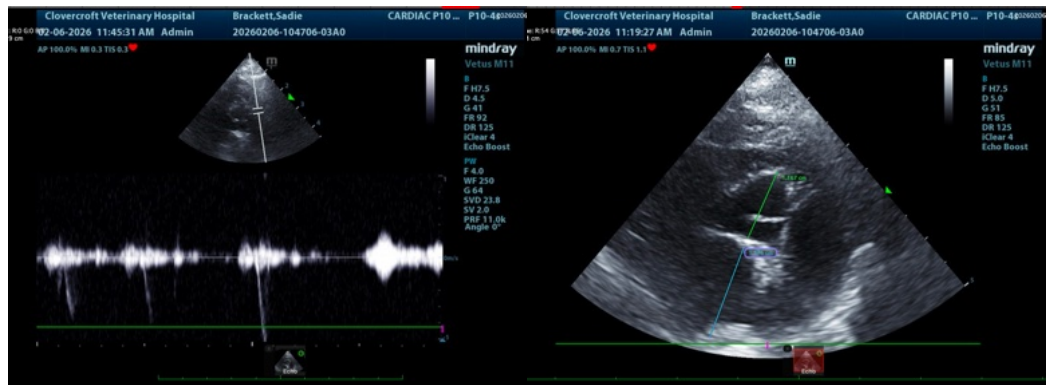
Dr. Harris

INVOICE

71366

DATE

2/6/26



The information and recommendations provided are based on the images presented by the referring veterinarian/sonographer. No evaluation can be communicated regarding pathology that was not visible in the image/video clips provided.

Thank you for this referral. If the clinical or image interpretation does not parallel your findings or if I can be of any further assistance please contact me.

Eric Lindquist, DMV, DABVP (CFM), Cert. IVUSS, CEO of SonoPath.com

info@SonoPath.com