



**PATIENT**

Fenway Sivo

**SPECIES**

Feline

**BREED**

Korat

**SEX**

Neutered Male

**AGE**

16 Years

**WEIGHT**

4.35 kg

**INTERPRETED BY**

Eric Lindquist, DMV,  
DABVP (CFM), Cert.  
IVUSS

**IMAGING PERFORMED BY**

Vincent Ravancho, CVT

**HOSPITAL NAME**

Bond Vet Montclair

**REFERRING VET**

Dr. Sposato

**INVOICE**

35735

**DATE**

2/6/26

**PRESENTING CLINICAL SIGNS**

- Inappropriate Eliminations
- Clinical findings WNL
- Abnormal PE/Chem/CBC/UA Results: No recent Labwork, Labwork from June 2025 WNL

**ULTRASONOGRAPHIC EXAMINATION OF THE ABDOMEN**

**Urinary System**

The **urinary bladder**, trigone, and pelvic urethra presented normal thicknesses and normal tone. The ureters were not visible which is normal. No uroliths or sediment were visualized and anechoic urine was present. No evidence of inflammatory or neoplastic changes were noted. Ureteral papillae were normal. The pelvic urethra was imaged 2.0 cm beyond the cystourethral junction.

The **kidneys** revealed largely normal size and structure, corticomedullary definition and ratio (cortex 1/3 of medulla) were essentially maintained with some mild age-related loss of curvilinear patterns regarding the capsule and C/M junction. The cortices presented largely uniform texture with some increased echogenicity expected for this age patient. Medullary structure differed distinctly from that of the cortex, and no evidence of pelvic dilation was present. The left kidney measured 3.5 cm. The right kidney measured 3.5 cm.

**Adrenal Glands**

Both **adrenal glands** were visualized and recognized as having normal shape, size, position and echogenicity for this breed. The phrenic vasculature, glandular echogenicity and detail were unremarkable. Capsule, cortex, and medullary definition were normal for this age patient. The right adrenal gland measured 0.36 cm. The left adrenal gland measured 0.33 cm.

**Spleen**

The **spleen** presented a smooth homogeneous parenchyma hyperechoic to liver and renal cortical parenchyma. The capsule was smooth without noticeable expansion or deviation from within the spleen or adjacent pathology. The splenic vasculature demonstrated normal volume without signs of congestion or thrombosis. No sonographic evidence of acute or chronic inflammatory, neoplastic, or infarctual changes were noted.

**Liver**

The **liver** images submitted revealed subjectively normal liver size, contour, and structure. Parenchymal echogenicity was naturally coarse and hypoechoic to the spleen. Vascular and biliary tracts were of normal volume with no evidence of congestion. The gallbladder presented acceptably thin walls with primarily anechoic content. The cystic and common bile ducts were normal. No pathological hepatic lymphadenopathy was evident. No overt structural evidence of inflammatory, infiltrative or regenerative pathology was evident.

**Gastrointestinal**



**PATIENT**

Fenway Sivo

**SPECIES**

Feline

**BREED**

Korat

**SEX**

Neutered Male

**AGE**

16 Years

**WEIGHT**

4.35 kg

**INTERPRETED BY**

Eric Lindquist, DMV,  
DABVP (CFM), Cert.  
IVUSS

**IMAGING PERFORMED BY**

Vincent Ravancho, CVT

**HOSPITAL NAME**

Bond Vet Montclair

**REFERRING VET**

Dr. Sposato

**INVOICE**

35735

**DATE**

2/6/26

The **gastrointestinal tract** revealed minor variable thickening and echogenic submucosal changes most consistent with low grade end result of chronic GI disease such as IBD and may be related to malassimilation of nutrients if any weight loss is present. No obvious neoplastic patterns were noted and luminal content as unremarkable. This is a minor change.

**Pancreas**

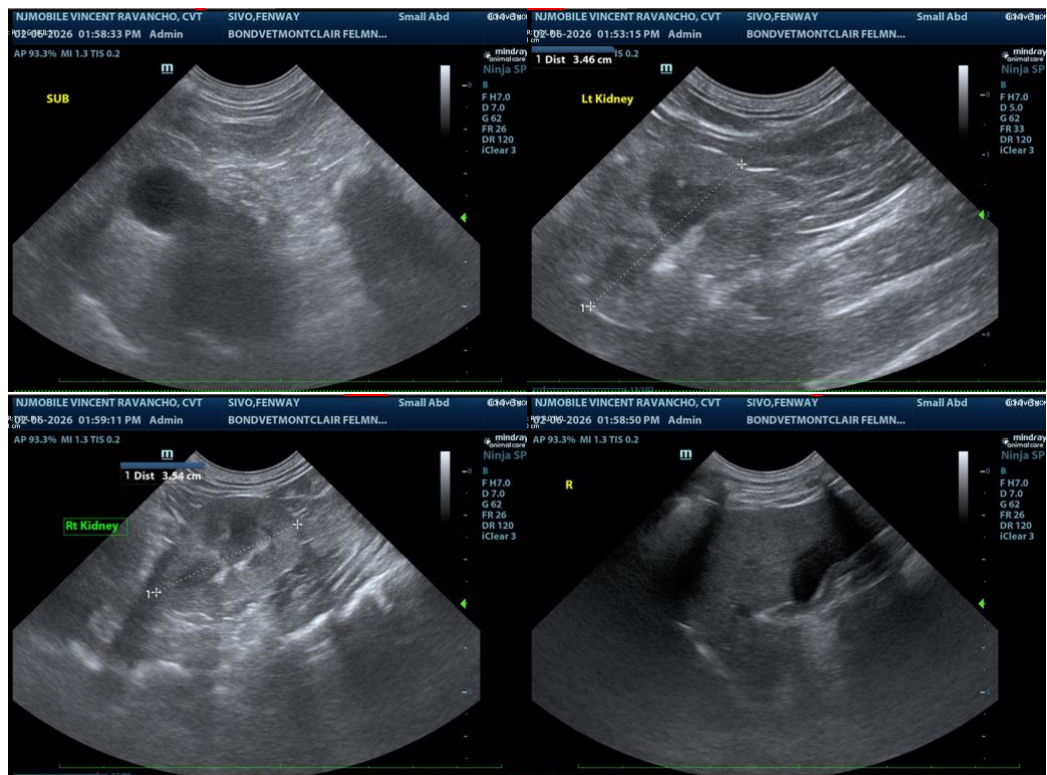
The base and limbs of the **pancreas** were observed to be largely isoechoic to surrounding omental fat. Pancreatic duct and capsular contour were acceptably normal and parenchyma respected normal curvilinear patterns. No overt evidence of active inflammatory or neoplastic disease was noted.

**ULTRASONOGRAPHIC FINDINGS**

- Geriatric abdomen without specific pathology.

**INTERPRETATION OF THE FINDINGS & FURTHER RECOMMENDATIONS**

The cause of inappropriate elimination is not evident in the visible pelvic urethra and descending colon. Environmental stressors, behavioral issues, and orthopedic disease should all be considered in this patient, as viscerally the abdomen is unremarkable. Cannot rule out deep pelvic inlet pathology, however, in the visible plane, there is no evidence of pathology.





**PATIENT**

Fenway Sivo

**SPECIES**

Feline

**BREED**

Korat

**SEX**

Neutered Male

**AGE**

16 Years

**WEIGHT**

4.35 kg

**INTERPRETED BY**

Eric Lindquist, DMV,  
 DABVP (CFM), Cert.  
 IVUSS

**IMAGING PERFORMED BY**

Vincent Ravancho, CVT

**HOSPITAL NAME**

Bond Vet Montclair

**REFERRING VET**

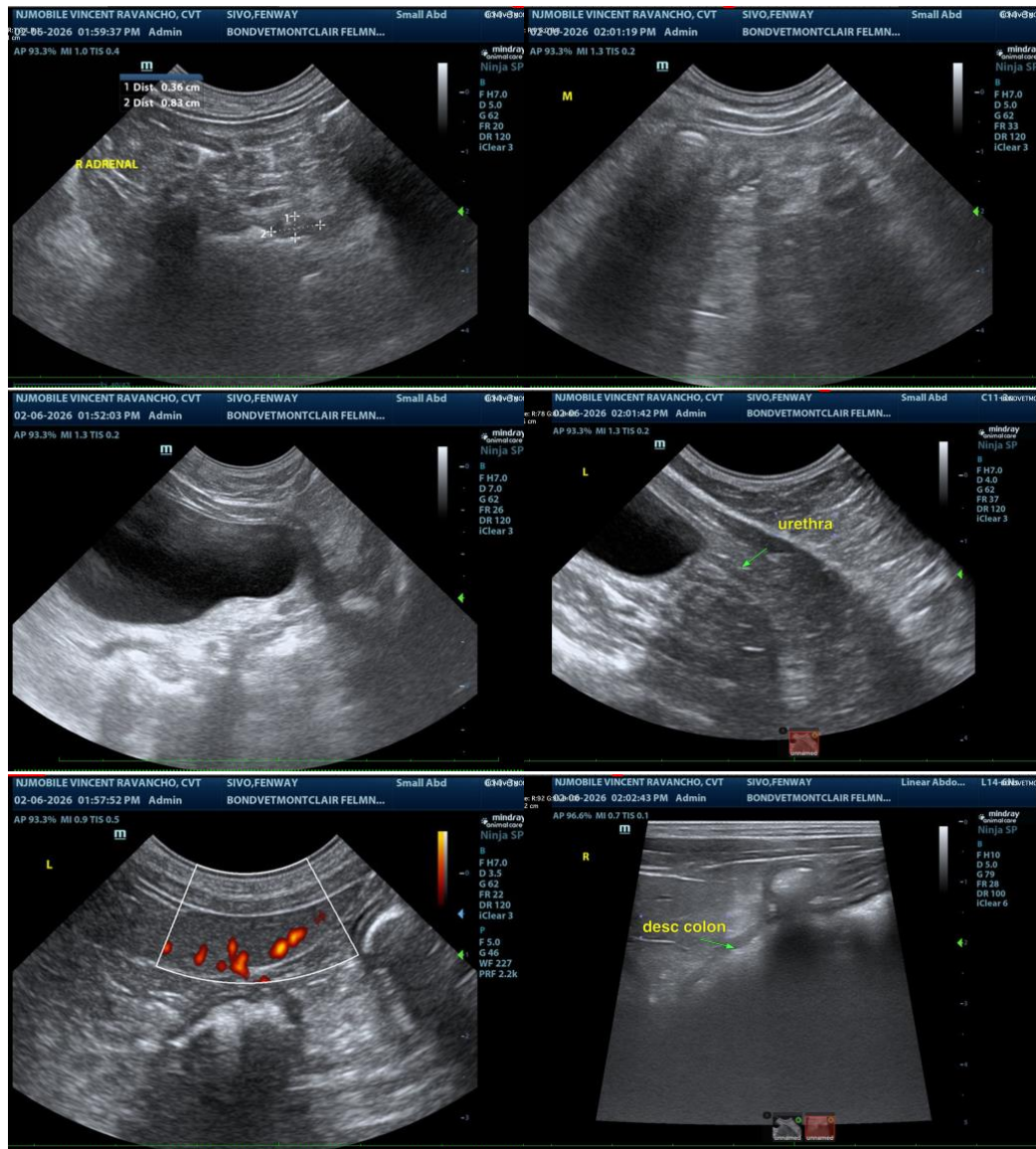
Dr. Sposato

**INVOICE**

35735

**DATE**

2/6/26



The information and recommendations provided are based on the images presented by the referring veterinarian/sonographer. No evaluation can be communicated regarding pathology that was not visible in the image/video clips provided.

Thank you for this referral. If the clinical or image interpretation does not parallel your findings or if I can be of any further assistance please contact me.

**Eric Lindquist**, DMV, DABVP(CFM), Cert. IVUSS,  
 CEO, Owner, Founder -- SonoPath.com  
[info@SonoPath.com](mailto:info@SonoPath.com)



**PATIENT**

Fenway Sivo

**SPECIES**

Feline

**BREED**

Korat

**SEX**

Neutered Male

**AGE**

16 Years

**WEIGHT**

4.35 kg

**INTERPRETED BY**

Eric Lindquist, DMV,  
DABVP (CFM), Cert.  
IVUSS

**IMAGING  
PERFORMED BY**

Vincent Ravancho, CVT

**HOSPITAL NAME**

Bond Vet Montclair

**REFERRING VET**

Dr. Sposato

**INVOICE**

35735

**DATE**

2/6/26