



PATIENT

Bella Noordyk

SPECIES

Canine

BREED

Shih-Poo

SEX

Spayed Female

AGE

13 Years 2 Months

WEIGHT

29.5 Pounds

INTERPRETED BY

Eric Lindquist, DMV,
DABVP (Canine &
Feline), Cert. IVUSS

IMAGING PERFORMED BY

Vincent Ravancho, CVT

HOSPITAL NAME

Legacy AH

REFERRING VET

Dr. Kristin Potenzzone

INVOICE

35734

DATE

2/6/26

PRESENTING CLINICAL SIGNS

- 4/6 HM, Want Baseline
- Mild Cough
- Abnormal PE/Chem/CBC/UA Results: WNL No BNP done

ULTRASONOGRAPHIC EXAMINATION OF THE HEART

CANINE CARDIAC PARAMETERS	MR VMAX (m/s)	TR VMAX (m/s)	LA/AO (M-Mode)	LA/AO (Heart Base; Swe)	FS (%)	EF (%)	EPSS (cm)
NORMAL PARAMETER	4.5-5.5	<2.7	1.3	Up to 1.6	28-40	40-100	<0.6
PATIENT	5.8	--	1.3	1.1	57	89	0.1
CANINE CARDIAC PARAMETERS	HR (BPM)	AV VMAX (m/s)	PV MAX (m/s)	BODY WEIGHT (lbs)	LAD LA MAX 4 Chamber	LVIDd Avg; 2D and m-mode short axis (cm)	LVIDs Avg; 2D and m-mode short axis (cm)
NORMAL PARAMETER	50-100	0.7-1.7	0.7-1.6				
PATIENT	120	1.40	1.90	29.5 lbs	2.00	2.67	--

Cardiac Presentation

The echocardiogram in this patient demonstrated normal **left atrial** size based on 3 different LA measurement methods. Chamber volumes and echogenicity were normal. The cranial and caudal **mitral** valve leaflets presented vegetative thickening consistent with endocardiosis. Doppler indicated measurable insufficiency. The **left ventricle** presented thicknesses with linear contour and was not dilated nor restricted. The **myocardium** presented normal echogenicity without subjective evidence of significant fibrotic or ischemic disease. **Contractility** of the ventricular walls was adequate and in normal range for this patient evidenced by the fractional shortening measurement and subjective evaluation of the different regions of the myocardium. The **left ventricular outflow** tract demonstrated normal laminar flow and subjective structural integrity. The **right atrium** and auricle revealed normal size, structure and content. No evidence of masses was noted or chamber overload. **Tricuspid** valvular assessment demonstrated adequate linear morphology. The **right ventricle** was of normal size (1/3 diameter of LV), chordae structure, myocardial echogenicity and thickness. **Pulmonic** tract assessment revealed normal valve structure, laminar flow, and diameter (approx.1:1 pa/ao ratio). No visible **pericardial** or free pleura fluid was noted. No echographically detectable evidence of



PATIENT

Bella Noordyk

SPECIES

Canine

BREED

Shih-Poo

SEX

Spayed Female

AGE

13 Years 2 Months

WEIGHT

29.5 Pounds

INTERPRETED BY

Eric Lindquist, DMV,
DABVP (Canine & Feline), Cert. IVUSS

IMAGING PERFORMED BY

Vincent Ravancho, CVT

HOSPITAL NAME

Legacy AH

REFERRING VET

Dr. Kristin Potenzzone

INVOICE

35734

DATE

2/6/26

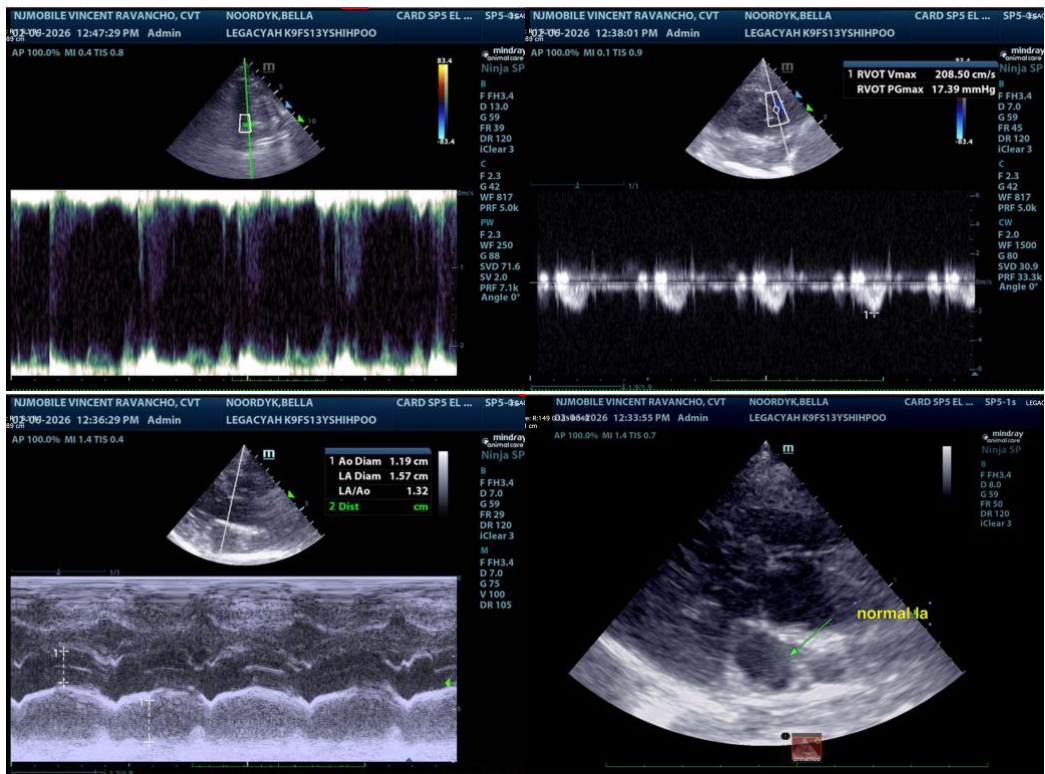
infiltrative disease was visible. The cranial **mediastinum and pericardial regions** were free of masses in the visible window.

ULTRASONOGRAPHIC FINDINGS

- Stage B-1 valvular disease, compensated

INTERPRETATION OF THE FINDINGS & FURTHER RECOMMENDATIONS

The heart is stable without clinical disease. No overt contraindication for anesthesia of brief to moderate duration. I suggest Torbutrol premed, Propofol induction, Isoflo maintenance or similar protocol if anesthesia is desired. Blood pressure recommended if not already performed and target white coat negative systolic pressure of < 160 mmHg. If higher than this ACE-inhibitor is suggested to reach this level. Recheck echocardiogram is recommended in 6 months, earlier if murmur grade increases or clinical signs initiate.





PATIENT

Bella Noordyk

SPECIES

Canine

BREED

Shih-Poo

SEX

Spayed Female

AGE

13 Years 2 Months

WEIGHT

29.5 Pounds

INTERPRETED BY

Eric Lindquist, DMV,
DABVP (Canine &
Feline), Cert. IVUSS

**IMAGING
PERFORMED BY**

Vincent Ravancho, CVT

HOSPITAL NAME

Legacy AH

REFERRING VET

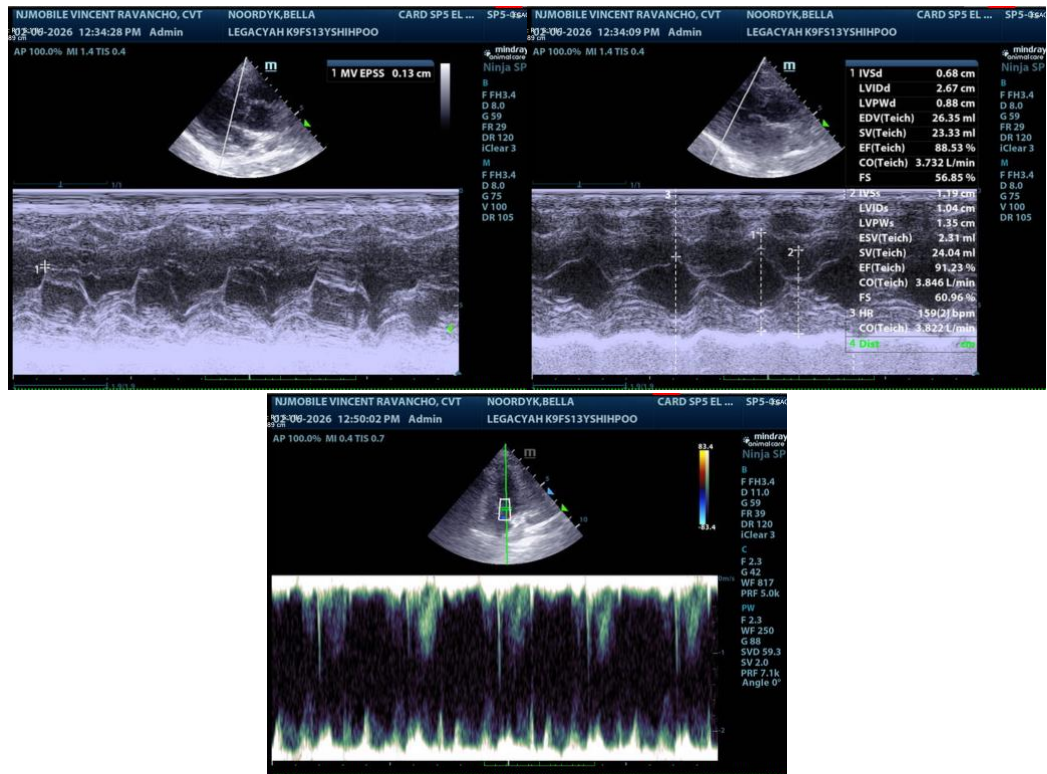
Dr. Kristin Potenzzone

INVOICE

35734

DATE

2/6/26



The information and recommendations provided are based on the images presented by the referring veterinarian/sonographer. No evaluation can be communicated regarding pathology that was not visible in the image/video clips provided.

Thank you for this referral. If the clinical or image interpretation does not parallel your findings or if I can be of any further assistance please contact me.

Eric Lindquist, DMV, DABVP(CFM), Cert. IVUSS,
CEO, Owner, Founder -- SonoPath.com
info@SonoPath.com