

**DATE PRESENTING CLINICAL SIGNS**

2/6/23

P has a history of MCT - first mass removed (that we have record of was 1/25/22) but possible removal of another MCT prior to that. FNA of spleen completed at the same time - no evidence of MCT (through intrapet) 1/25/23 - P diagnosed with another MCT - P has sx scheduled for removal.

PATIENT

Sparta Sanchez

Current Medications: 1/20/23 - tramadol 100mg BID and gaba 300mg BID for dental procedure

Lab Results: Total health - WNL. Cytology - consistent with MCT

Date of Previous IntraPet Ultrasound: 1/4/22. See attached.

Sedation: IV Torb.

Stat Report: Not requested.

Imaging Performed By: Rachel Brillhart, RDMS.

SPECIES

Canine

BREED

Unknown

SEX

Spayed female

AGE

3/18/13

WEIGHT

93 lbs

INTERPRETED BY

Eric Lindquist, DMV
DABVP, Cert. IVUSS

HOSPITAL NAME

Warm and Fuzzy VC

REFERRING VET

Dr. Weber

INVOICE

42574

ULTRASONOGRAPHIC EXAMINATION OF THE ABDOMEN**Urinary System**

The **urinary bladder**, trigone, and pelvic urethra presented normal thicknesses and normal tone. The ureters were not visible which is normal. No uroliths or sediment were visualized and anechoic urine was present. No evidence of inflammatory or neoplastic changes was noted. Ureteral papillae were normal.

The **kidneys** revealed largely normal size and structure, corticomedullary definition and ratio (cortex 1/3 of medulla) were essentially maintained with some age-related loss of curvilinear patterns regarding the capsule and C/M junction. The cortices presented largely uniform texture with some increased echogenicity expected for his age patient. Medullary structure differed distinctly from that of the cortex and no evidence of pelvic dilation was present. The right kidney measured 7.27 cm. The left kidney measured 7.53 cm.

Adrenal Glands

The right **adrenal gland** revealed an intraparenchymal non expansive nodule measuring 8 mm.. The right adrenal gland measured 3.32 x 0.65 cm at the caudal pole and 0.78 cm at the cranial pole. The left adrenal gland revealed a newly developed 0.84 x 0.66 cm nodule at the caudal pole. The left adrenal gland measured 2.9 x 0.85 cm at the caudal pole and 0.57 cm at the cranial pole.

Spleen

The **spleen** revealed multi-focal, hypoechoic nodular changes that measured up to 0.6 cm. If not already aspirated FNA is indicated.

Liver

The **liver** presented heterogenous parenchyma with increased portal markings and coarse architecture. Slight undulating capsular contour was noted. The gallbladder and common bile duct were unremarkable. This is consistent with chronic inflammatory hepatopathy.

Gastrointestinal

Examination of the **gastrointestinal tract** revealed a stomach and intestine free of stasis, of normal wall thickness, acceptable curvilinear mural detail, and peristaltic activity. Small and large intestine demonstrated normal luminal chyme and stool consistency respectively. No obstructive or overt infiltrative disease was noted. No associated abnormal lymphatic activity was noted.

Pancreas

The base and limbs of the **pancreas** were observed to be largely isoechoic to surrounding omental fat. Pancreatic duct and capsular contour were acceptably normal and parenchyma respected normal curvilinear patterns. No overt evidence of active inflammatory or neoplastic disease was noted.

ULTRASONOGRAPHIC FINDINGS

Unspecific splenic nodular changes.

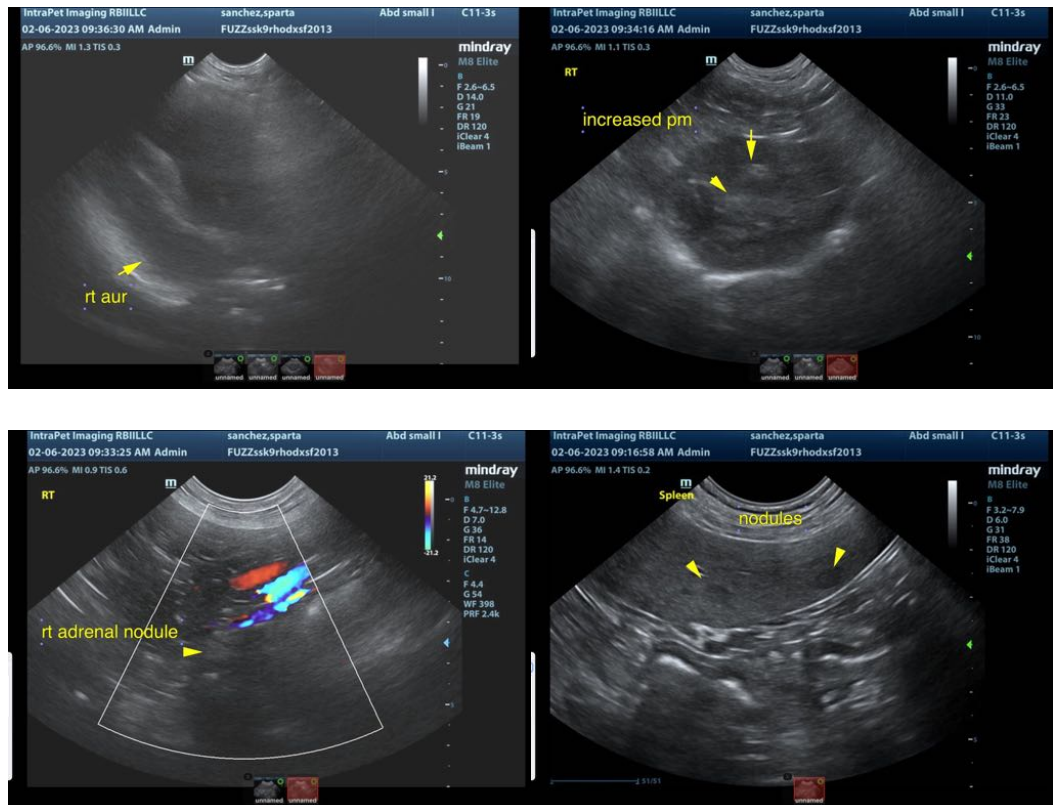
Newly developed right adrenal nodule, new development. Likely hyperplasia.

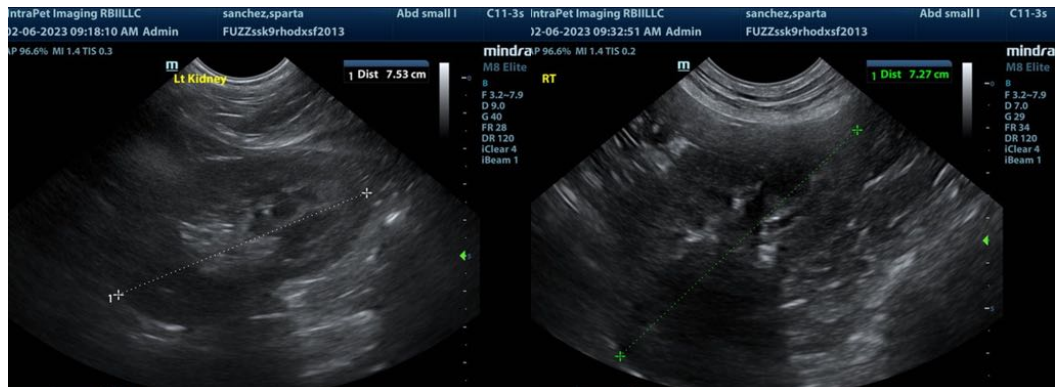
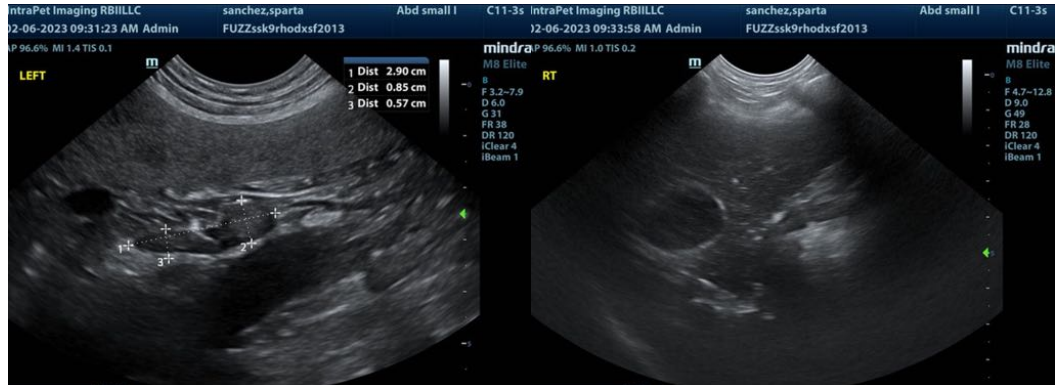
Left adrenal nodule, likely hyperplasia.

Mild hepatic remodeling, new progression from the prior sonogram.

INTERPRETATION OF THE FINDINGS & FURTHER RECOMMENDATIONS

If FNA of the spleen has not been performed then FNA is indicated. Blood pressure measurement is warranted to ensure that hypertension is not an issue.





The information and recommendations provided are based on the images presented by the referring veterinarian. No evaluation can be communicated regarding pathology that was not visible in the image/video clips provided.

Thank you for this referral. If the clinical or image interpretation does not parallel your findings or if I can be of any further assistance please contact me.

Eric Lindquist, DMV, DABVP, Cert. IVUSS, CEO of SonoPath.com
 Eric.Lindquist@SonoPath.com