



PATIENT

Rango Kuhn

SPECIES

Canine

BREED

Boxer Mix

SEX

Neutered male

AGE

11 years

WEIGHT

89 lbs

INTERPRETED BY

Eric Lindquist, DMV
DABVP, Cert. IVUSS

IMAGING PERFORMED BY

Dr. Bray

HOSPITAL NAME

Taylorville VC

REFERRING VET

Dr. Bray

INVOICE

42562

DATE

2/6/23

PRESENTING CLINICAL SIGNS

History: P has been pretty healthy overall until past few months, his appetite and thirst have increased with a small amount of weight loss.

Abnormal PE/Chem/CBC/UA Results: PE is unremarkable besides some chronic nodules/skin tags and mild dental disease. Weight loss of 4lbs in 8 months. P is currently 4/9 BCS. Hx of mild SDMA fluctuations. Last month labs showed mild SDMA, ALP, Cholesterol and Lipase increases. We are waiting on GI panel

ULTRASONOGRAPHIC EXAMINATION OF THE ABDOMEN

Urinary System

The **urinary bladder**, trigone, and pelvic urethra presented normal thicknesses and normal tone. The pelvic urethra was imaged 2.0 cm beyond the cystourethral junction and appeared normal. The ureters were not visible which is normal. No uroliths or sediment were visualized and anechoic urine was present. No evidence of inflammatory or neoplastic changes was noted. Ureteral papillae were normal.

The **kidneys** revealed largely normal size and structure, corticomedullary definition and ratio (cortex 1/3 of medulla) were essentially maintained with some age-related loss of curvilinear patterns regarding the capsule and C/M junction. The cortices presented largely uniform texture with some increased echogenicity expected for his age patient. Medullary structure differed distinctly from that of the cortex and no evidence of pelvic dilation was present. An anechoic cyst was noted in the caudal pole of the left kidney. The left kidney measured 7.4 cm. The right kidney measured 6.7 cm. A 1.0 cm cyst was noted at the caudal pole of the right kidney. An anechoic cyst was noted at the cranial pole of the right kidney as well.

Adrenal Glands

Both **adrenal glands** were visualized and recognized as having normal shape, size, position and echogenicity for this breed. The phrenic vasculature, glandular echogenicity and detail were unremarkable. Capsule, cortex, and medullary definition were normal for this age patient. The left adrenal gland measured 0.5 cm. The right adrenal gland measured 0.6 cm at the cranial pole and 0.5 cm at the caudal pole.

Spleen

The **spleen** presented a smooth homogeneous parenchyma hyperechoic to liver and renal cortical parenchyma. The capsule was smooth without noticeable expansion or deviation from within the spleen or adjacent pathology. The splenic vasculature demonstrated normal volume without signs of congestion or thrombosis. No sonographic evidence of acute or chronic inflammatory, neoplastic, or infarctual changes was noted.

Liver

The **liver** images from right and left intercostal as well as subcostal views revealed subjectively normal liver size, contour, and structure. Some age-related parenchymal remodeling was noted but likely not



PATIENT

Rango Kuhn

clinically significant at this time. Vascular and biliary tracts were of normal volume and no evidence of congestion was noted. The gallbladder presented some dependent debris with essentially normal contour. The cystic and common bile ducts were normal. No overt evidence of active inflammatory, infiltrative or regenerative pathology was noted but should be paired with current or past LE elevations regarding any clinical significance to this presentation. The hepatic lymph nodes were unremarkable.

SPECIES

Canine

Gastrointestinal

BREED

Boxer Mix

Examination of the **gastrointestinal tract** revealed a stomach and intestine free of stasis, of normal wall thickness, acceptable curvilinear mural detail, and peristaltic activity. Small and large intestine demonstrated normal luminal chyme and stool consistency respectively. No obstructive or overt infiltrative disease was noted. No associated abnormal lymphatic activity was noted.

SEX

Neutered male

Pancreas

AGE

11 years

The base and limbs of the **pancreas** were observed to be largely isoechoic to surrounding omental fat. Pancreatic duct and capsular contour were acceptably normal and parenchyma respected normal curvilinear patterns. No overt evidence of active inflammatory or neoplastic disease was noted.

WEIGHT

89 lbs

ULTRASONOGRAPHIC FINDINGS

Polycystic renal changes, subjectively benign.

Mild hepatic remodeling.

Structurally normal adrenal glands at this time.

INTERPRETED BY

Eric Lindquist, DMV
DABVP, Cert. IVUSS

INTERPRETATION OF THE FINDINGS & FURTHER RECOMMENDATIONS

There was no evidence of significant disease.

IMAGING PERFORMED BY

Dr. Bray

HOSPITAL NAME

Taylorville VC

REFERRING VET

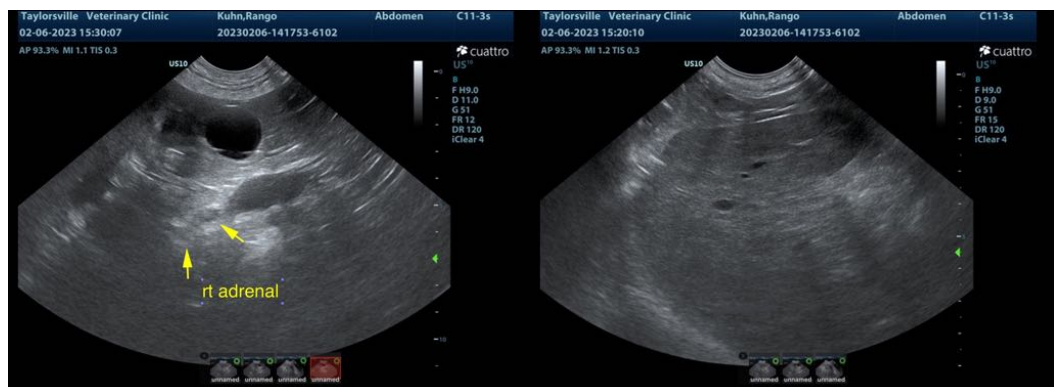
Dr. Bray

INVOICE

42562

DATE

2/6/23





PATIENT

Rango Kuhn

SPECIES

Canine

BREED

Boxer Mix

SEX

Neutered male

AGE

11 years

WEIGHT

89 lbs

INTERPRETED BY

Eric Lindquist, DMV
DABVP, Cert. IVUSS

IMAGING PERFORMED BY

Dr. Bray

HOSPITAL NAME

Taylorville VC

REFERRING VET

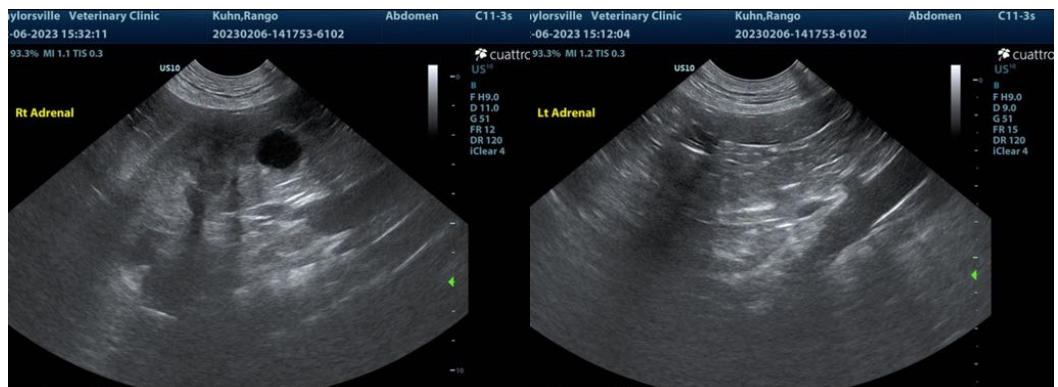
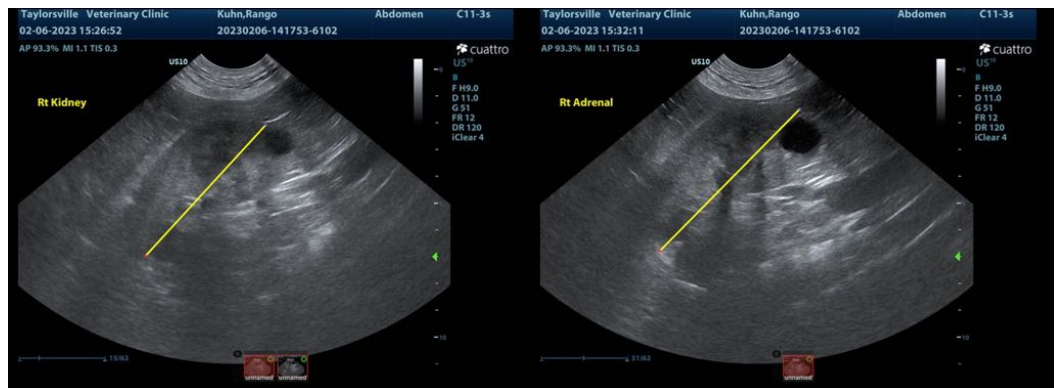
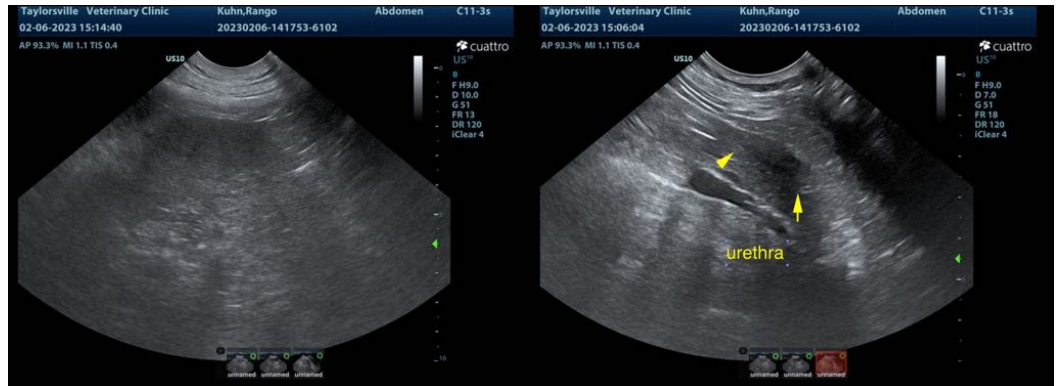
Dr. Bray

INVOICE

42562

DATE

2/6/23



The information and recommendations provided are based on the images presented by the referring veterinarian/sonographer. No evaluation can be communicated regarding pathology that was not visible in the image/video clips provided.

Thank you for this referral. If the clinical or image interpretation does not parallel your findings or if I can be of any further assistance please contact me.

Eric Lindquist, DMV, DABVP, Cert. IVUSS, CEO of SonoPath.com
info@SonoPath.com