



PATIENT

Buddy Woodworth

PRESENTING CLINICAL SIGNS

History: Wellness bloodwork showed elevated kidney values - recommended US

SPECIES

Feline

ULTRASONOGRAPHIC EXAMINATION OF THE ABDOMEN

Urinary System

BREED

DSH

The **urinary bladder**, trigone, and pelvic urethra presented normal thicknesses and normal tone. The ureters were not visible which is normal. No uroliths or sediment were visualized and anechoic urine was present. No evidence of inflammatory or neoplastic changes were noted. Ureteral papillae were normal. The pelvic urethra was imaged 2.0 cm beyond the cystourethral junction.

SEX

Neutered Male

The **kidneys** revealed interstitial nephrosis pattern, multiple infarcts and cortical remodeling bilaterally. The left kidney was subnormal in size, measuring 2.88 cm. The right kidney measured 2.9 cm.

Adrenal Glands

AGE

8

The regions of the **adrenal glands** revealed no evidence of pathology.

Spleen

WEIGHT

8.5

The **spleen** presented a smooth homogeneous parenchyma hyperechoic to liver and renal cortical parenchyma. The capsule was smooth without noticeable expansion or deviation from within the spleen or adjacent pathology. The splenic vasculature demonstrated normal volume without signs of congestion or thrombosis. No sonographic evidence of acute or chronic inflammatory, neoplastic, or infarctual changes were noted.

INTERPRETED BY

Eric Lindquist, DMV
DABVP, Cert. IVUSS

Liver

The **liver** images submitted revealed subjectively normal liver size, contour, and structure. Parenchymal echogenicity was naturally coarse and hypoechoic to the spleen. Vascular and biliary tracts were of normal volume with no evidence of congestion. The gallbladder presented acceptably thin walls with primarily anechoic content. The cystic and common bile ducts were normal. No pathological hepatic lymphadenopathy was evident. No overt structural evidence of inflammatory, infiltrative or regenerative pathology was evident.

IMAGING PERFORMED BY

Adrienne Waffle

Gastrointestinal

HOSPITAL NAME

Torch Lake VC

Examination of the **gastrointestinal tract** revealed a stomach and intestine free of stasis, of normal wall thickness, acceptable curvilinear mural detail, and peristaltic activity. Small and large intestine demonstrated normal luminal chyme and stool consistency respectively. No obstructive or overt infiltrative disease was noted. No associated abnormal lymphatic activity was noted.

REFERRING VET

Adrienne Waffle

Pancreas

The base and limbs of the **pancreas** were observed to be largely isoechoic to surrounding omental fat. Pancreatic duct and capsular contour were acceptably normal and parenchyma respected normal curvilinear patterns. No overt evidence of active inflammatory or neoplastic disease was noted.

INVOICE

21003

ULTRASONOGRAPHIC FINDINGS

- Chronic interstitial nephrosis with infarcts

DATE

2/6/23

INTERPRETATION OF THE FINDINGS & FURTHER RECOMMENDATIONS



PATIENT

Buddy Woodworth

No evidence of neoplasia, however, the renal presentation, subjectively appears end-stage. 72-hour IV fluid protocol, blood pressures, and urine culture are all indicated, and reassessment of the azotemia.

SPECIES

Feline

BREED

DSH

SEX

Neutered Male

AGE

8

WEIGHT

8.5

INTERPRETED BY

Eric Lindquist, DMV
DABVP, Cert. IVUSS

IMAGING PERFORMED BY

Adrienne Waffle

HOSPITAL NAME

Torch Lake VC

REFERRING VET

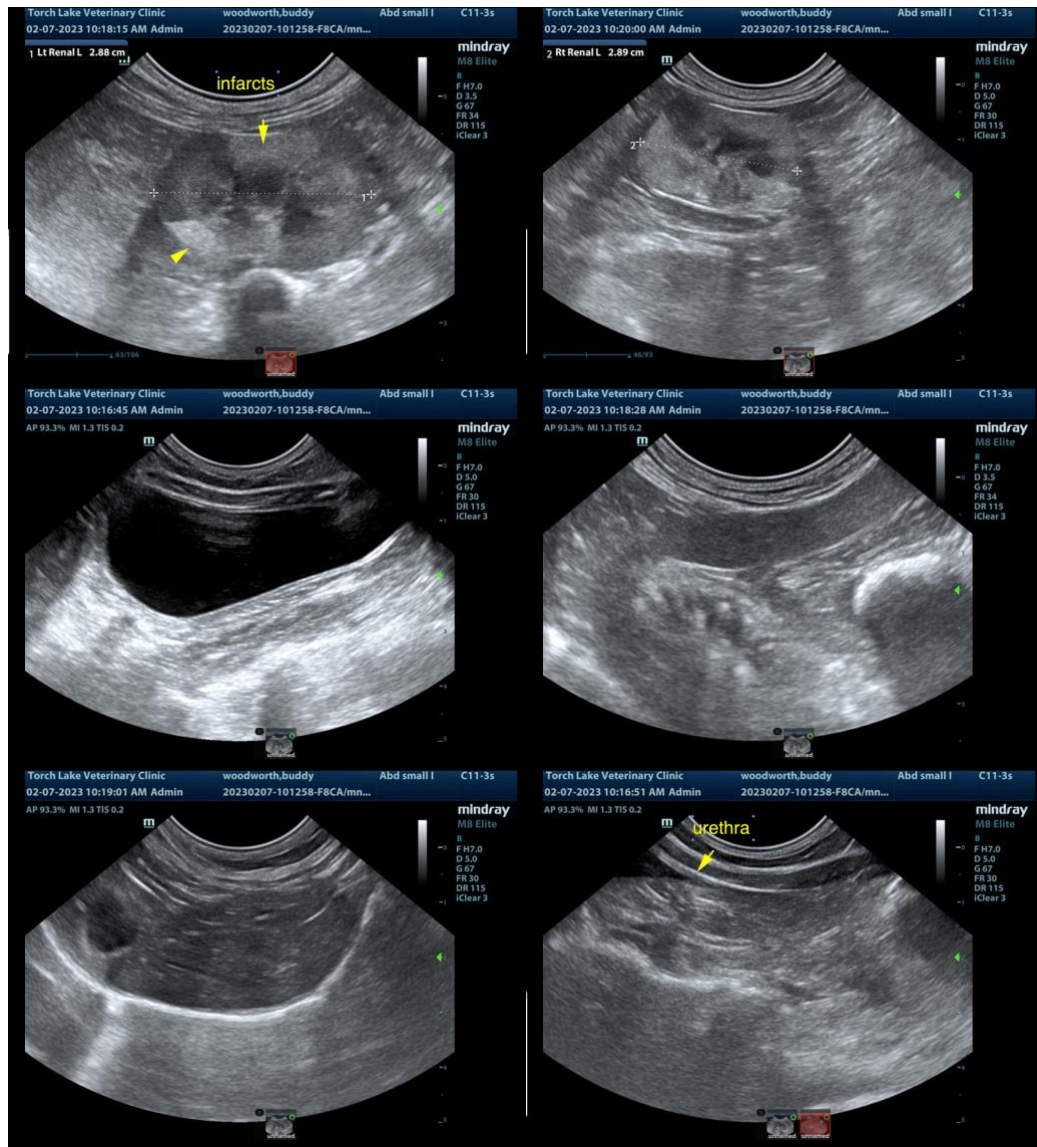
Adrienne Waffle

INVOICE

21003

DATE

2/6/23



The information and recommendations provided are based on the images presented by the referring veterinarian. No evaluation can be communicated regarding pathology that was not visible in the image/video clips provided.

Thank you for this referral. If the clinical or image interpretation does not parallel your findings or if I can be of any further assistance please contact me.

Eric Lindquist, DMV, DABVP, Cert. IVUSS, CEO of SonoPath.com
info@SonoPath.com