



## PATIENT

Loki Reem

## SPECIES

Feline

## BREED

Cross Breed

## SEX

Male

## AGE

6 Months 7 Days

## WEIGHT

2.9 kg

## PRESENTING CLINICAL SIGNS

History: Came for the post-op check following castration. Occasional grade 2 HM was identified in the left and right parasternal regions

Abnormal PE/Chem/CBC/UA Results: Not done

## ULTRASONOGRAPHIC EXAMINATION OF THE HEART

FELINE CARDIAC PARAMETERS	BODY WEIGHT (kg)	HR (BPM)	IVSd (cm)	LVIDd (cm)	LVWd (cm)	FS (%)	EF (%)
NORMAL PARAMETER	-----	150-240	0.3-0.6	1.0-2.1	0.25-0.6	35-67	80-100
PATIENT	--	NM	--	1.23	--	42	77
FELINE CARDIAC PARAMETERS	LA/AO (Boon)	LA/AO HEART BASE (Sisson)	LA 2D 4-chamber long axis AS to FW (Sisson) (cm)	LVOT VEL. (m/s)	RVOT VEL. (m/s)	IVRT (m/)	
NORMAL PARAMETER	<1.5	0.88-1.79	0.7-1.7	<1.6	<1.3	40-60	
PATIENT	--	1.52	1.33	1.16	.73	NM	
Adapted from June Boon, Veterinary Echocardiography, 1998 Sisson D et al. JVIM 1991; 5: 232, Jacobs et al. Am J Vet Res 1985; 46:1705							

## INTERPRETED BY

Eric Lindquist, DMV  
DABVP, Cert. IVUSS

## IMAGING PERFORMED BY

Inam ul haq, DVM,  
MRCVS

## HOSPITAL NAME

City Veterinary Clinic,  
Abu Dhabi, Khalifa City

## REFERRING VET

Inam ul haq, DVM,  
MRCVS

## INVOICE

21008

## DATE

2/5/23

## Cardiac Presentation

The echocardiogram in this patient demonstrated normal **left atrial** size based on 3 separate LA measurements. The cranial and caudal **mitral** valve leaflets presented normal linear structure and kinetics. The **left ventricle** presented normal thicknesses with linear contour and was not dilated nor restricted. The **myocardium** presented normal echogenicity without subjective evidence of significant fibrotic or ischemic disease. **Contractility** of the ventricular walls was adequate and in normal range for this patient evidenced by the fractional shortening measurement and subjective evaluation of the different regions and angles of the myocardium. The **left ventricular outflow** tract demonstrated normal laminar flow and subjective structural integrity. The **right atrium** and auricle revealed normal size, structure and content. No evidence of masses was noted or chamber overload. **Tricuspid** valvular assessment demonstrated adequate linear morphology and kinetics. The **right ventricle** was of normal size (1/3 diameter of LV), chordae structure, myocardial echogenicity and thickness. **Pulmonic** tract assessment revealed normal valve structure, laminar flow, and diameter (approx.1:1 pa/ao ratio). No visible **pericardial** or free pleura fluid was noted or extra cardiac pathology in the visible planes. The cranial **mediastinum and pericardial regions** were free of masses in the visible window.

## ULTRASONOGRAPHIC FINDINGS

- Structurally normal echocardiogram- Likely flow murmur

## INTERPRETATION OF THE FINDINGS & FURTHER RECOMMENDATIONS



**PATIENT**

No evidence of congenital disease.

Loki Reem

Flow murmurs can be caused by volume shifts, anemia, excitable/tachycardic state, DRVOTO (Dynamic Right Ventricular Outflow Obstruction), or even simple stethoscope pressure upon clinical exam.

**SPECIES**

These flow murmurs are typically benign and may develop often later in life theoretically owing to age related clinically insignificant changes of the heart. If the patient is recently clinical for anorexia, weight loss or metabolic disturbances, an abdominal sonogram and full workup may be appropriate to assess underlying clinical systemic causes of a newly developed flow murmur.

Feline

**BREED**

Cross Breed

**SEX**

Male

**AGE**

6 Months 7 Days

**WEIGHT**

2.9 kg

**INTERPRETED BY**

Eric Lindquist, DMV  
DABVP, Cert. IVUSS

**IMAGING PERFORMED BY**

Inam ul haq, DVM,  
MRCVS

**HOSPITAL NAME**

City Veterinary Clinic,  
Abu Dhabi, Khalifa City

**REFERRING VET**

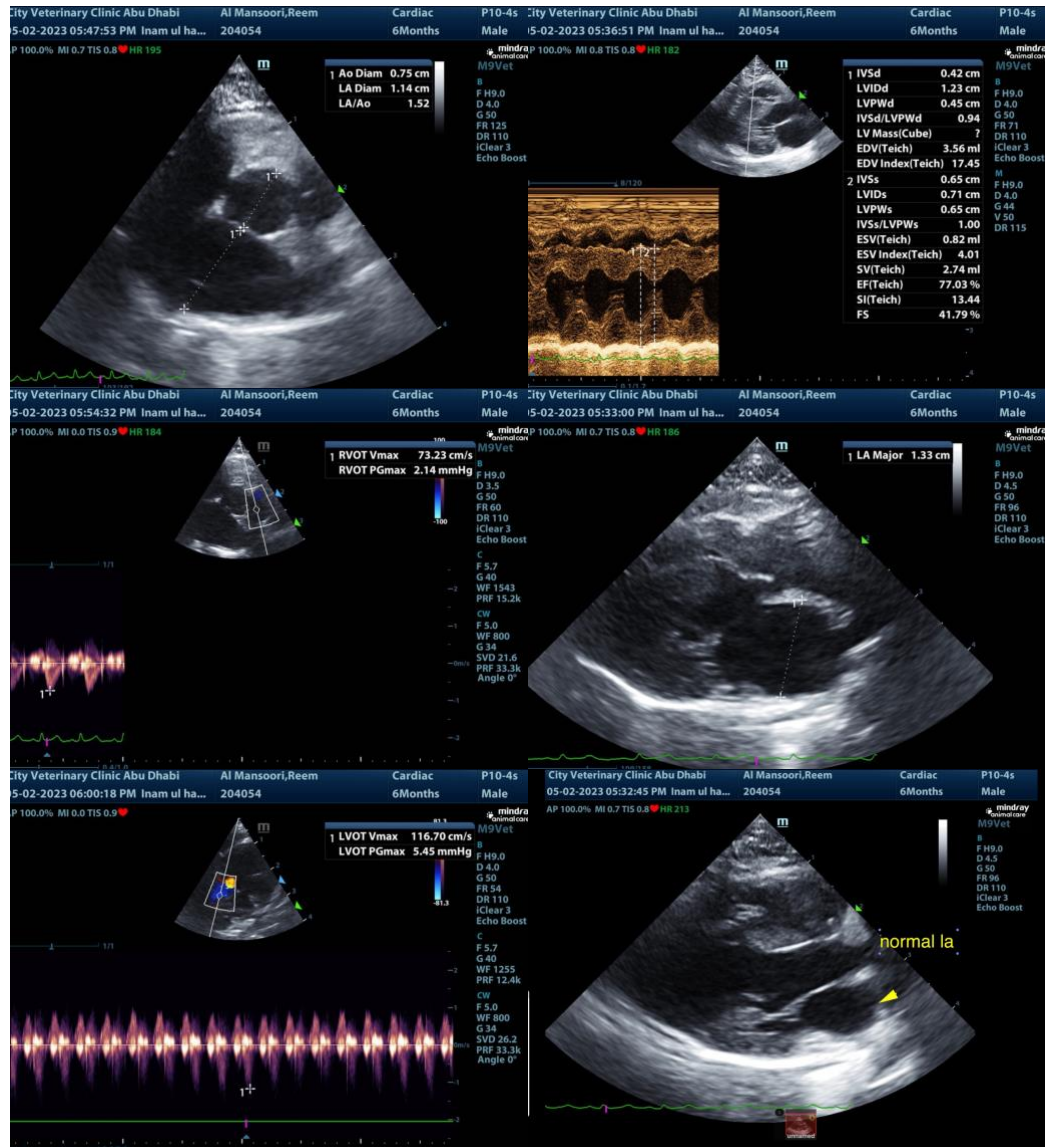
Inam ul haq, DVM,  
MRCVS

**INVOICE**

21008

**DATE**

2/5/23





**PATIENT**

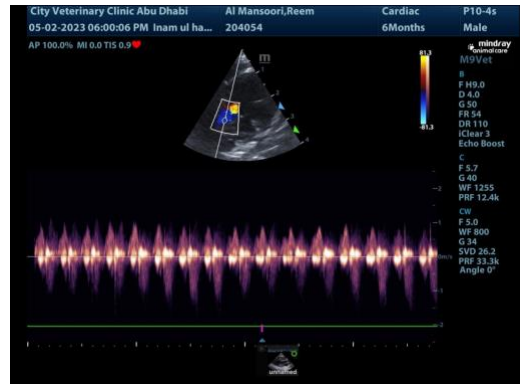
Loki Reem

**SPECIES**

Feline

**BREED**

Cross Breed



**SEX**

Male

**AGE**

6 Months 7 Days

**WEIGHT**

2.9 kg

**INTERPRETED BY**

Eric Lindquist, DMV  
DABVP, Cert. IVUSS

**IMAGING PERFORMED BY**

Inam ul haq, DVM,  
MRCVS

**HOSPITAL NAME**

City Veterinary Clinic,  
Abu Dhabi, Khalifa City

**REFERRING VET**

Inam ul haq, DVM,  
MRCVS

**INVOICE**

21008

**DATE**

2/5/23

The information and recommendations provided are based on the images presented by the referring veterinarian. No evaluation can be communicated regarding pathology that was not visible in the image/video clips provided.

Thank you for this referral. If the clinical or image interpretation does not parallel your findings or if I can be of any further assistance please contact me.

**Eric Lindquist**, DMV, DABVP, Cert. IVUSS, CEO of SonoPath.com  
info@SonoPath.com