



PATIENT

Loki Young

SPECIES

Canine

BREED

Golden Retriever

SEX

Neutered Male

AGE

10 Years

WEIGHT

100

INTERPRETED BY

Eric Lindquist, DMV
DABVP, Cert. IVUSS

IMAGING PERFORMED BY

Griffin

HOSPITAL NAME

Northside VC

REFERRING VET

Griffin

INVOICE

21006

DATE

2/4/23

PRESENTING CLINICAL SIGNS

History: Acute lethargy that started at 3 PM yesterday, Patient vomited large amount of dark vomitus that smelled like fecal material last night. Patient is on gabapentin and pred and levothyroxine. Patient is drinking and keeping water down.

Abnormal PE/Chem/CBC/UA Results: PE: CP deficits in both hind legs, decreased rom in hips Mild painful in cranial abdomen on palpation CBC: WNL today 10 days ago CBC/CHEM: WNL

ULTRASONOGRAPHIC EXAMINATION OF THE ABDOMEN

Urinary System

The **urinary bladder**, trigone, and pelvic urethra presented normal thicknesses and normal tone. The ureters were not visible which is normal. No uroliths or sediment were visualized and anechoic urine was present. No evidence of inflammatory or neoplastic changes were noted. Ureteral papillae were normal.

The **kidneys** revealed largely normal size and structure, corticomedullary definition and ratio (cortex 1/3 of medulla) were essentially maintained with some mild age-related loss of curvilinear patterns regarding the capsule and C/M junction. The cortices presented largely uniform texture with some increased echogenicity expected for his age patient. Medullary structure differed distinctly from that of the cortex and no evidence of pelvic dilation was present. The left kidney measured 7.0 cm. The right kidney measured 7.8 cm.

Adrenal Glands

Both **adrenal glands** were flattened. The right adrenal measured 4.0 mm. The left adrenal gland measured 3.0 mm.

Spleen

The **spleen** presented a smooth homogeneous parenchyma hyperechoic to liver and renal cortical parenchyma. The capsule was smooth without noticeable expansion or deviation from within the spleen or adjacent pathology. The splenic vasculature demonstrated normal volume without signs of congestion or thrombosis. No sonographic evidence of acute or chronic inflammatory, neoplastic, or infarctual changes were noted.

Liver

The **liver** images from right and left intercostal as well as subcostal views revealed subjectively normal liver size, contour, and structure. Some mild age-related parenchymal remodeling was noted but likely not clinically significant at this time. Vascular and biliary tracts were of normal volume and no evidence of congestion was noted. The gallbladder presented some dependent debris with essentially normal contour. The cystic and common bile ducts were normal. No overt evidence of active inflammatory, infiltrative or regenerative pathology was noted but should be paired with current or past LE elevations regarding any clinical significance to this presentation. The hepatic lymph nodes were unremarkable.

Gastrointestinal

The **stomach** was slightly irregular at the cranial aspect of the pyloric outflow. Minor hypertrophy was noted with an empty lumen. The small intestine and colon were unremarkable.



PATIENT

Loki Young

SPECIES

Canine

BREED

Golden Retriever

SEX

Neutered Male

AGE

10 Years

WEIGHT

100

INTERPRETED BY

Eric Lindquist, DMV
DABVP, Cert. IVUSS

IMAGING PERFORMED BY

Griffin

HOSPITAL NAME

Northside VC

REFERRING VET

Griffin

INVOICE

21006

DATE

2/4/23

Pancreas

The base and limbs of the **pancreas** were observed to be largely isoechoic to surrounding omental fat. Pancreatic duct and capsular contour were acceptably normal and parenchyma respected normal curvilinear patterns. No overt evidence of active inflammatory or neoplastic disease was noted.

ULTRASONOGRAPHIC FINDINGS

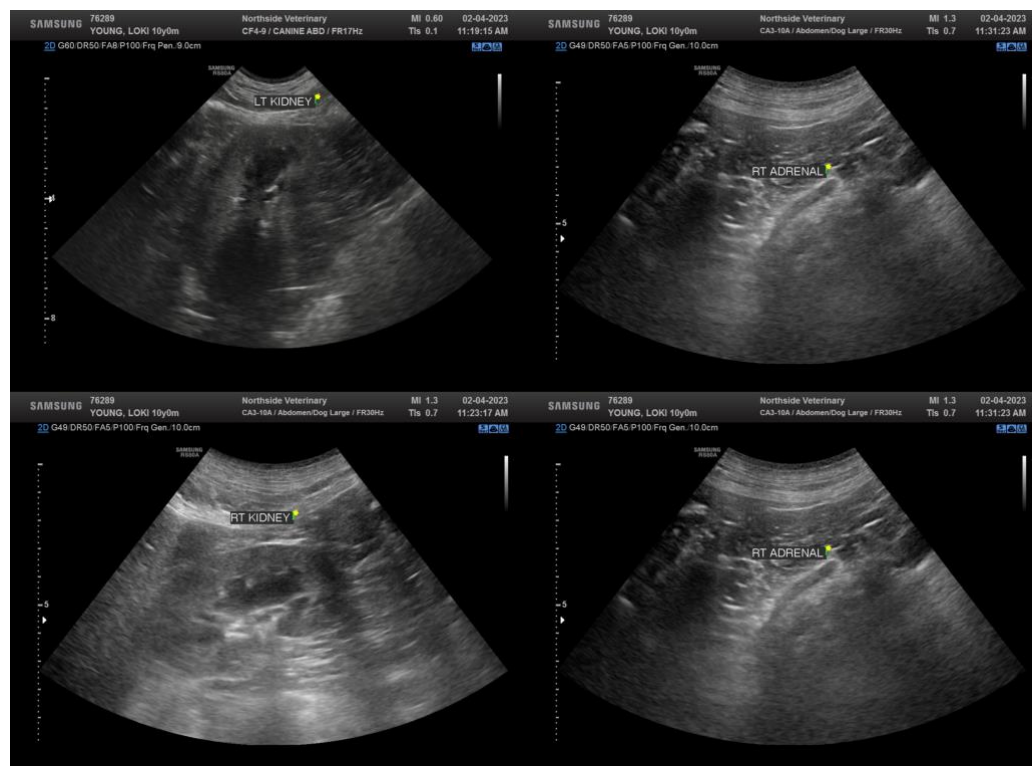
- Slight irregular gastric wall, possible small ulcer/gastritis
- Flattened adrenal glands
- Age-related renal and hepatic changes

INTERPRETATION OF THE FINDINGS & FURTHER RECOMMENDATIONS

Screening for Addisons is warranted. GI protectant protocol is indicated. No evidence of foreign body or obvious neoplasia. A clinical trial of the following may prove effective.

Helicobacter/Gastritis protocol

A clinical trial of **Zithromax (Dogs: 5-10 mg/kg p.o. q24h. May increase dosing interval to q48h after 3-5 days of treatment), Metronidazole (10-20 mg/kg p.o. b.i.d.), Pepcid (0.5-1 mg/kg s.i.d.) and Sucralfate (0.5-2 g/dog PO) or Omeprazole (1 mg/kg p.o. s.i.d.)** over the next 3 weeks along with a **novel-protein or hydrolyzed diet** with slurry feeding b.i.d./t.i.d. over the next 2-4 days and then increase to canned diet bid. Dry food should be avoided over the next 4 weeks. A recheck sonogram to assess GI improvement or progression would be ideal in 4 weeks.





PATIENT

Loki Young

SPECIES

Canine

BREED

Golden Retriever

SEX

Neutered Male

AGE

10 Years

WEIGHT

100

INTERPRETED BY

Eric Lindquist, DMV
DABVP, Cert. IVUSS

IMAGING PERFORMED BY

Griffin

HOSPITAL NAME

Northside VC

REFERRING VET

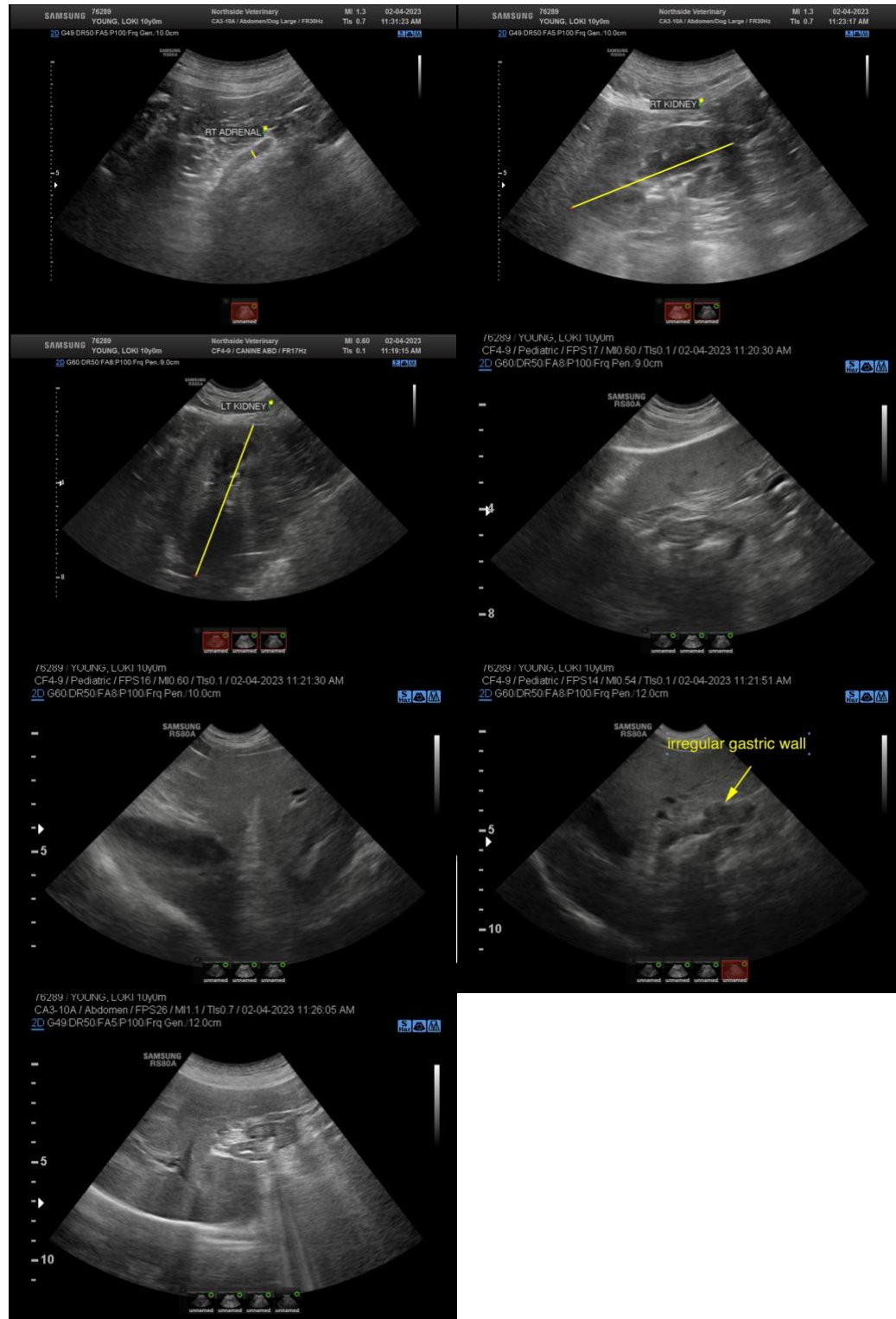
Griffin

INVOICE

21006

DATE

2/4/23



The information and recommendations provided are based on the images presented by the referring veterinarian. No evaluation can be communicated regarding pathology that was not visible in the image/video clips provided.



PATIENT

Loki Young

Thank you for this referral. If the clinical or image interpretation does not parallel your findings or if I can be of any further assistance please contact me.

SPECIES

Canine

Eric Lindquist, DMV, DABVP, Cert. IVUSS, CEO of SonoPath.com
info@SonoPath.com

BREED

Golden Retriever

SEX

Neutered Male

AGE

10 Years

WEIGHT

100

INTERPRETED BY

Eric Lindquist, DMV
DABVP, Cert. IVUSS

**IMAGING
PERFORMED BY**

Griffin

HOSPITAL NAME

Northside VC

REFERRING VET

Griffin

INVOICE

21006

DATE

2/4/23