



PATIENT

Bella Mueller

SPECIES

Canine

BREED

Mix

SEX

Spayed Female

AGE

8

WEIGHT

95

INTERPRETED BY

Eric Lindquist, DMV
DABVP, Cert. IVUSS

IMAGING PERFORMED BY

Jenn

HOSPITAL NAME

Rockaway AH

REFERRING VET

Dr. Ascot

INVOICE

21000

DATE

2/4/23

PRESENTING CLINICAL SIGNS

History: Suspect cholangiohepatitis lethargic restless, nauseous, and hyporexic Current meds NaCl Unasyn

Abnormal PE/Chem/CBC/UA Results: normal CBC ALT 689 ALP 920 Tbili 1.3 Cpl normal

ULTRASONOGRAPHIC EXAMINATION OF THE ABDOMEN

Urinary System

The **urinary bladder**, trigone, and pelvic urethra presented normal thicknesses and normal tone. The ureters were not visible which is normal. No uroliths or sediment were visualized and anechoic urine was present. No evidence of inflammatory or neoplastic changes were noted. Ureteral papillae were normal. The pelvic urethra was imaged 2.0 cm beyond the cystourethral junction.

The **kidneys** revealed largely normal size and structure, corticomedullary definition and ratio (cortex 1/3 of medulla) were essentially maintained with some minor age-related loss of curvilinear patterns regarding the capsule and C/M junction. The cortices presented largely uniform texture with some increased echogenicity expected for his age patient. Medullary structure differed distinctly from that of the cortex and no evidence of pelvic dilation was present. The right kidney measured 7.3 cm. The left kidney measured 7.1 cm.

Adrenal Glands

The **left adrenal gland** was visualized and recognized as having normal shape, size, position and echogenicity for this breed. The phrenic vasculature, glandular echogenicity and detail were unremarkable. Capsule, cortex, and medullary definition were normal for this age patient. The left adrenal gland measured 0.3 cm.

The region of the **right adrenal gland** was imaged and revealed no evident pathology.

Spleen

The **spleen** revealed slight scalloping contour and minor heterogenous parenchymal changes.

Liver

The **liver** revealed increased portal markings. The gallbladder wall was slightly echogenic. Mild irregular swelling was noted.

Gastrointestinal

Examination of the **gastrointestinal tract** revealed a stomach and intestine free of stasis, of normal wall thickness, acceptable curvilinear mural detail, and peristaltic activity. Small and large intestine demonstrated normal luminal chyme and stool consistency respectively. No obstructive or overt infiltrative disease was noted. No associated abnormal lymphatic activity was noted.

Pancreas

The base and limbs of the **pancreas** were observed to be largely isoechoic to surrounding omental fat. Pancreatic duct and capsular contour were acceptably normal and parenchyma respected normal curvilinear patterns. No overt evidence of active inflammatory or neoplastic disease was noted.



PATIENT

Bella Mueller

ULTRASONOGRAPHIC FINDINGS

- Cholangitis liver pattern with mild hepatosplenic swelling
- Age-related renal changes

SPECIES

Canine

INTERPRETATION OF THE FINDINGS & FURTHER RECOMMENDATIONS

FNA is warranted to rule out underlying neoplasia. FNA of the spleen and core liver biopsy could also be considered for further definition. Leptospirosis titers is warranted. Prognosis is guarded. Cholangiohepatitis vs emerging lymphoma are primary differentials.

BREED

Mix

SEX

Spayed Female

AGE

8

WEIGHT

95

INTERPRETED BY

Eric Lindquist, DMV
DABVP, Cert. IVUSS

IMAGING PERFORMED BY

Jenn

HOSPITAL NAME

Rockaway AH

REFERRING VET

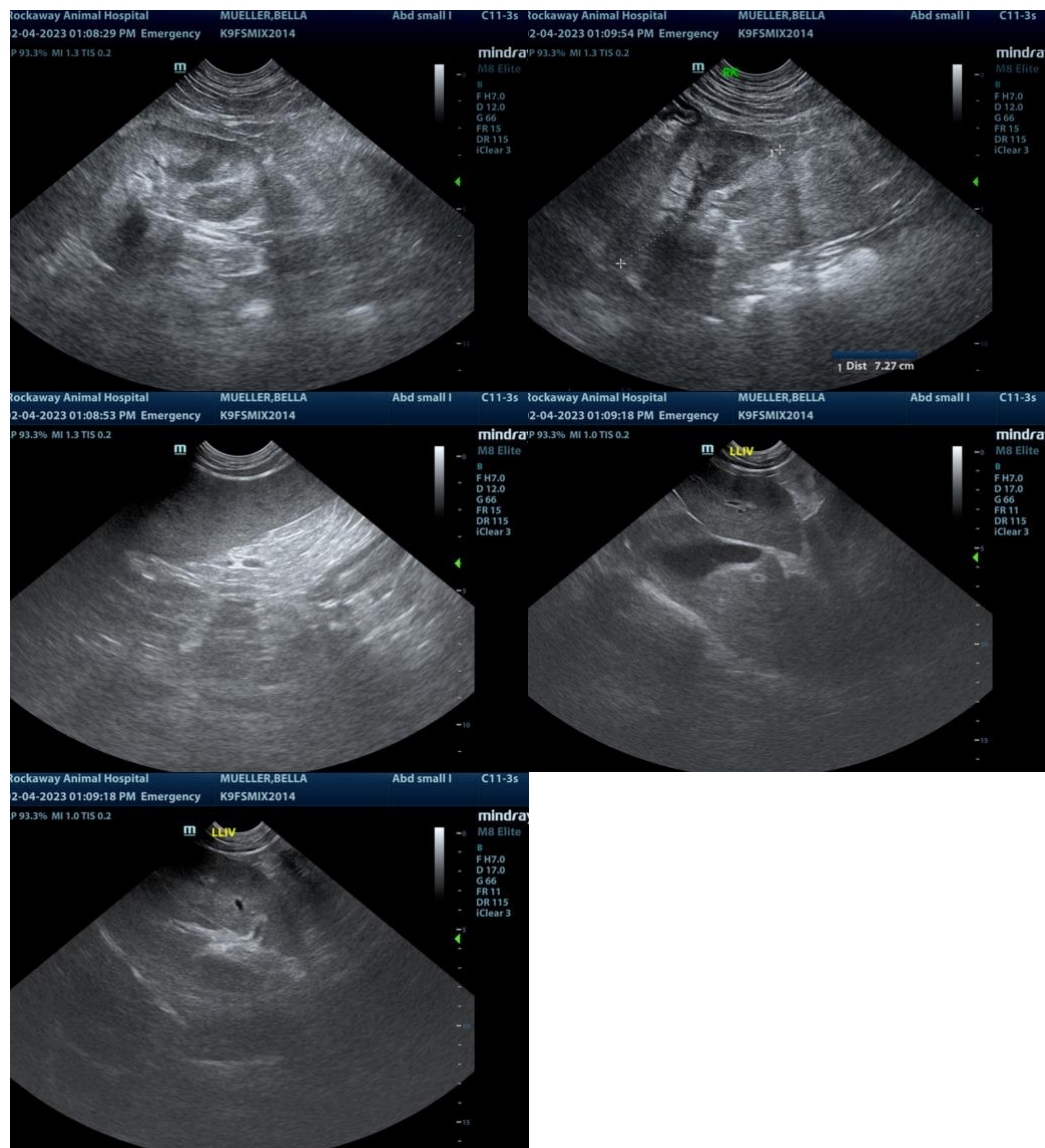
Dr. Ascot

INVOICE

21000

DATE

2/4/23



The information and recommendations provided are based on the images presented by the referring veterinarian. No evaluation can be communicated regarding pathology that was not visible in the image/video clips provided.

Thank you for this referral. If the clinical or image interpretation does not parallel your findings or if I



PATIENT

can be of any further assistance please contact me.

Bella Mueller

SPECIES

Eric Lindquist, DMV, DABVP, Cert. IVUSS, CEO of SonoPath.com
info@SonoPath.com

Canine

BREED

Mix

SEX

Spayed Female

AGE

8

WEIGHT

95

INTERPRETED BY

Eric Lindquist, DMV
DABVP, Cert. IVUSS

**IMAGING
PERFORMED BY**

Jenn

HOSPITAL NAME

Rockaway AH

REFERRING VET

Dr. Ascot

INVOICE

21000

DATE

2/4/23