

PATIENT PRESENTING CLINICAL SIGNS

Zoey Kim Ongoing heart murmur. This is a 6 month recheck Echo. No clinical signs. Owner decreased medications and Zoey is doing very well clinically Heart Rate and Respiratory Rates 180/50 Current Medications Furosemide 1/3 of 12.5mg PO q24, Enalapril 1.25mg PO q24h, Vetmedin 1.25mg PO q12h

SPECIES

Canine

ULTRASONOGRAPHIC EXAMINATION OF THE HEART

BREED

Rat Terrier

SEX

Spayed Female

AGE

13.5 Years

WEIGHT

10.1 Pounds

INTERPRETED BY

Eric Lindquist, DMV

DABVP, Cert. IVUSS

IMAGING PERFORMED BY

Jenna Walsh, CVT

HOSPITAL NAME

Edgewood AC

REFERRING VET

Dr. Kimball

INVOICE

35479

DATE

2/4/22

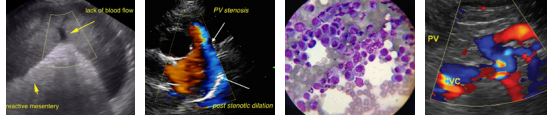
CANINE CARDIAC PARAMETERS	MR VMAX (m/s)	TR VMAX (m/s)	LA/AO (Boon method)	LA/AO (Heart Base; Swe)	FS (%)	EF (%)	EPSS (cm)
NORMAL PARAMETER	4.5-5.5	<2.7	1.3	<1.6	28-40	40-100	<0.6
PATIENT	5.0	2.5	1.5	1.8	40		0.2
CANINE CARDIAC PARAMETERS	HR (BPM)	AV VMAX (m/s)	PV MAX (m/s)	BODY WEIGHT (kg)	LA 2D short axis Base view (cm)	LVIDd Avg; 2D and m-mode short axis (cm)	LVIDs Avg; 2D and m-mode short axis (cm)
NORMAL PARAMETER	50-100	0.7-1.7	0.7-1.6				
PATIENT		1.3			4.8	4.0	

Cardiac Presentation

The **left atrium** presented chronic dilation. Chamber volumes and echogenicity were normal. The cranial and caudal **mitral** valve leaflets presented vegetative thickening consistent with endocardiosis. Doppler indicated measurable insufficiency. Prolapse of the anterior mitral valve leaflet noted. The **left ventricle** presented thicknesses with linear contour and was not dilated nor restricted. The **myocardium** presented normal echogenicity without subjective evidence of significant fibrotic or ischemic disease. **Contractility** of the ventricular walls was adequate and in normal range for this patient evidenced by the fractional shortening measurement and subjective evaluation of the different regions of the myocardium. The **left ventricular outflow** tract demonstrated normal laminar flow and subjective structural integrity. The **right atrium** and auricle revealed normal size, structure and content. No evidence of masses was noted or chamber overload. **Tricuspid** valvular assessment demonstrated adequate linear morphology. The **right ventricle** was of normal size (1/3 diameter of LV), chordae structure, myocardial echogenicity and thickness. **Pulmonic** tract assessment revealed normal valve structure, laminar flow, and diameter (approx. 1:1 pa/ao ratio). No visible **pericardial** or free pleura fluid was noted. No echographically detectable evidence of infiltrative disease was visible. The cranial **mediastinum and pericardial regions** were free of masses in the visible window.

ULTRASONOGRAPHIC FINDINGS

- Partially compensated Stage C1 valvular disease



PATIENT

Zoey Kim

SPECIES

Canine

BREED

Rat Terrier

SEX

Spayed Female

AGE

13.5 Years

WEIGHT

10.1 Pounds

INTERPRETED BY

Eric Lindquist, DMV
DABVP, Cert. IVUSS

IMAGING PERFORMED BY

Jenna Walsh, CVT

HOSPITAL NAME

Edgewood AC

REFERRING VET

Dr. Kimball

INVOICE

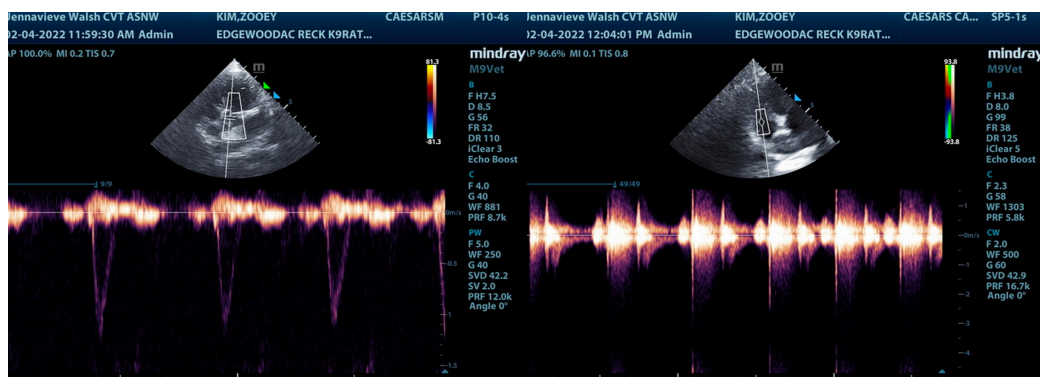
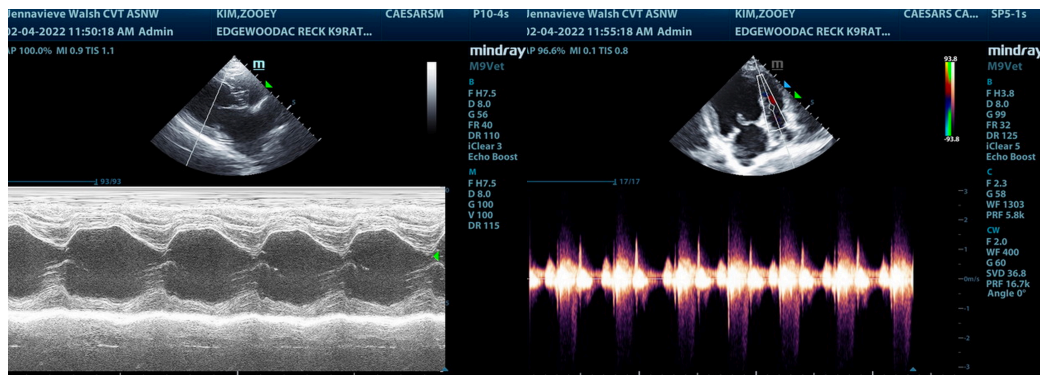
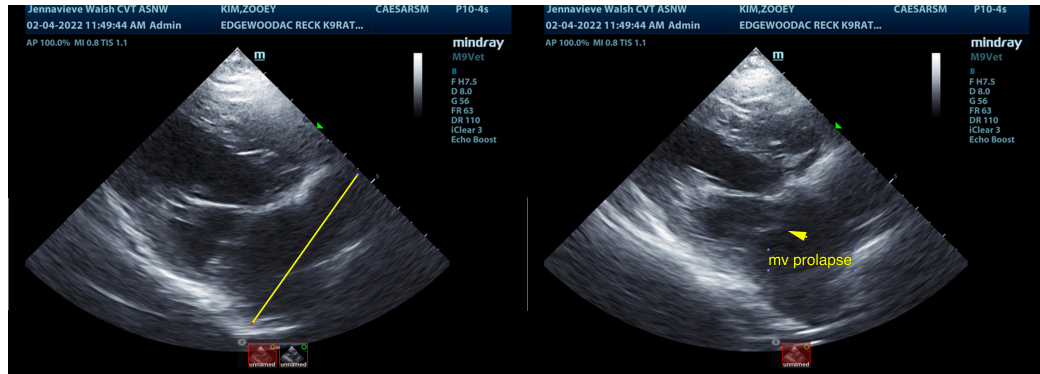
35479

DATE

2/4/22

INTERPRETATION OF THE FINDINGS & FURTHER RECOMMENDATIONS

In addition to the current protocol, I recommend adding Spironolactone at 1-2 mg/kg BID and increasing Enalapril to 0.5 mg/kg BID. Recheck 3-6 months, earlier if clinical signs initiate.





PATIENT

Zooley Kim

SPECIES

Canine

BREED

Rat Terrier

SEX

Spayed Female

AGE

13.5 Years

WEIGHT

10.1 Pounds

INTERPRETED BY

Eric Lindquist, DMV
DABVP, Cert. IVUSS

IMAGING PERFORMED BY

Jenna Walsh, CVT

HOSPITAL NAME

Edgewood AC

REFERRING VET

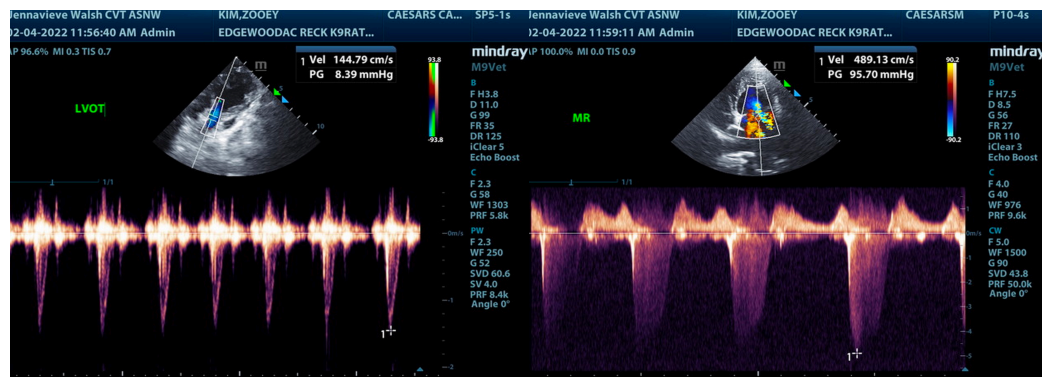
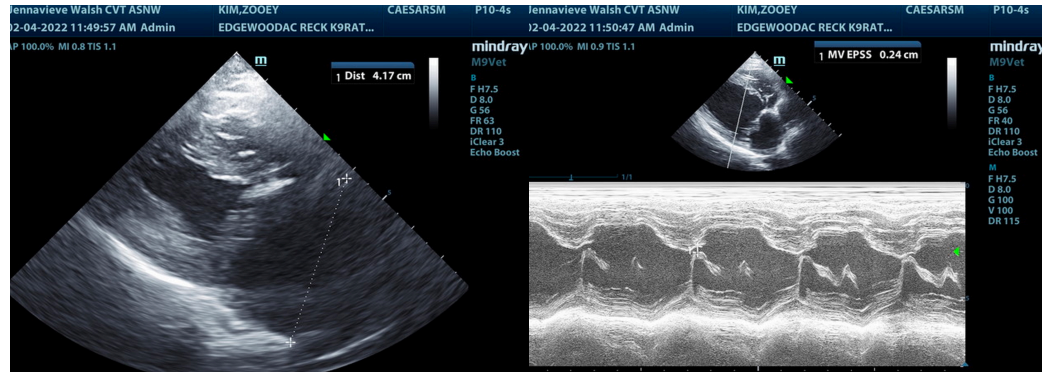
Dr. Kimball

INVOICE

35479

DATE

2/4/22



The information and recommendations provided are based on the images presented by the referring veterinarian/sonographer. No evaluation can be communicated regarding pathology that was not visible in the image/video clips provided.

Thank you for this referral. If the clinical or image interpretation does not parallel your findings or if I can be of any further assistance please contact me.

Eric Lindquist, DMV, DABVP, Cert. IVUSS, CEO of SonoPath.com

info@SonoPath.com