



PATIENT

Scamper Damiano

SPECIES

Canine

BREED

Terrier Mix

SEX

Neutered Male

AGE

6 Years

WEIGHT

15 Lbs.

PRESENTING CLINICAL SIGNS

History: Intermittent heavy breathing/gagging, usually occurs with cold weather.

ULTRASONOGRAPHIC EXAMINATION OF THE HEART

CANINE CARDIAC PARAMETERS	MR VMAX (m/s)	TR VMAX (m/s)	LA/AO (Boon method)	LA/AO (Heart Base; Swe)	FS (%)	EF (%)	EPSS (cm)
NORMAL PARAMETER	4.5-5.5	<2.7	1.3	<1.6	28-40	40-100	<0.6
PATIENT	5.60		>2.0	>2.5	35		NM
CANINE CARDIAC PARAMETERS	HR (BPM)	AV VMAX (m/s)	PV MAX (m/s)	BODY WEIGHT (kg)	LA 2D short axis Base view (cm)	LVIDd Avg; 2D and m-mode short axis (cm)	LVIDs Avg; 2D and m-mode short axis (cm)
NORMAL PARAMETER	50-100	0.7-1.7	0.7-1.6	BELOW	BELOW	BELOW	BELOW
PATIENT	160				5.5	3.8	

Cardiac Presentation

The cardiac presentation in this patient revealed a moderate to severe volume overload of the left atrium and left ventricle with severe mitral insufficiency. A rapid echocardiogram was performed, owing to the respiratory stress of the patient. B-lines noted in the peripheral lung fields. Tachycardia was present.

ULTRASONOGRAPHIC FINDINGS

- C-1 valvular disease

INTERPRETATION OF THE FINDINGS & FURTHER RECOMMENDATIONS

I recommended quadra therapy in this patient, pimobendan at 0.3 mg/kg BID, ace-inhibitor 0.5 mg/kg SID, progressing to BID, spironolactone at 1-2 mg/kg BID and Lasix at 2-3 mg/kg BID.

The heart is in a somewhat precarious state with volume overload and a heart that is working to compensate for the valvular insufficiency. Target respiratory rate is < 20 resp/minute after therapy. After initiating therapy, I recommend recheck on the clinical exam, BUN, Creatinine, USG, Chest radiographs & Blood pressure in 5-7 days. Recheck echo in 1 month. Earlier if clinical decompensation is occurring. I do not recommend anesthesia at this time until stabilization has occurred on the recommended medications. Repeat preanesthetic echo is ideal if anesthesia is eventually necessary.

INTERPRETED BY

Eric Lindquist, DMV
DABVP, Cert. IVUSS

IMAGING PERFORMED BY

Eric Lindquist, DMV
DABVP, Cert. IVUSS

HOSPITAL NAME

Whippany VH

REFERRING VET

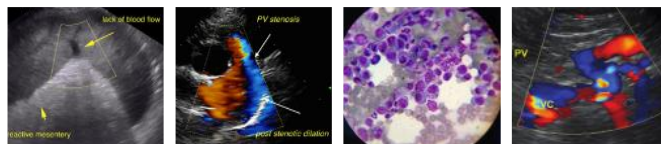
Dr. Cordero

INVOICE

13765

DATE

2/4/22



PATIENT

Scamper Damiano

SPECIES

Canine

BREED

Terrier Mix

SEX

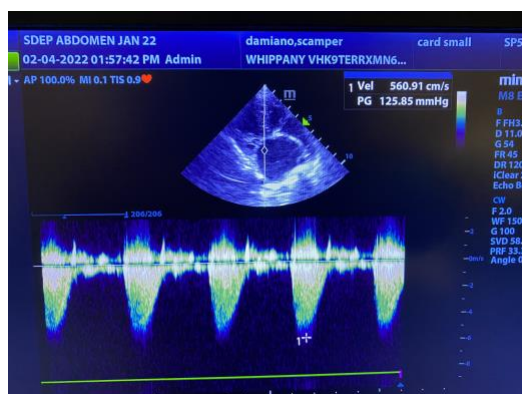
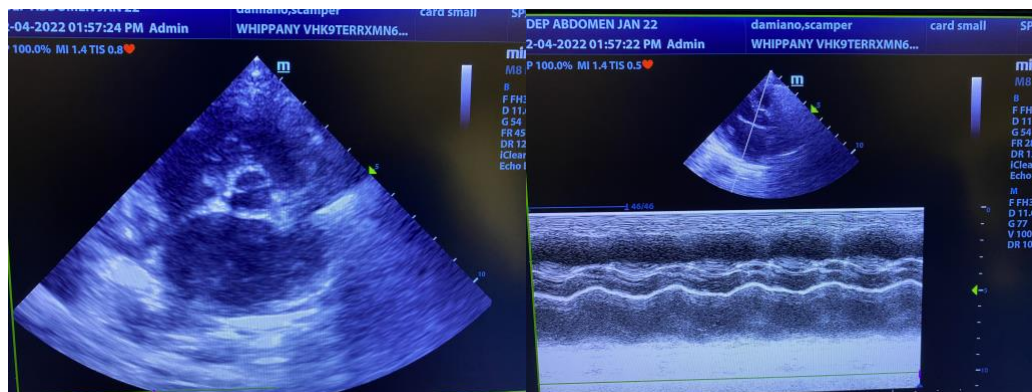
Neutered Male

AGE

6 Years

WEIGHT

15 Lbs.



The information and recommendations provided are based on the images presented by the referring veterinarian. No evaluation can be communicated regarding pathology that was not visible in the image/video clips provided.

Thank you for this referral. If the clinical or image interpretation does not parallel your findings or if I can be of any further assistance please contact me.

INTERPRETED BY

Eric Lindquist, DMV
DABVP, Cert. IVUSS

IMAGING PERFORMED BY

Eric Lindquist, DMV
DABVP, Cert. IVUSS

HOSPITAL NAME

Whippany VH

REFERRING VET

Dr. Cordero

INVOICE

13765

DATE

2/4/22

Eric Lindquist, DMV, DABVP, Cert. IVUSS, CEO of SonoPath.com
info@SonoPath.com