SonoPath
Clinical Sonography & Telecytology

EDUCATIONAL TELECONSULTATION SERVICES™

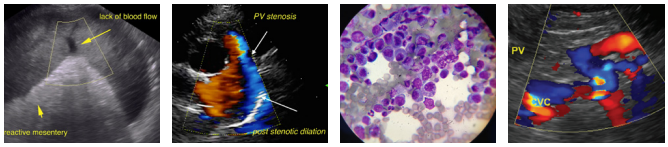

SonoPath.com™
1-800-838-4268 info@sonopath.com

PATIENT
Riley Griffin

SPECIES
Canine

BREED
Yorkshire Terrier X

SEX
Spayed Female

AGE
4 Years

WEIGHT
18 Pounds

INTERPRETED BY
Eric Lindquist, DMV
DABVP, Cert. IVUSS

IMAGING PERFORMED BY
Dr. Ray Caughman

HOSPITAL NAME
Dogwood AH

REFERRING VET
Dr. Ray Caughman

INVOICE
35484

DATE
2/4/22

PRESENTING CLINICAL SIGNS

Lethargy one week. Vomiting 24 hour duration. Got new dog treats recently
Abnormal PE/Chem/CBC/UA Results: WBC 21K with bands, Chloride low 104, Amylase >2500, Lipase 5925, ALP 405 Abdomen tense, mm dry CRT 2.0 sec, Painful on abdominal palpation

ULTRASONOGRAPHIC EXAMINATION OF THE ABDOMEN

Urinary System

The **urinary bladder**, trigone, and pelvic urethra presented normal thicknesses and normal tone. The ureters were not visible which is normal. No uroliths or sediment were visualized and anechoic urine was present. No evidence of inflammatory or neoplastic changes were noted. Ureteral papillae were normal. The pelvic urethra was imaged 2.0 cm beyond the cystourethral junction.

The **kidneys** revealed normal size and structure, corticomedullary definition and ratio for this age. The cortices presented largely uniform texture with normal echogenic relationship to liver and spleen. Medullary structure differed distinctly from the cortex and no evidence of pelvic dilation was present. The capsules were acceptably uniform without significant irregularities. The right kidney measured 6.04 cm. The left kidney measured 4.99 cm.

Adrenal Glands

Both **adrenal glands** were visualized and recognized as having normal shape, size, position and echogenicity for this breed. The phrenic vasculature, glandular echogenicity and detail were unremarkable. Capsule, cortex, and medullary definition were normal for this age patient. The left adrenal gland measured 0.37 cm. The right adrenal gland measured 0.42 cm.

Spleen

The **spleen** presented a smooth homogeneous parenchyma hyperechoic to liver and renal cortical parenchyma. The capsule was smooth without noticeable expansion or deviation from within the spleen or adjacent pathology. The splenic vasculature demonstrated normal volume without signs of congestion or thrombosis. No sonographic evidence of acute or chronic inflammatory, neoplastic, or infarctual changes were noted.

Liver

Exam of the cranial abdomen demonstrated excessive **liver** size, swollen contour, with conserved uniform architecture. Parenchymal echogenicity was diffusely isoechoic to the spleen and falciform fat. Minor excessive GB debris was noted with the presence gall bladder dilation and precipitate without the overt formation of mucocele but this may be an issue in the future. This type of liver presentation typically is associated with slow and gradual SAP elevations with low-grade ALT rise. USG-FNA sampling is encouraged if more aggressive LE profiles are present such as ALT > 200 or rapid rise in SAP. These presentations are usually reactive hepatopathies owing to other disease processes either endocrine (Diabetes, Hypothyroidism, Cushing's disease), "antigen surveillance" from the gut/pancreas, or idiopathic breed predisposed progressions.

Gastrointestinal

The **stomach** revealed minor luminal fluid accumulation. Deviation of the gastric axis caudally noted, owing to hepatomegaly. Gastrointestinal wall was unremarkable. No evidence of foreign bodies. The distal small intestine was unremarkable.

SonoPath
Clinical Sonography & Telecytology

EDUCATIONAL TELECONSULTATION SERVICES™

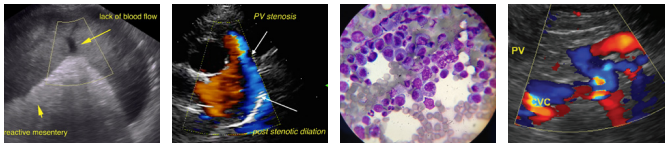

SonoPath.com™
1-800-838-4268 info@sonopath.com

PATIENT

Riley Griffin

SPECIES

Canine

BREED

Yorkshire Terrier X

SEX

Spayed Female

AGE

4 Years

WEIGHT

18 Pounds

INTERPRETED BY

Eric Lindquist, DMV

DABVP, Cert. IVUSS

IMAGING PERFORMED BY

Dr. Ray Caughman

HOSPITAL NAME

Dogwood AH

REFERRING VET

Dr. Ray Caughman

INVOICE

35484

DATE

2/4/22

Pancreas

Mild heterogeneous **pancreatic** changes noted at the pancreatic base with ill-defined enhanced surrounding mesentery, consistent with pancreatitis. This is more dramatic in the right limb.

ULTRASONOGRAPHIC FINDINGS

- Gastroenteritis/pancreatitis pattern

INTERPRETATION OF THE FINDINGS & FURTHER RECOMMENDATIONS

IV fluid support, broad-spectrum antibiotics and pain management warranted. Recheck sonogram in 48-72 hours. GI protectants also indicated.

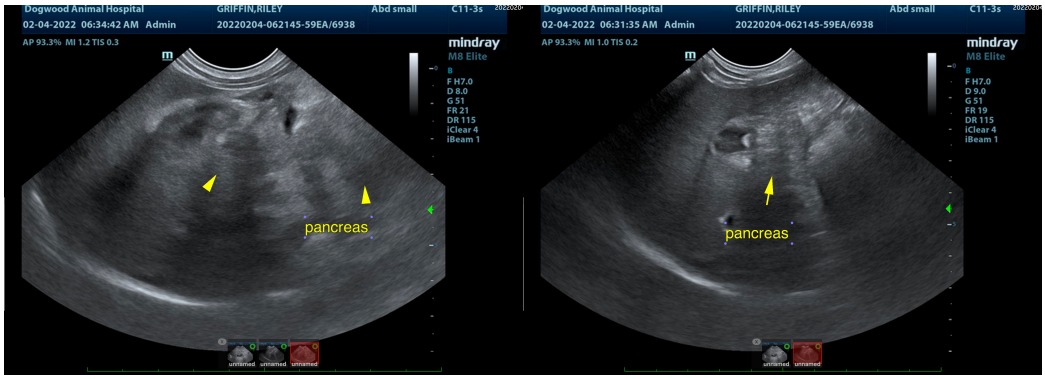

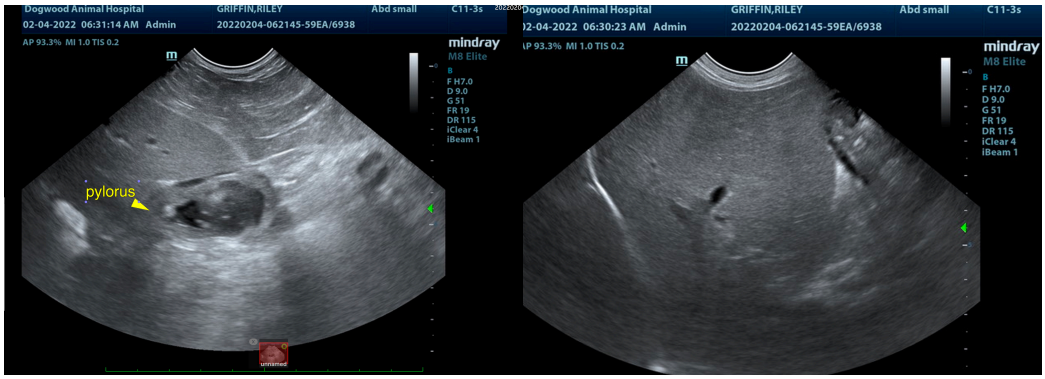

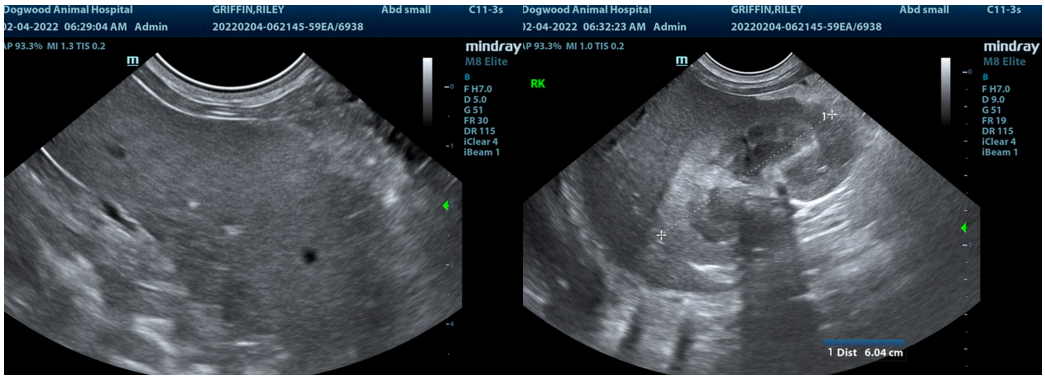

SonoPath
Clinical Sonography & Telecytology

EDUCATIONAL TELECONSULTATION SERVICES™

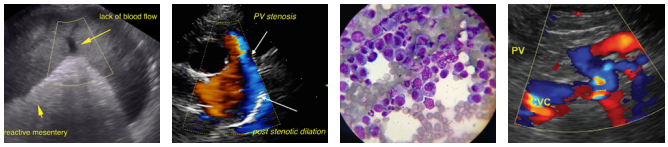

SonoPath.com™
1-800-838-4268 info@sonopath.com

PATIENT

Riley Griffin

SPECIES

Canine

BREED

Yorkshire Terrier X

SEX

Spayed Female

AGE

4 Years

WEIGHT

18 Pounds

INTERPRETED BY

Eric Lindquist, DMV

DABVP, Cert. IVUSS

IMAGING PERFORMED BY

Dr. Ray Caughman

HOSPITAL NAME

Dogwood AH

REFERRING VET

Dr. Ray Caughman

INVOICE

35484

DATE

2/4/22

The information and recommendations provided are based on the images presented by the referring veterinarian/sonographer. No evaluation can be communicated regarding pathology that was not visible in the image/video clips provided.

Thank you for this referral. If the clinical or image interpretation does not parallel your findings or if I can be of any further assistance please contact me.

Eric Lindquist, DMV, DABVP, Cert. IVUSS, CEO of SonoPath.com

info@SonoPath.com