

**DATE PRESENTING CLINICAL SIGNS**

2/4/22 History: History of elevated liver enzymes and GI symptoms.
On Keppra recently for seizures.

PATIENT

Missy Keller Current Medications: Amox Clav 62.5mg (#20)- 1 tab PO q 12 hours, Amox Clav 125mg (#20)- 1 tab PO q 12 hours, Cerenia 16mg- 1 tab PO every 24 hours (three day's worth), Famotidine 10mg (#10)- 1 tab PO q 12 hours, Keppra 250 mg PO q 8 h.

SPECIES

Canine Lab Results: CBC:
RETIC 151.7 High (10.0-110.0)
RETIC- HGB 20.7 Low (22.3-29.6)
Bands suspected

BREED

Chihuahua X Mono 1.52 High (0.16-1.12)
PLT 0 Low (148-484); confirmed with blood smear- adequate platelets
MPV 18.5 High (8.7-13.2)

SEX

Spayed Female - CHEM:
Glu 146 High (74-143)
GLOB 4.7 High (2.5-4.5)
ALT 3595 (dilution of 1:3)
ALKP 1931 High (23-212)
GGT 26 High (0-11)

AGE

2/14/15 TBILI 4.7 High (0.0-0.9).
Date of Previous IntraPet Ultrasound: No previous IntraPet scans.

WEIGHT

23.7 Pounds

Sedation: Not required to complete full diagnostic ultrasound.
Stat Report: Not requested.

INTERPRETED BY

Eric Lindquist, DMV
DABVP, Cert. IVUSS

ULTRASONOGRAPHIC EXAMINATION OF THE ABDOMEN**Urinary System**

The **urinary bladder**, trigone, and pelvic urethra presented normal thicknesses and normal tone. The ureters were not visible which is normal. No uroliths or sediment were visualized and anechoic urine was present. No evidence of inflammatory or neoplastic changes were noted. Ureteral papillae were normal. Hyperechoic fat/omentum noted cranial to the urinary bladder.

IMAGING PERFORMED BY

Rachel Brilhart RDMS

HOSPITAL NAME

Swan Creek VC

The **kidneys** revealed normal size and structure, corticomedullary definition and ratio for this age. The cortices presented largely uniform texture with normal echogenic relationship to liver and spleen. Medullary structure differed distinctly from the cortex and no evidence of pelvic dilation was present. The capsules were acceptably uniform without significant irregularities. The left kidney measured 4.48 cm. The right kidney measured 4.88 cm.

REFERRING VET

Dr. Receski

Adrenal Glands

Both **adrenal glands** were visualized and recognized as having normal shape, size, position and echogenicity for this breed. The phrenic vasculature, glandular echogenicity and detail were unremarkable. Capsule, cortex, and medullary definition were normal for this age patient. The left adrenal gland measured 2.1 cm x 0.40 cm at the cranial pole and 0.65 cm at the caudal pole. The right adrenal gland measured 2.12 cm x 0.8 cm at the cranial pole and 0.55 cm at the caudal pole.

INVOICE

35495

Spleen

The **spleen** presented a smooth homogeneous parenchyma hyperechoic to liver and renal cortical parenchyma. The capsule was smooth without noticeable expansion or deviation from within the spleen or adjacent pathology. The splenic vasculature demonstrated normal volume without signs of congestion or thrombosis. No sonographic evidence of acute or chronic inflammatory, neoplastic, or infarctual changes were noted.

Liver

The **liver** was structurally unremarkable with slight coarse architecture. The gallbladder and common bile duct were unremarkable.

Gastrointestinal

The **stomach** was mildly thickened with hypertrophied muscularis and empty lumen. No loss of mural detail. The small intestine and colon were unremarkable.

Pancreas

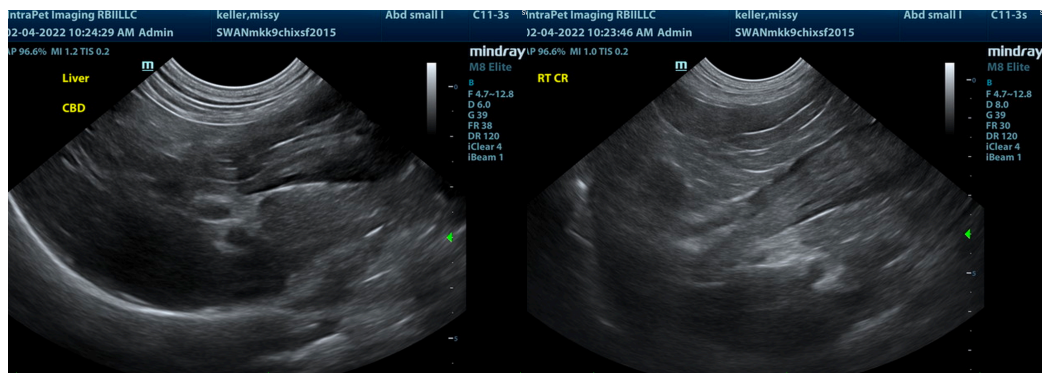
The **pancreas** revealed minor hyperechoic changes, consistent with remodeling.

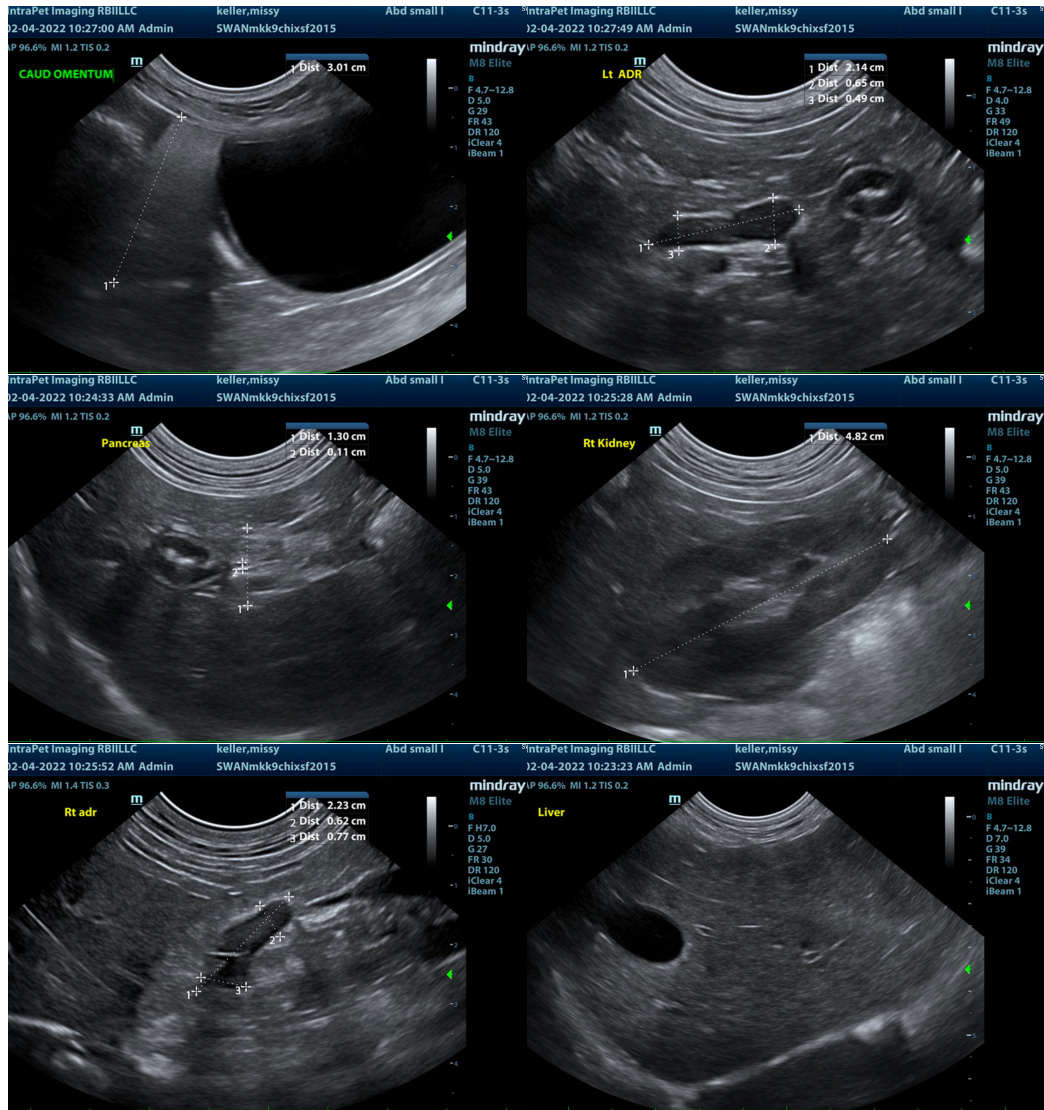
ULTRASONOGRAPHIC FINDINGS

- Minor hepatic remodeling
- Minor pancreatic remodeling
- Minor gastric hypertrophy
- Undefined omental remodeling in the caudal abdomen

INTERPRETATION OF THE FINDINGS & FURTHER RECOMMENDATIONS

Possible history of steatitis. Palpation of the caudal abdomen warranted to assess for any discomfort. Leptospirosis titers warranted. FNA of the liver warranted to assess inflammatory cell type. Ampicillin/Metronidazole or similar combination recommended with hepatic nutraceuticals. GI protectant protocol also indicated. If liver enzymes remain elevated, core biopsy may be necessary to differentiate copper accumulation.





The information and recommendations provided are based on the images presented by the referring veterinarian. No evaluation can be communicated regarding pathology that was not visible in the image/video clips provided.

Thank you for this referral. If the clinical or image interpretation does not parallel your findings or if I can be of any further assistance please contact me.

Eric Lindquist, DMV, DABVP, Cert. IVUSS, CEO of SonoPath.com
info@SonoPath.com