



PATIENT PRESENTING CLINICAL SIGNS

Maisy Spring Grade 2/3 murmur.

SPECIES ULTRASONOGRAPHIC EXAMINATION OF THE HEART

Canine

BREED

Yorkie

SEX

Spayed Female

AGE

10 Years

WEIGHT

1.25 kg

CANINE CARDIAC PARAMETERS	MR VMAX (m/s)	TR VMAX (m/s)	LA/AO (Boon method)	LA/AO (Heart Base; Swe)	FS (%)	EF (%)	EPSS (cm)
NORMAL PARAMETER	4.5-5.5	<2.7	1.3	<1.6	28-40	40-100	<0.6
PATIENT			1.1	1.2			NM
CANINE CARDIAC PARAMETERS	HR (BPM)	AV VMAX (m/s)	PV MAX (m/s)	BODY WEIGHT (kg)	LA 2D short axis Base view (cm)	LVIDd Avg; 2D and m-mode short axis (cm)	LVIDs Avg; 2D and m-mode short axis (cm)
NORMAL PARAMETER	50-100	0.7-1.7	0.7-1.6				
PATIENT					1.6		

Cardiac Presentation

The echocardiogram in this patient demonstrated normal **left atrial** size based on 3 different LA measurement methods. Chamber volumes and echogenicity were normal. The cranial and caudal **mitral** valve leaflets presented vegetative thickening consistent with endocardiosis. Doppler indicated measurable insufficiency. The **left ventricle** presented thicknesses with linear contour and was not dilated nor restricted. The **myocardium** presented normal echogenicity without subjective evidence of significant fibrotic or ischemic disease. **Contractility** of the ventricular walls was adequate and in normal range for this patient evidenced by the fractional shortening measurement and subjective evaluation of the different regions of the myocardium. The **aortic valve** was thickened in this patient with aortic insufficiency noted, not clinically significant. The **right atrium** and auricle revealed normal size, structure and content. No evidence of masses was noted or chamber overload. **Tricuspid** valvular assessment demonstrated adequate linear morphology. The **right ventricle** was of normal size (1/3 diameter of LV), chordae structure, myocardial echogenicity and thickness. **Pulmonic** tract assessment revealed normal valve structure, laminar flow, and diameter (approx.1:1 pa/ao ratio). No visible **pericardial** or free pleura fluid was noted. No echographically detectable evidence of infiltrative disease was visible. The cranial **mediastinum** and **pericardial** regions were free of masses in the visible window. Occasional arrhythmia noted.

ULTRASONOGRAPHIC FINDINGS

- Stage B1 valvular disease with mitral and aortic insufficiency
- Occasional arrhythmia

INTERPRETATION OF THE FINDINGS & FURTHER RECOMMENDATIONS

EKG indicated as well as blood pressures. Valvular disease is compensated at this time.

INTERPRETED BY

Eric Lindquist, DMV

DABVP, Cert. IVUSS

IMAGING PERFORMED BY

Dave Stasiuk

HOSPITAL NAME

Resolution Vet
Ultrasound

REFERRING VET

Dr. Sasa Karagic

INVOICE

35459

DATE

2/4/22



PATIENT

Maisy Spring

SPECIES

Canine

BREED

Yorkie

SEX

Spayed Female

AGE

10 Years

WEIGHT

1.25 kg

INTERPRETED BY

Eric Lindquist, DMV

DABVP, Cert. IVUSS

IMAGING PERFORMED BY

Dave Stasiuk

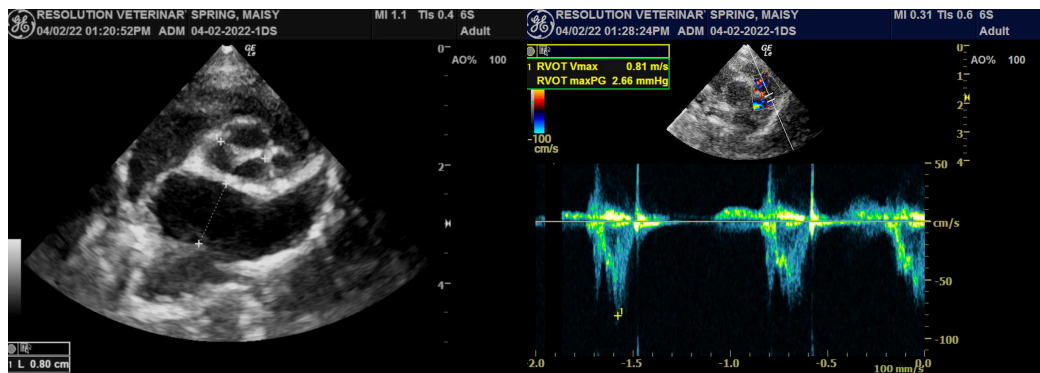
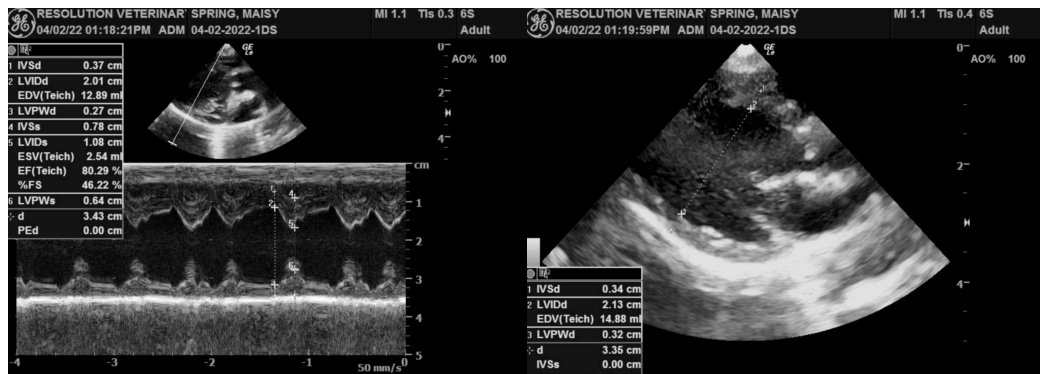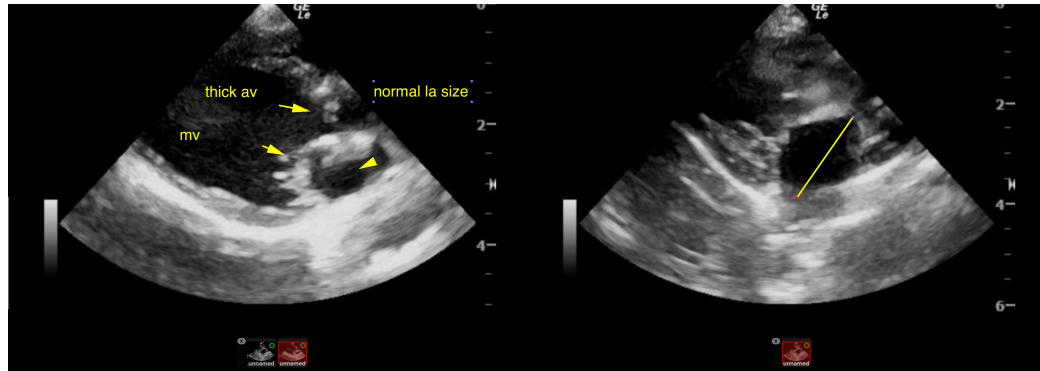
HOSPITAL NAME

Resolution Vet
Ultrasound

REFERRING VET

Dr. Sasa Karagic

B1: The heart is stable without clinical disease. No overt contraindication for anesthesia of brief to moderate duration. I suggest Torbutrol premed, Propofol induction, Isoflor maintenance or similar protocol if anesthesia is desired. Blood pressure recommended if not already performed and target white coat negative systolic pressure of < 160 mmHg. If higher than this ACE-inhibitor is suggested to reach this level. Recheck echocardiogram is recommended in 6 months, earlier if murmur grade increases or clinical signs initiate.



INVOICE

35459

DATE

2/4/22



PATIENT

Maisy Spring

SPECIES

Canine

BREED

Yorkie

SEX

Spayed Female

AGE

10 Years

WEIGHT

1.25 kg

INTERPRETED BY

Eric Lindquist, DMV

DABVP, Cert. IVUSS

IMAGING PERFORMED BY

Dave Stasiuk

HOSPITAL NAME

Resolution Vet
Ultrasound

REFERRING VET

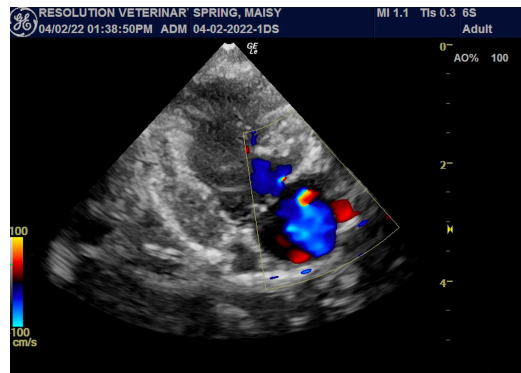
Dr. Sasa Karagic

INVOICE

35459

DATE

2/4/22



The information and recommendations provided are based on the images presented by the referring veterinarian/sonographer. No evaluation can be communicated regarding pathology that was not visible in the image/video clips provided.

Thank you for this referral. If the clinical or image interpretation does not parallel your findings or if I can be of any further assistance please contact me.

Eric Lindquist, DMV, DABVP, Cert. IVUSS, CEO of SonoPath.com

info@SonoPath.com