



PATIENT PRESENTING CLINICAL SIGNS

Hallie Carter Heartworm + w/clinical signs. Heart murmur.

SPECIES ULTRASONOGRAPHIC EXAMINATION OF THE HEART

Canine

BREED

Mix

SEX

Spayed Female

AGE

4 Years

WEIGHT

CANINE CARDIAC PARAMETERS	MR VMAX (m/s)	TR VMAX (m/s)	LA/AO (Boon method)	LA/AO (Heart Base; Swe)	FS (%)	EF (%)	EPSS (cm)
NORMAL PARAMETER	4.5-5.5	<2.7	1.3	<1.6	28-40	40-100	<0.6
PATIENT			1.0	1.3	40	72	NM
CANINE CARDIAC PARAMETERS	HR (BPM)	AV VMAX (m/s)	PV MAX (m/s)	BODY WEIGHT (kg)	LA 2D short axis Base view (cm)	LVIDd Avg; 2D and m-mode short axis (cm)	LVIDs Avg; 2D and m-mode short axis (cm)
NORMAL PARAMETER	50-100	0.7-1.7	0.7-1.6				
PATIENT		1.67	1.09		3.25	3.07	

Cardiac Presentation

The echocardiogram in this patient demonstrated normal **left atrial** size based on 3 separate methods of LA evaluation. Trivial **mitral** insufficiency noted. The **left ventricle** presented thicknesses with linear contour and was not dilated nor restricted. The **myocardium** presented normal echogenicity without subjective evidence of significant fibrotic or ischemic disease. **Contractility** of the ventricular walls was adequate and in normal range for this patient evidenced by the fractional shortening measurement and subjective evaluation of the different regions of the myocardium. The **left ventricular outflow** tract demonstrated normal laminar flow and subjective structural integrity. The **right atrium** and auricle revealed normal size, structure and content. No evidence of masses was noted. Trivial **tricuspid** insufficiency noted. The **right ventricle** was of normal size (1/3 diameter of LV), chordae structure, myocardial echogenicity and thickness. **Pulmonary outflow** tract assessment revealed normal valve structure, laminar flow, and diameter (approx.1:1 pa/ao ratio). No visible **pericardial** or free pleura fluid was noted. The cranial **mediastinum** and **pericardial** and **extra-cardiac** regions were free of masses in the visible window.

ULTRASONOGRAPHIC FINDINGS

- Essentially normal echocardiogram with trivial mitral and tricuspid insufficiency

INTERPRETATION OF THE FINDINGS & FURTHER RECOMMENDATIONS

No evidence of primary cardiac disease or heartworms.

INTERPRETED BY

Eric Lindquist, DMV

DABVP, Cert. IVUSS

IMAGING PERFORMED BY

Eric Lindquist, DMV

DABVP, Cert. IVUSS

HOSPITAL NAME

Parsipanny Troy Hills

REFERRING VET

Dr. Dulude

INVOICE

35457

DATE

2/4/22



PATIENT

Hallie Carter

SPECIES

Canine

BREED

Mix

SEX

Spayed Female

AGE

4 Years

WEIGHT

INTERPRETED BY

Eric Lindquist, DMV
DABVP, Cert. IVUSS

IMAGING PERFORMED BY

Eric Lindquist, DMV
DABVP, Cert. IVUSS

HOSPITAL NAME

Parsipanny Troy Hills

REFERRING VET

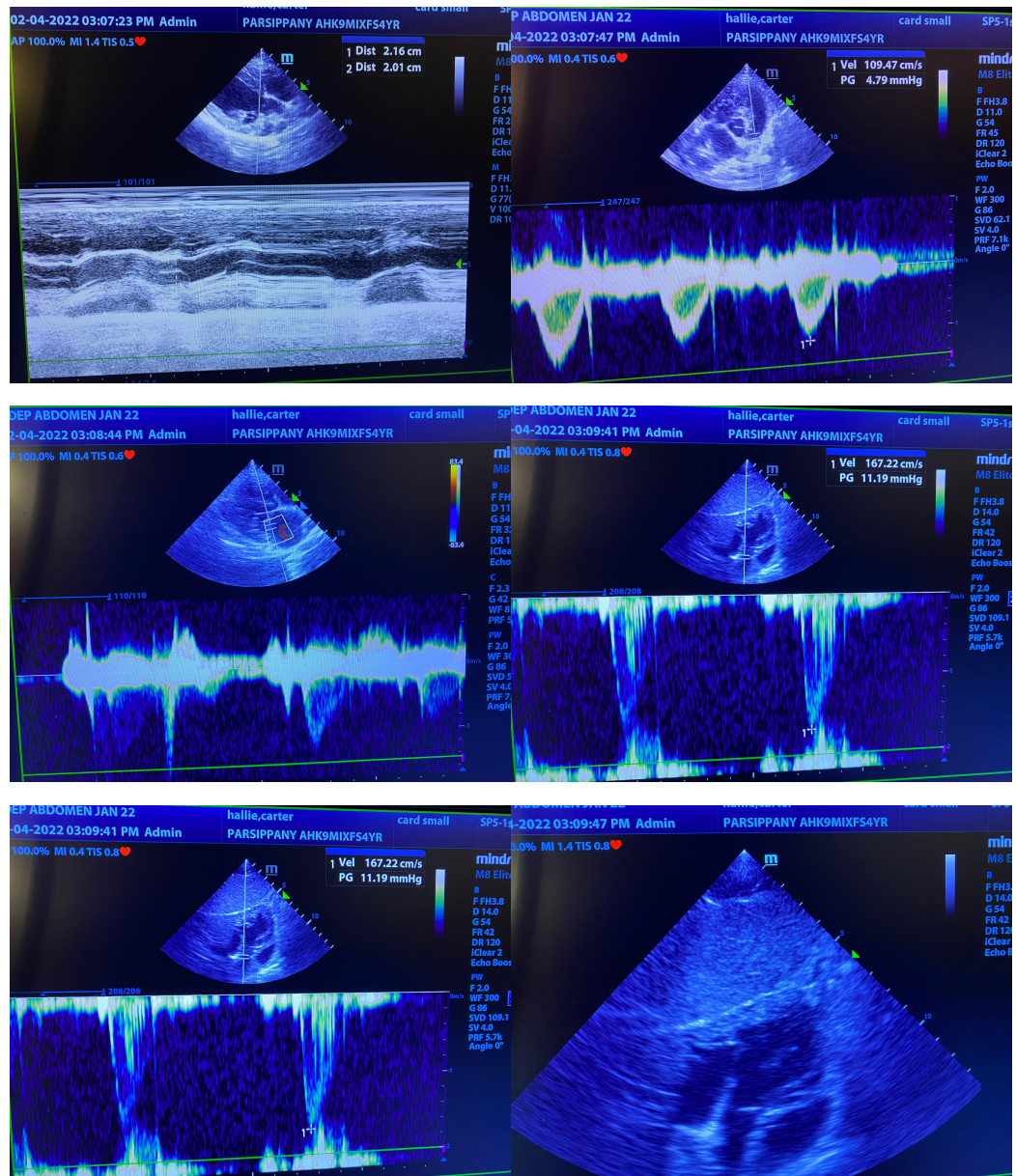
Dr. Dulude

INVOICE

35457

DATE

2/4/22



The information and recommendations provided are based on the images presented by the referring veterinarian/sonographer. No evaluation can be communicated regarding pathology that was not visible in the image/video clips provided.

Thank you for this referral. If the clinical or image interpretation does not parallel your findings or if I can be of any further assistance please contact me.

Eric Lindquist, DMV, DABVP, Cert. IVUSS, CEO of SonoPath.com

info@SonoPath.com