

PATIENT PRESENTING CLINICAL SIGNS

Griffen Rago Recheck echo from 1/7/22. Dx with Advanced Stage B2 valvular disease On Lasix, enalapril and Pimobendan
Abnormal PE/Chem/CBC/UA Results: BP 106/78(90),114/71(82)

SPECIES

Canine

ULTRASONOGRAPHIC EXAMINATION OF THE HEART

BREED

Mix

SEX

Neutered Male

AGE

10 Years

WEIGHT

30 Pounds

CANINE CARDIAC PARAMETERS	MR VMAX (m/s)	TR VMAX (m/s)	LA/AO (Boon method)	LA/AO (Heart Base; Swe)	FS (%)	EF (%)	EPSS (cm)
NORMAL PARAMETER	4.5-5.5	<2.7	1.3	<1.6	28-40	40-100	<0.6
PATIENT			1.1	1.6	56	88	0.1
CANINE CARDIAC PARAMETERS	HR (BPM)	AV VMAX (m/s)	PV MAX (m/s)	BODY WEIGHT (kg)	LA 2D short axis Base view (cm)	LVIDd Avg; 2D and m-mode short axis (cm)	LVIDs Avg; 2D and m-mode short axis (cm)
NORMAL PARAMETER	50-100	0.7-1.7	0.7-1.6				
PATIENT	61		1.4		3.05	3.16	

INTERPRETED BY

Eric Lindquist, DMV
DABVP, Cert. IVUSS

IMAGING PERFORMED BY

JK

HOSPITAL NAME

Hamburg Vet Clinic

REFERRING VET

Dr. Martens

INVOICE

35473

DATE

2/4/22

Cardiac Presentation

The echocardiogram in this patient demonstrated normal **left atrial** size based on 3 separate methods of LA evaluation. **Mitral** insufficiency noted on color flow and spectral doppler. The **left ventricle** presented thicknesses with linear contour and was not dilated nor restricted. The **myocardium** presented normal echogenicity without subjective evidence of significant fibrotic or ischemic disease. **Contractility** of the ventricular walls was adequate and in normal range for this patient evidenced by the fractional shortening measurement and subjective evaluation of the different regions of the myocardium. The **left ventricular outflow** tract demonstrated normal laminar flow and subjective structural integrity. The **right atrium** and auricle revealed normal size, structure and content. No evidence of masses was noted. **Tricuspid** valve revealed mild insufficiency at 1.8 m/sec. The **right ventricle** was of normal size (1/3 diameter of LV), chordae structure, myocardial echogenicity and thickness. **Pulmonary outflow** tract assessment revealed normal valve structure, laminar flow, and diameter (approx. 1:1 pa/ao ratio). No visible **pericardial** or free pleura fluid was noted. The cranial **mediastinum** and **pericardial** and **extra-cardiac** regions were free of masses in the visible window.

ULTRASONOGRAPHIC FINDINGS

- Compensated valvular disease on current protocol

INTERPRETATION OF THE FINDINGS & FURTHER RECOMMENDATIONS

Recommend continuation of the current protocol and recheck echo in 6 months as long as no clinical signs are present. The cardiac volumes appear to be stabilized at this point. Recheck echo in 6 months.



PATIENT

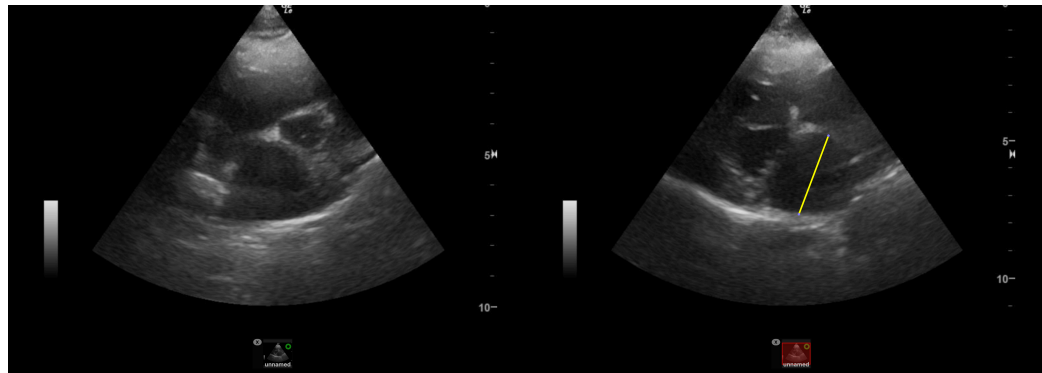
Griffen Rago

SPECIES

Canine

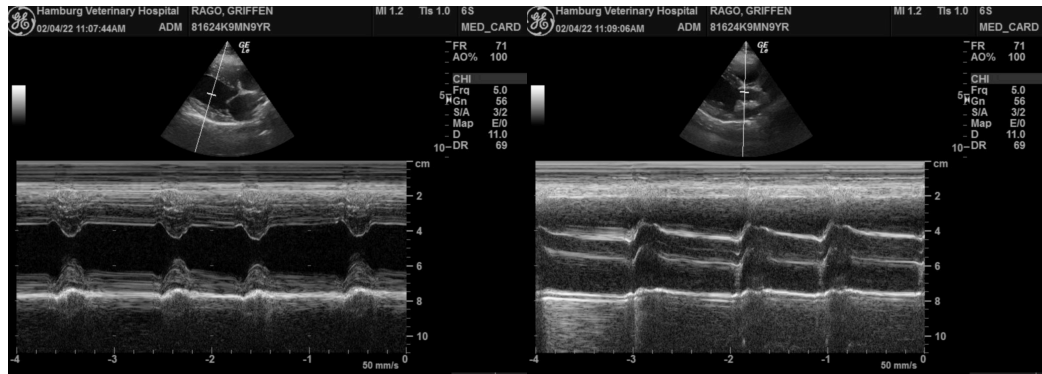
BREED

Mix



SEX

Neutered Male



AGE

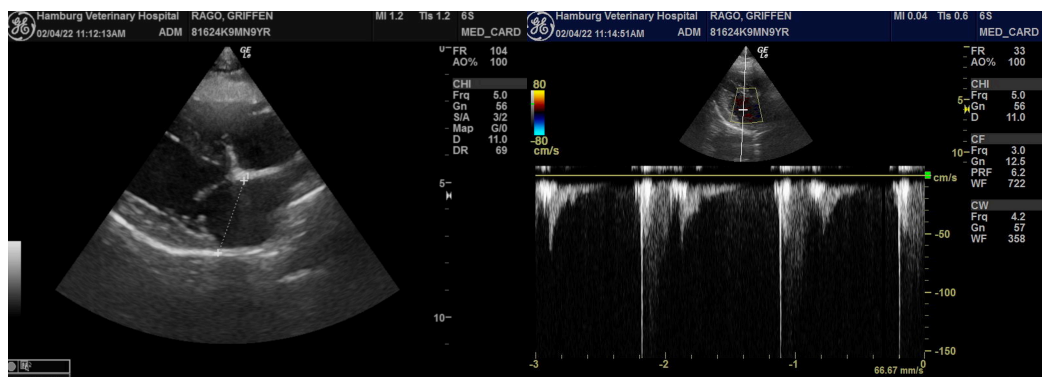
10 Years

WEIGHT

30 Pounds

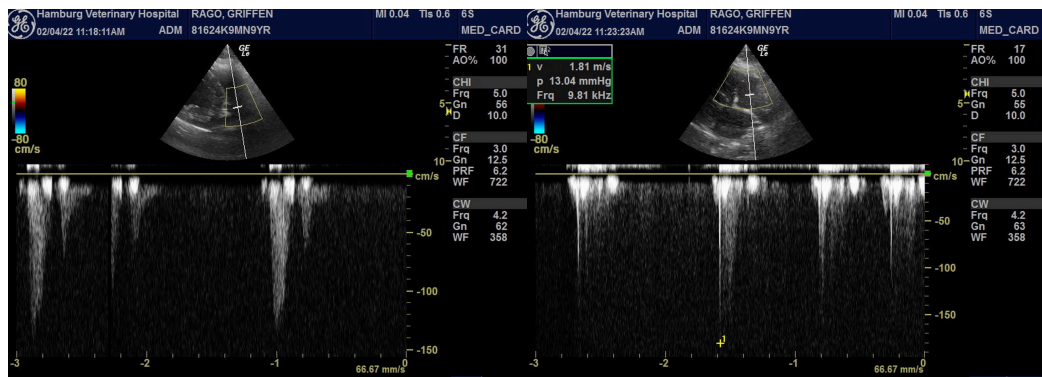
INTERPRETED BY

Eric Lindquist, DMV
DABVP, Cert. IVUS



HOSPITAL NAME

Hamburg Vet Clinic



REFERRING VET

Dr. Martens

INVOICE

35473

DATE

2/4/22



PATIENT

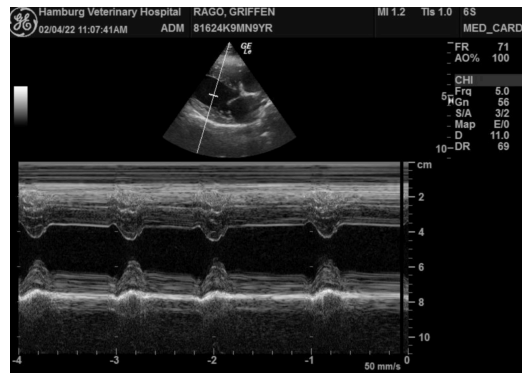
Griffen Rago

SPECIES

Canine

BREED

Mix



SEX

Neutered Male

The information and recommendations provided are based on the images presented by the referring veterinarian/sonographer. No evaluation can be communicated regarding pathology that was not visible in the image/video clips provided.

AGE

10 Years

Thank you for this referral. If the clinical or image interpretation does not parallel your findings or if I can be of any further assistance please contact me.

Eric Lindquist, DMV, DABVP, Cert. IVUSS, CEO of SonoPath.com

info@SonoPath.com

WEIGHT

30 Pounds

INTERPRETED BY

Eric Lindquist, DMV

DABVP, Cert. IVUSS

IMAGING PERFORMED BY

JK

HOSPITAL NAME

Hamburg Vet Clinic

REFERRING VET

Dr. Martens

INVOICE

35473

DATE

2/4/22