



PATIENT

Miss Smudges
Dillingham

SPECIES

Canine

BREED

Dachshund

SEX

Spayed female

AGE

8 years

WEIGHT

6.39 kg

INTERPRETED BY

Eric Lindquist, DMV
DABVP, Cert. IVUSS

IMAGING PERFORMED BY

Dr. Moore

HOSPITAL NAME

Lone Mountain AH

REFERRING VET

Dr. Moore

INVOICE

71199

DATE

2/3/26

PRESENTING CLINICAL SIGNS

- vomiting for 4 days - bile and undigested food. loose stools.
- Elevated ALT 136 elevated ALP 443 BP 180mmHg proteinuria radiographs confirmed hepatomegaly

ULTRASONOGRAPHIC EXAMINATION OF THE ABDOMEN

Urinary System

The **urinary bladder**, trigone, and pelvic urethra presented normal thicknesses and normal tone. The ureters were not visible which is normal. No uroliths or sediment were visualized and anechoic urine was present. No evidence of inflammatory or neoplastic changes was noted. Ureteral papillae were normal.

The **kidneys** revealed largely normal size and structure, corticomedullary definition and ratio (cortex 1/3 of medulla) were essentially maintained with some age-related loss of curvilinear patterns regarding the capsule and C/M junction. The cortices presented largely uniform texture with some increased echogenicity expected for this age patient. Medullary structure differed distinctly from that of the cortex and no evidence of pelvic dilation was present. The right kidney measured 4.4 cm. The left kidney measured 4.1 cm.

Adrenal Glands

The left **adrenal gland** was uniform and measured 0.57 cm. The region of the right adrenal gland was imaged with no evidence of pathology.

Spleen

The **spleen** presented a smooth homogeneous parenchyma hyperechoic to liver and renal cortical parenchyma. The capsule was smooth without noticeable expansion or deviation from within the spleen or adjacent pathology. The splenic vasculature demonstrated normal volume without signs of congestion or thrombosis. No sonographic evidence of acute or chronic inflammatory, neoplastic, or infarctual changes was noted.

Liver

The **liver** images from right and left intercostal as well as subcostal views revealed subjectively normal liver size, contour, and structure. Some age-related parenchymal remodeling was noted but likely not clinically significant at this time. Vascular and biliary tracts were of normal volume and no evidence of congestion was noted. The gallbladder was mildly over distended with suspended and dependent debris, yet not to the level of emerging mucocele, yet sludge appears to be mildly excessive. No adjunctive inflammation was noted.



PATIENT

Miss Smudges
Dillingham

SPECIES

Canine

BREED

Dachshund

SEX

Spayed female

AGE

8 years

WEIGHT

6.39 kg

INTERPRETED BY

Eric Lindquist, DMV
DABVP, Cert. IVUSS

IMAGING PERFORMED BY

Dr. Moore

HOSPITAL NAME

Lone Mountain AH

REFERRING VET

Dr. Moore

INVOICE

71199

DATE

2/3/26

Gastrointestinal

Examination of the **gastrointestinal tract** revealed a stomach and intestine free of stasis, of normal wall thickness, acceptable curvilinear mural detail, and peristaltic activity. Small and large intestine demonstrated normal luminal chyme and stool consistency respectively. No obstructive or overt infiltrative disease was noted. No associated abnormal lymphatic activity was noted.

Pancreas

The base and limbs of the **pancreas** were observed to be largely isoechoic to surrounding omental fat. Pancreatic duct and capsular contour were acceptably normal and parenchyma respected normal curvilinear patterns. No overt evidence of active inflammatory or neoplastic disease was noted.

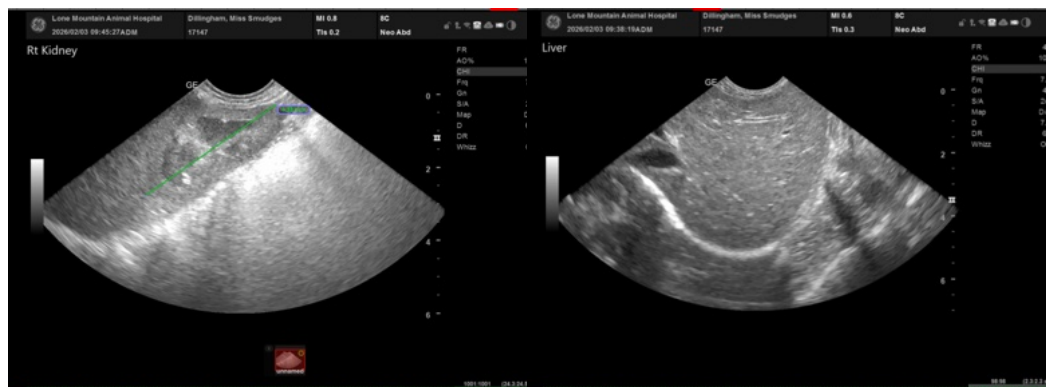
ULTRASONOGRAPHIC FINDINGS

Age related abdominal changes with minor excessive gallbladder inspissation.

INTERPRETATION OF THE FINDINGS & FURTHER RECOMMENDATIONS

Ursodiol therapy can be considered as a proactive measure, yet debatable on its necessity at this point. Supportive care should prove effective. FNA of the liver can be considered for further definition if enzyme remain elevated. Structurally the GI tract is unremarkable.

Dietary indiscretion, food intolerance, structurally significant inflammatory bowel or occult parasitism and occult Addison's are all potentials.





PATIENT

Miss Smudges
Dillingham

SPECIES

Canine

BREED

Dachshund

SEX

Spayed female

AGE

8 years

WEIGHT

6.39 kg

INTERPRETED BY

Eric Lindquist, DMV
DABVP, Cert. IVUSS

IMAGING PERFORMED BY

Dr. Moore

HOSPITAL NAME

Lone Mountain AH

REFERRING VET

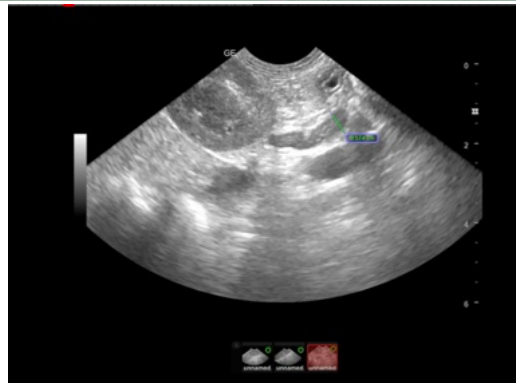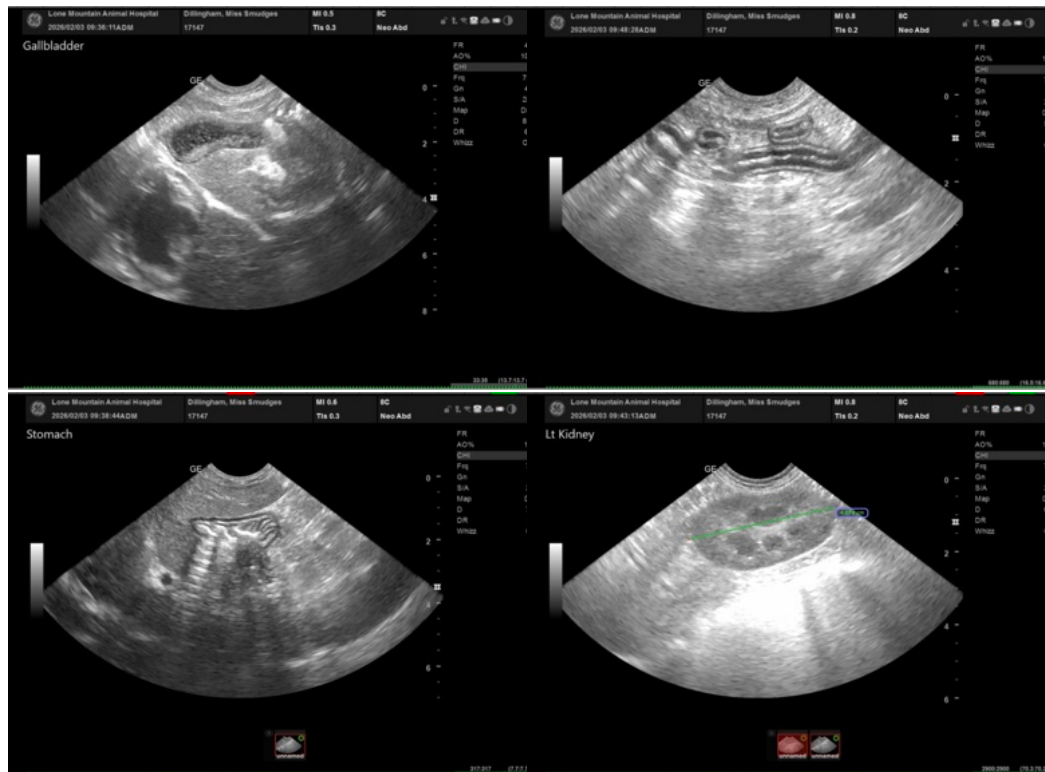
Dr. Moore

INVOICE

71199

DATE

2/3/26



The information and recommendations provided are based on the images presented by the referring veterinarian/sonographer. No evaluation can be communicated regarding pathology that was not visible in the image/video clips provided.

Thank you for this referral. If the clinical or image interpretation does not parallel your findings or if I can be of any further assistance please contact me.

Eric Lindquist, DMV, DABVP (CFM), Cert. IVUSS, CEO of SonoPath.com

info@SonoPath.com