



PATIENT

Weedy Trujillo

PRESENTING CLINICAL SIGNS

Chronic diarrhea, weight loss, and URI Patient is hyperthyroid - undergoing treatment

SPECIES

Feline

Abnormal PE/Chem/CBC/UA Results: PE: nasal discharge, BCS 4/9 CBC: neutrophilia and monocytosis Chem: AMY 1570, K 6.7 FeIV/FIV: Negative Fecal: NPS

BREED

DSH

ULTRASONOGRAPHIC EXAMINATION OF THE ABDOMEN

Urinary System

The **urinary bladder**, trigone, and pelvic urethra presented normal thicknesses and normal tone. The ureters were not visible which is normal. No uroliths or sediment were visualized and anechoic urine was present. No evidence of inflammatory or neoplastic changes were noted. Ureteral papillae were normal.

SEX

Neutered Male

AGE

9 Years

The **kidneys** revealed largely normal size and structure, corticomedullary definition and ratio (cortex 1/3 of medulla) were essentially maintained with some age-related loss of curvilinear patterns regarding the capsule and C/M junction. The cortices presented largely uniform texture with some increased echogenicity expected for his age patient. Medullary structure differed distinctly from that of the cortex and no evidence of pelvic dilation was present. The right kidney measured 3.94 cm. The left kidney measured 4.17 cm.

WEIGHT

9.4

Adrenal Glands

The regions of the **adrenal glands** were unremarkable.

INTERPRETED BY

Eric Lindquist, DMV

Spleen

The **spleen** presented a smooth homogeneous parenchyma hyperechoic to liver and renal cortical parenchyma. The capsule was smooth without noticeable expansion or deviation from within the spleen or adjacent pathology. The splenic vasculature demonstrated normal volume without signs of congestion or thrombosis. No sonographic evidence of acute or chronic inflammatory, neoplastic, or infarctual changes were noted.

DABVP, Cert. IVUSS

IMAGING PERFORMED BY

Cristina Polit/Mayra Sanchez

Liver

The **liver** images from right and left intercostal as well as subcostal views revealed subjectively normal liver size, contour, and structure. Some age-related parenchymal remodeling was noted but likely not clinically significant at this time. Vascular and biliary tracts were of normal volume and no evidence of congestion was noted. The gallbladder presented some dependent debris with essentially normal contour. The cystic and common bile ducts were normal. No overt evidence of active inflammatory, infiltrative or regenerative pathology was noted but should be paired with current or past LE elevations regarding any clinical significance to this presentation. The hepatic lymph nodes were unremarkable.

HOSPITAL NAME

Sunset AH

REFERRING VET

Dr. Christina Polit

INVOICE

44763

Gastrointestinal

The **gastrointestinal tract** revealed minor variable thickening and echogenic submucosal changes most consistent with low grade end result of chronic GI disease such as IBD and may be related to malassimilation of nutrients if any weight loss is present. No obvious neoplastic patterns were noted and luminal content as unremarkable.

DATE

2/3/23



PATIENT

Weedy Trujillo

SPECIES

Feline

BREED

DSH

SEX

Neutered Male

AGE

9 Years

WEIGHT

9.4

INTERPRETED BY

Eric Lindquist, DMV

DABVP, Cert. IVUSS

IMAGING PERFORMED BY

Cristina Polit/Mayra Sanchez

HOSPITAL NAME

Sunset AH

REFERRING VET

Dr. Christina Polit

INVOICE

44763

DATE

2/3/23

Pancreas

The base and limbs of the **pancreas** were observed to be largely isoechoic to surrounding omental fat. Pancreatic duct and capsular contour were acceptably normal and parenchyma respected normal curvilinear patterns. No overt evidence of active inflammatory or neoplastic disease was noted.

Free Abdomen

Some reactive mesentery noted associated with the small intestine. The lymph nodes were mildly enlarged up to 1.0 cm and somewhat rounded.

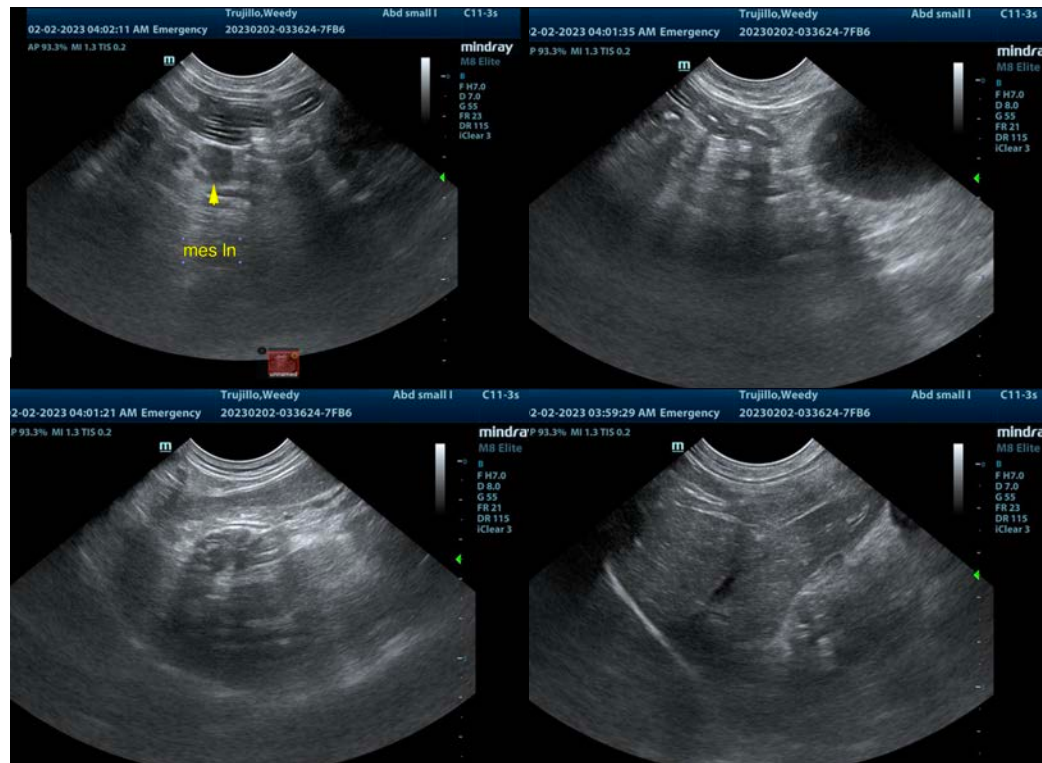
ULTRASONOGRAPHIC FINDINGS

- Geriatric abdomen with mild mesenteric lymphadenopathy
- Minor intestinal thickening

INTERPRETATION OF THE FINDINGS & FURTHER RECOMMENDATIONS

No overt neoplastic criteria. However, emerging round cell neoplasia cannot be completely ruled out. Full thickness intestinal and lymph nodes biopsies would be ideal. If accessible, FNA of the mesenteric lymph nodes indicated.

Maldigestion panel, three view chest radiographs and full CNS examination is recommended to examine for occult disease that could be responsible for the weight loss. Evaluation for competitive eating environments should also be considered.





PATIENT

Weedy Trujillo

SPECIES

Feline

BREED

DSH

SEX

Neutered Male

AGE

9 Years

WEIGHT

9.4

INTERPRETED BY

Eric Lindquist, DMV

DABVP, Cert. IVUSS

IMAGING PERFORMED BY

Cristina Polit/Mayra Sanchez

HOSPITAL NAME

Sunset AH

REFERRING VET

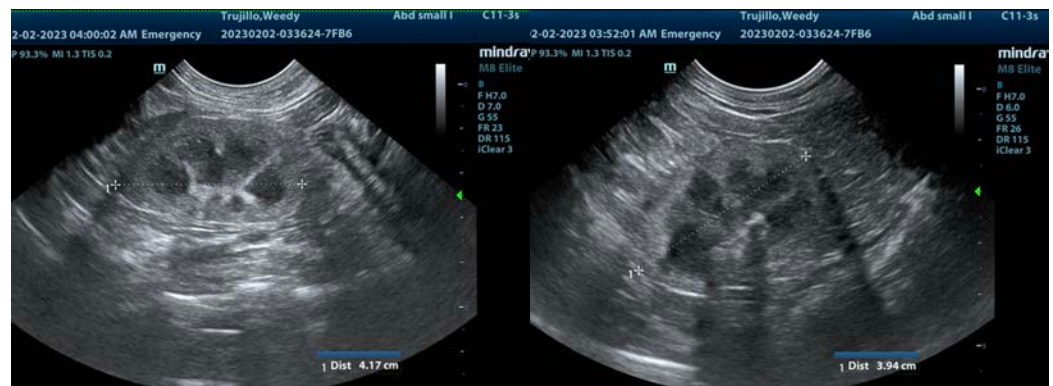
Dr. Christina Polit

INVOICE

44763

DATE

2/3/23



The information and recommendations provided are based on the images presented by the referring veterinarian/sonographer. No evaluation can be communicated regarding pathology that was not visible in the image/video clips provided.

Thank you for this referral. If the clinical or image interpretation does not parallel your findings or if I can be of any further assistance please contact me.

Eric Lindquist, DMV, DABVP, Cert. IVUSS, CEO of SonoPath.com

info@SonoPath.com