



PATIENT PRESENTING CLINICAL SIGNS

Ralphie Clegg History: murmur 5/6. Just started Vetoryl 10 mg x1 tab sid, and Pimobendan 10 mg x 1/2 tab bid. Cushings, osteoarthritis, grade 2 pdd, mass on adrenal

SPECIES Abnormal PE/Chem/CBC/UA Results: ALKP 1962, trig 546, lipase 340, T4 < 0.5; monocytes increased.
 Canine UA: pH7, USPG 1.003, squamous epithelial cells 2-3/hpf, wbcs 0-2

ULTRASONOGRAPHIC EXAMINATION OF THE HEART

BREED

Mixed

SEX

Neutered Male

AGE

12 Years

WEIGHT

42 Pounds

CANINE CARDIAC PARAMETERS	MR VMAX (m/s)	TR VMAX (m/s)	LA/AO (Boon method)	LA/AO (Heart Base; Swe)	FS (%)	EF (%)	EPSS (cm)
NORMAL PARAMETER	4.5-5.5	<2.7	1.3	<1.3	28-40	40-100	<0.6
PATIENT	5.0	3.2	NM	1.0	50	90	0.1
CANINE CARDIAC PARAMETERS	HR (BPM)	AV VMAX (m/s)	PV MAX (m/s)	BODY WEIGHT (kg)	LA 2D short axis Base view (cm)	LVIDd Avg; 2D and m-mode short axis (cm)	LVIDs Avg; 2D and m-mode short axis (cm)
NORMAL PARAMETER	50-100	0.7-1.7	0.7-1.6				
PATIENT	--	2.0	1.50	--	2.9	2.1	--

INTERPRETED BY

Eric Lindquist, DMV
 DABVP, Cert. IVUSS

IMAGING PERFORMED BY

Diane McFadden

HOSPITAL NAME

Sova

REFERRING VET

Dr. Bott-Wentworth

INVOICE

20957

DATE

2/3/23

Cardiac Presentation

The cardiac presentation in this patient presented tachycardia with arrhythmogenic activity. The patient appeared subjectively volume contracted in the left ventricle and left atrium. The left atrium measured 2.9 cm. Mitral and tricuspid insufficiency were present. The LA/AO heart base measurement was subnormal. Concentric hypertrophy of the left ventricle was noted.

ULTRASONOGRAPHIC FINDINGS

- Volume contracted left atrium and left ventricle
- No evidence of volume overload
- Tachycardia

INTERPRETATION OF THE FINDINGS & FURTHER RECOMMENDATIONS

Blood pressure measurements are recommended. I recommend assessing hydration status in this patient, as volume contraction is an issue. I recommend stopping Pimobendan at this time and reassessing. Even though the left atrium was definitively enlarged at the prior sonogram, it appears to be normal to subnormal in size at this time. Blood pressure measurements, causes of tachycardia and EKG are indicated. The combination of Cushings disease, adrenal tumor and Trilostane may be playing a role. Assessment for potential hemorrhage related to the adrenal mass would be warranted if not recently evaluated.



PATIENT

Ralphie Clegg

SPECIES

Canine

BREED

Mixed

SEX

Neutered Male

AGE

12 Years

WEIGHT

42 Pounds

INTERPRETED BY

Eric Lindquist, DMV
DABVP, Cert. IVUSS

IMAGING PERFORMED BY

Diane McFadden

HOSPITAL NAME

Sova

REFERRING VET

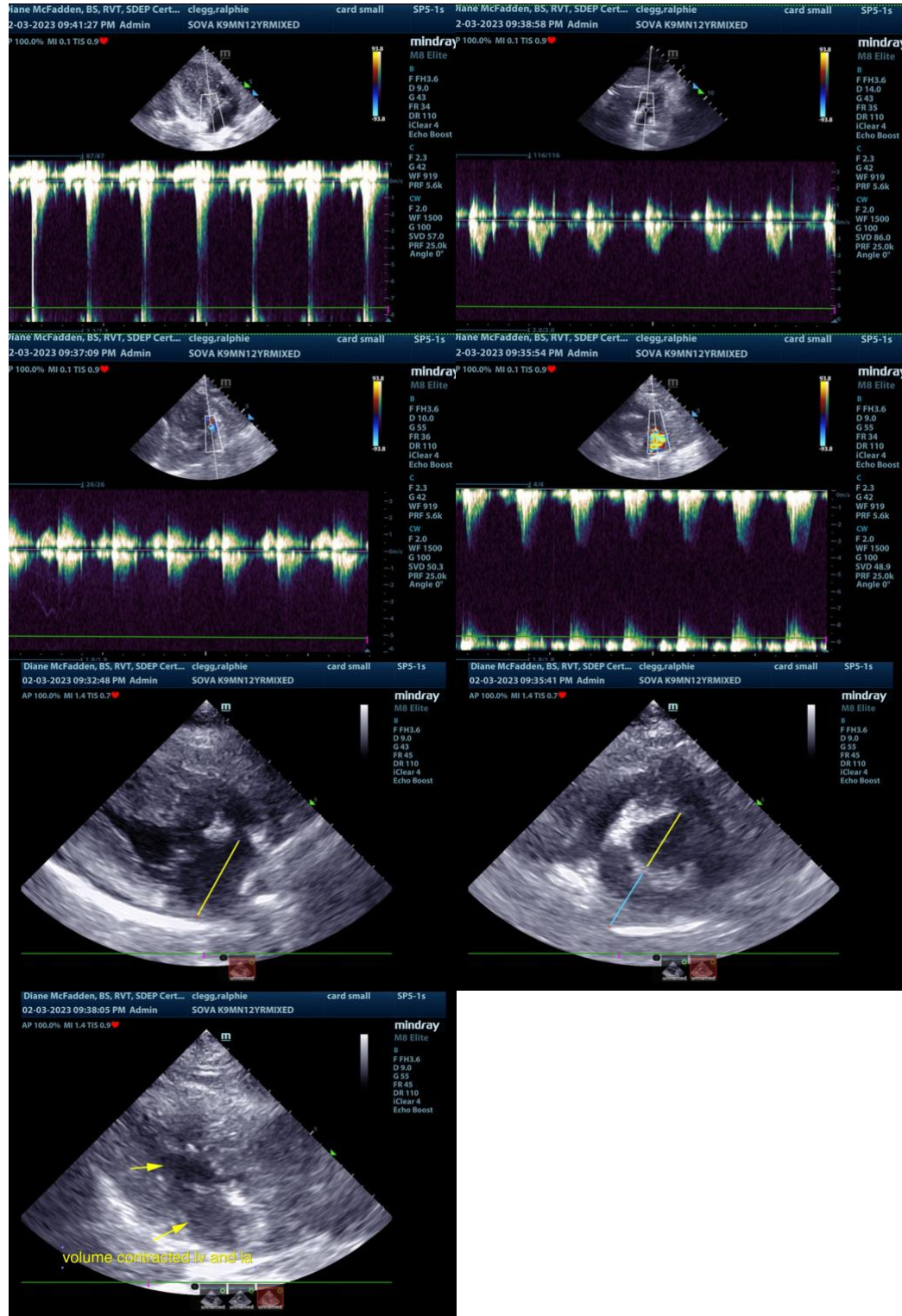
Dr. Bott-Wentworth

INVOICE

20957

DATE

2/3/23



The information and recommendations provided are based on the images presented by the referring veterinarian. No evaluation can be communicated regarding pathology that was not visible in the image/video clips provided.



PATIENT

Ralphie Clegg

Thank you for this referral. If the clinical or image interpretation does not parallel your findings or if I can be of any further assistance please contact me.

SPECIES

Canine

Eric Lindquist, DMV, DABVP, Cert. IVUSS, CEO of SonoPath.com
info@SonoPath.com

BREED

Mixed

SEX

Neutered Male

AGE

12 Years

WEIGHT

42 Pounds

INTERPRETED BY

Eric Lindquist, DMV
DABVP, Cert. IVUSS

**IMAGING
PERFORMED BY**

Diane McFadden

HOSPITAL NAME

Sova

REFERRING VET

Dr. Bott-Wentworth

INVOICE

20957

DATE

2/3/23