

PATIENT

Penny Blaney

SPECIES

Canine

BREED

Poodle X

SEX

Intact Female

AGE

1 Year

WEIGHT

14 kg

INTERPRETED BY

Eric Lindquist, DMV
DABVP, Cert. IVUSS

IMAGING PERFORMED BY

Kelly Reschny

HOSPITAL NAME

Hillview VC

REFERRING VET

Dr. Stevenson

INVOICE

20959

DATE

2/3/23

PRESENTING CLINICAL SIGNS

History: PREG check Feb 2/23- Is scheduled for a spay in a few weeks. Has an intact male at home. O not sure if the dogs tied but notices that Penny's abdomen is looser this last week. O does not wish puppies. Rec'd ultrasound to see if she is pregnant so she can decide next step. If they tied, it would be 45 days now.

LIMITED ULTRASONOGRAPHIC EXAMINATION

The left ovary was uniform, measuring 1.56 cm x 0.89 cm. The right ovary was uniform, measuring 1.64 cm x 0.79 cm.

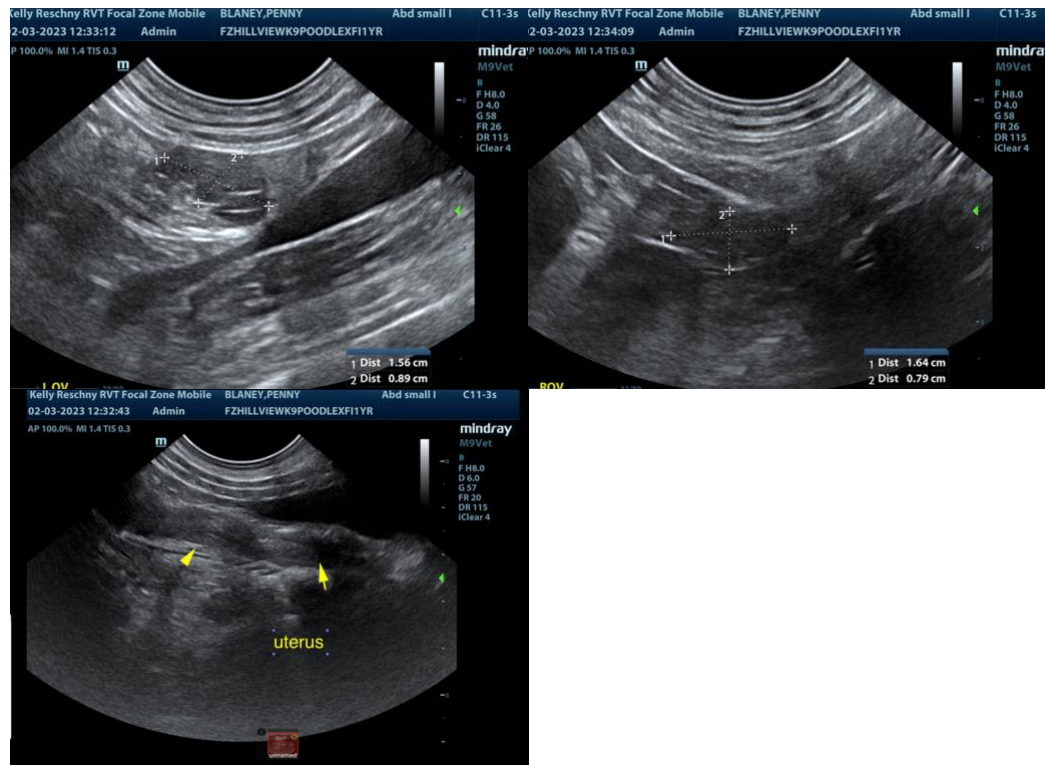
The uterus was uniform and empty.

ULTRASONOGRAPHIC FINDINGS

- Empty uterus
- Normal ovaries

INTERPRETATION OF THE FINDINGS & FURTHER RECOMMENDATIONS

No evidence of pathology. Negative pregnancy check.



The information and recommendations provided are based on the images presented by the referring veterinarian. No evaluation can be communicated regarding pathology that was not visible in the image/video clips provided.

Thank you for this referral. If the clinical or image interpretation does not parallel your findings or if I



PATIENT

can be of any further assistance please contact me.

Penny Blaney

Eric Lindquist, DMV, DABVP, Cert. IVUSS, CEO of SonoPath.com
Eric.Lindquist@SonoPath.com

SPECIES

Canine

BREED

Poodle X

SEX

Intact Female

AGE

1 Year

WEIGHT

14 kg

INTERPRETED BY

Eric Lindquist, DMV
DABVP, Cert. IVUSS

**IMAGING
PERFORMED BY**

Kelly Reschny

HOSPITAL NAME

Hillview VC

REFERRING VET

Dr. Stevenson

INVOICE

20959

DATE

2/3/23