



**PATIENT**

Hershey Martin

**SPECIES**

Canine

**BREED**

Boston Terrier

**SEX**

Neutered Male

**AGE**

10 Years

**WEIGHT**

14.6 Pounds

**PRESENTING CLINICAL SIGNS**

History: heart-based tumor noted on echo 8/5/22 with trivial MR and TR. on chlorambucil 0.95 mg bid

**ULTRASONOGRAPHIC EXAMINATION OF THE HEART**

CANINE CARDIAC PARAMETERS	MR VMAX (m/s)	TR VMAX (m/s)	LA/AO (Boon method)	LA/AO (Heart Base; Swe)	FS (%)	EF (%)	EPSS (cm)
<b>NORMAL PARAMETER</b>	4.5-5.5	<2.7	1.3	<1.3	28-40	40-100	<0.6
<b>PATIENT</b>	5.0	3.0	NM	1.47	36	67	0.1
CANINE CARDIAC PARAMETERS	HR (BPM)	AV VMAX (m/s)	PV MAX (m/s)	BODY WEIGHT (kg)	LA 2D short axis Base view (cm)	LVIDd Avg; 2D and m-mode short axis (cm)	LVIDs Avg; 2D and m-mode short axis (cm)
<b>NORMAL PARAMETER</b>	50-100	0.7-1.7	0.7-1.6				
<b>PATIENT</b>	175	1.74	1.20	--	2.49	3.11	--

**Cardiac Presentation**

The cardiac presentation in this patient presented mitral and tricuspid insufficiency. No volume overload was noted. The left atrium was enlarged. The heart base mass is persistent and growing dorsal caudally, measuring 3.7 cm x 3.6 cm. The mass is consistent with aortic body tumor/chemodectoma. No pericardial or pleural effusion are noted. The hepatic veins were not dilated.

**INTERPRETED BY**

Eric Lindquist, DMV  
DABVP, Cert. IVUSS

**IMAGING PERFORMED BY**

Diane McFadden

**HOSPITAL NAME**

Brenda King, VMD

**REFERRING VET**

Dr. King

**INVOICE**

20958

**DATE**

2/3/23

**ULTRASONOGRAPHIC FINDINGS**

- Slow growing heart base mass
- Compensated mitral and tricuspid insufficiency

**INTERPRETATION OF THE FINDINGS & FURTHER RECOMMENDATIONS**

Blood pressure and EKG are indicated, if not already performed.



**PATIENT**

Hershey Martin

**SPECIES**

Canine

**BREED**

Boston Terrier

**SEX**

Neutered Male

**AGE**

10 Years

**WEIGHT**

14.6 Pounds

**INTERPRETED BY**

Eric Lindquist, DMV  
DABVP, Cert. IVUSS

**IMAGING PERFORMED BY**

Diane McFadden

**HOSPITAL NAME**

Brenda King, VMD

**REFERRING VET**

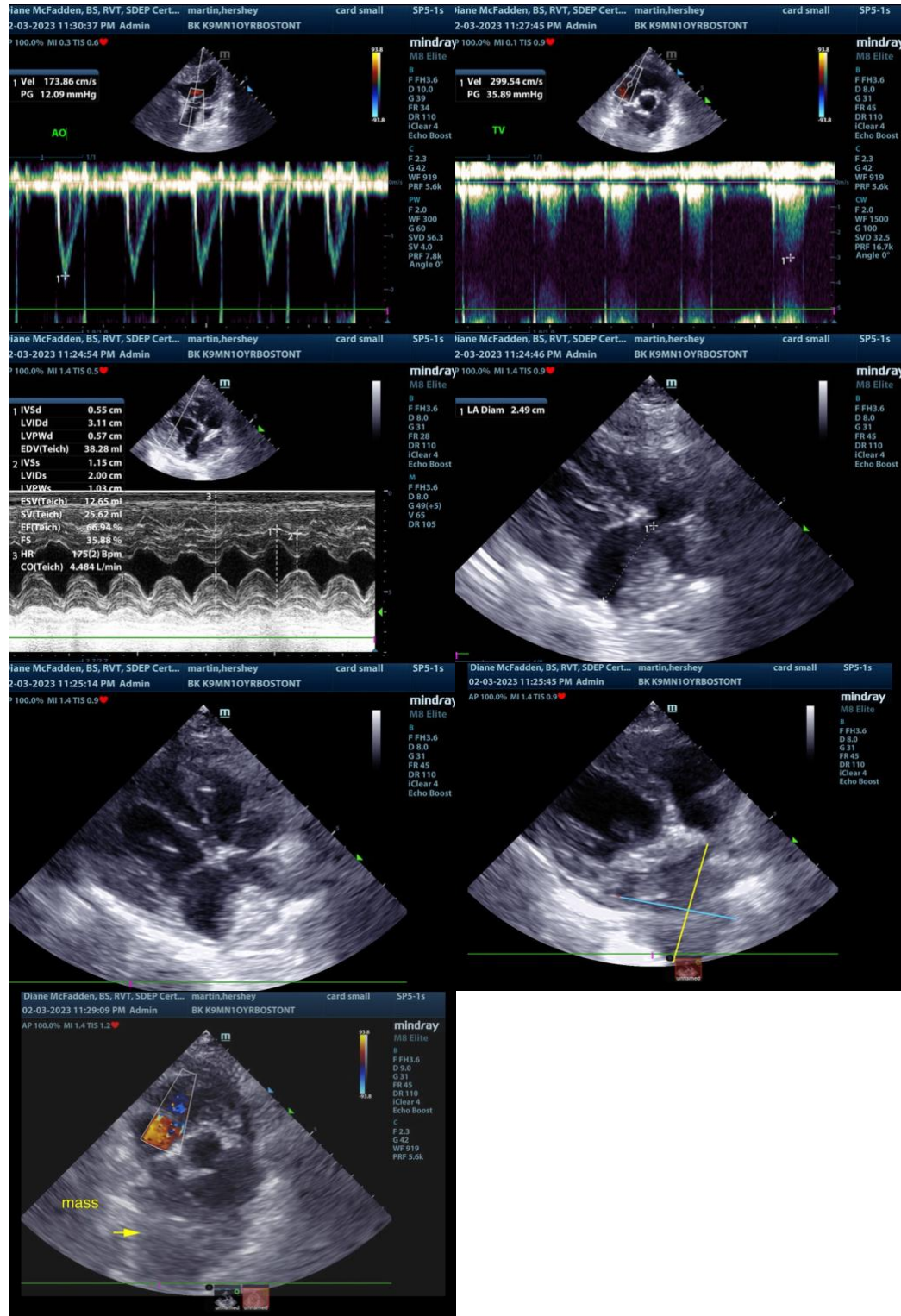
Dr. King

**INVOICE**

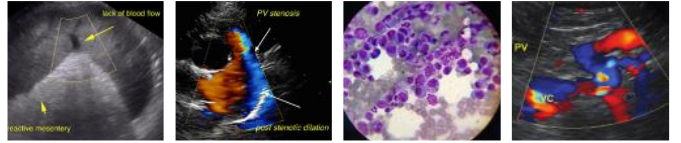
20958

**DATE**

2/3/23



The information and recommendations provided are based on the images presented by the referring veterinarian. No evaluation can be communicated regarding pathology that was not visible in the image/video clips provided.



**PATIENT**

Hershey Martin

Thank you for this referral. If the clinical or image interpretation does not parallel your findings or if I can be of any further assistance please contact me.

**SPECIES**

Canine

**Eric Lindquist**, DMV, DABVP, Cert. IVUSS, CEO of SonoPath.com  
info@SonoPath.com

**BREED**

Boston Terrier

**SEX**

Neutered Male

**AGE**

10 Years

**WEIGHT**

14.6 Pounds

**INTERPRETED BY**

Eric Lindquist, DMV  
DABVP, Cert. IVUSS

**IMAGING  
PERFORMED BY**

Diane McFadden

**HOSPITAL NAME**

Brenda King, VMD

**REFERRING VET**

Dr. King

**INVOICE**

20958

**DATE**

2/3/23