IMAGING PERFORMED BY

IntraPet.com

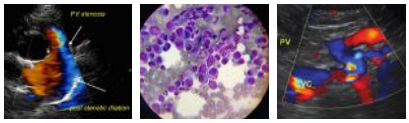

SonoPath
Clinical Sonography & Telecytology
EDUCATIONAL TELECONSULTATION SERVICES™
1-800-838-4268 info@sonopath.com SonoPath.com

DATE

2/3/23

PATIENT

Bosco Chapman

SPECIES

Canine

BREED

German Shepherd

SEX

Neutered Male

AGE

9/6/13

WEIGHT

81.4 Pounds

INTERPRETED BY

Eric Lindquist, DMV
DABVP, Cert. IVUSS

HOSPITAL NAME

Hickory VH

REFERRING VET

Dr. Snyder

INVOICE

20982

PRESENTING CLINICAL SIGNS

History: Lethargic, vomiting for few weeks.

Current Medications: Gabapentin, Yunnan Baiyao.
Lab Results: Mild anemia w/ regeneration, mild ALT elevation.
Radiographs: Lateral chest NSF.
Date of Previous IntraPet Ultrasound: No previous.
Sedation: Not required to complete full diagnostic ultrasound.
Stat Report: Not requested.
Imaging Performed By: Rachel Brilhart, RDMS.

ULTRASONOGRAPHIC EXAMINATION OF THE ABDOMEN

Urinary System

The **urinary bladder**, trigone, and pelvic urethra presented normal thicknesses and normal tone. The ureters were not visible which is normal. No uroliths or sediment were visualized and anechoic urine was present. No evidence of inflammatory or neoplastic changes were noted. Ureteral papillae were normal.

The **kidneys** revealed largely normal size and structure, corticomedullary definition and ratio (cortex 1/3 of medulla) were essentially maintained with some age-related loss of curvilinear patterns regarding the capsule and C/M junction. The cortices presented largely uniform texture with some increased echogenicity expected for his age patient. Medullary structure differed distinctly from that of the cortex and no evidence of pelvic dilation was present. The right kidney measured 7.25 cm. The left kidney measured 7.0 cm.

Adrenal Glands

Both **adrenal glands** were visualized and recognized as having normal shape, size, position and echogenicity for this breed. The phrenic vasculature, glandular echogenicity and detail were unremarkable. Capsule, cortex, and medullary definition were normal for this age patient. The left adrenal gland measured 2.56 cm x 0.77 cm at the caudal pole and 0.68 cm at the cranial pole. The right adrenal gland measured 2.86 cm x 1.23 cm at the cranial pole and 0.92 cm at the caudal pole.

Spleen

The **spleen** was mildly enlarged with slight swollen contour and slight heterogenous parenchymal changes.

Liver

The **liver** revealed a pedunculated, peripherally inflamed, significantly disruptive and disorganized mass (10.0 cm). The right liver appeared largely unremarkable with minor heterogenous changes. Minor gallbladder debris was noted.

Gastrointestinal

Examination of the **gastrointestinal tract** revealed a stomach and intestine free of stasis, of normal wall thickness, acceptable curvilinear mural detail, and peristaltic activity. Small and large intestine demonstrated normal luminal chyme and stool consistency respectively. No obstructive or overt infiltrative disease was noted. No associated abnormal lymphatic activity was noted.

Pancreas

The **pancreas** was enlarged and irregular with undulating contour and loss of structural detail. The left limb measured 2.0 cm in width.

Other

A rapid view of the **heart** revealed no evidence of pathology in the pericardium or right auricle. Contractility appeared normal. No pleural effusion or obvious evidence of metastatic disease was noted.

ULTRASONOGRAPHIC FINDINGS

- Pedunculated left sided liver mass, potentially resectable
- Heterogenous, swollen/enlarged spleen
- Enlarged, irregular pancreas
- Age-related renal changes

INTERPRETATION OF THE FINDINGS & FURTHER RECOMMENDATIONS

Screening FNA of the hepatic mass and spleen could be considered, however, the left sided liver mass is highly precarious and inflamed. The spleen is likely reactive, however, concurrent neoplastic event within the spleen cannot be completely ruled out. I recommend immediate exploratory surgery with expectations towards complete left liver lobectomy given the active inflammation, with inspection of the spleen. Splenectomy at the time of the surgery would be a judgement call by the surgeon at that time.

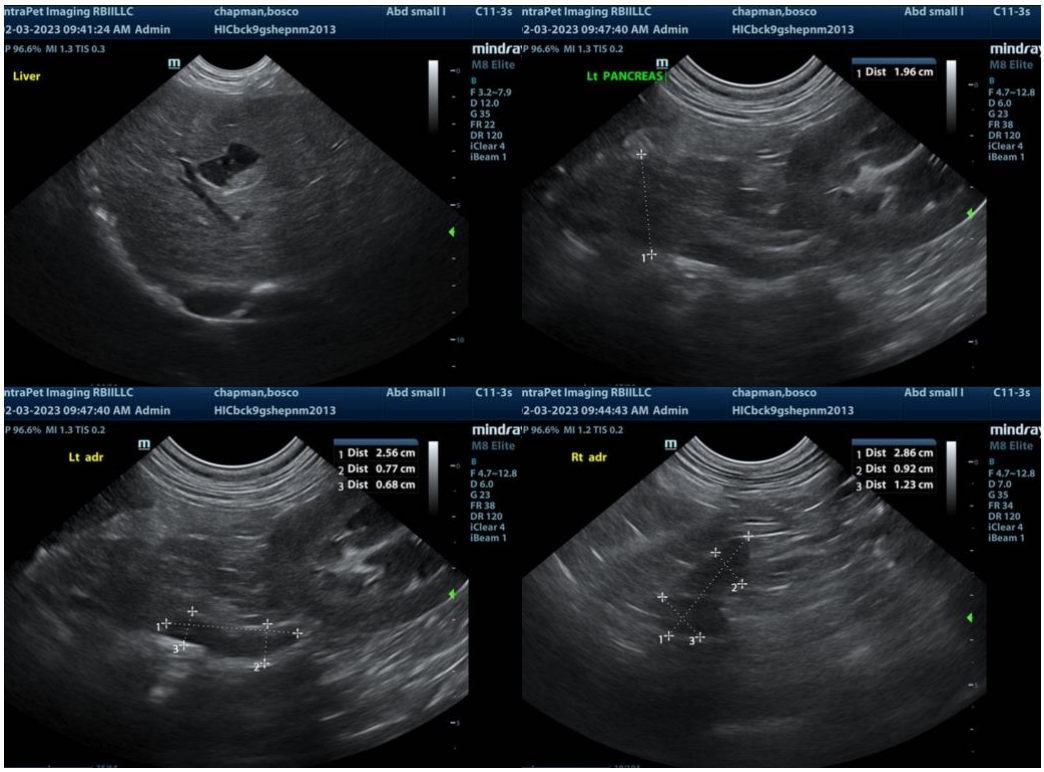

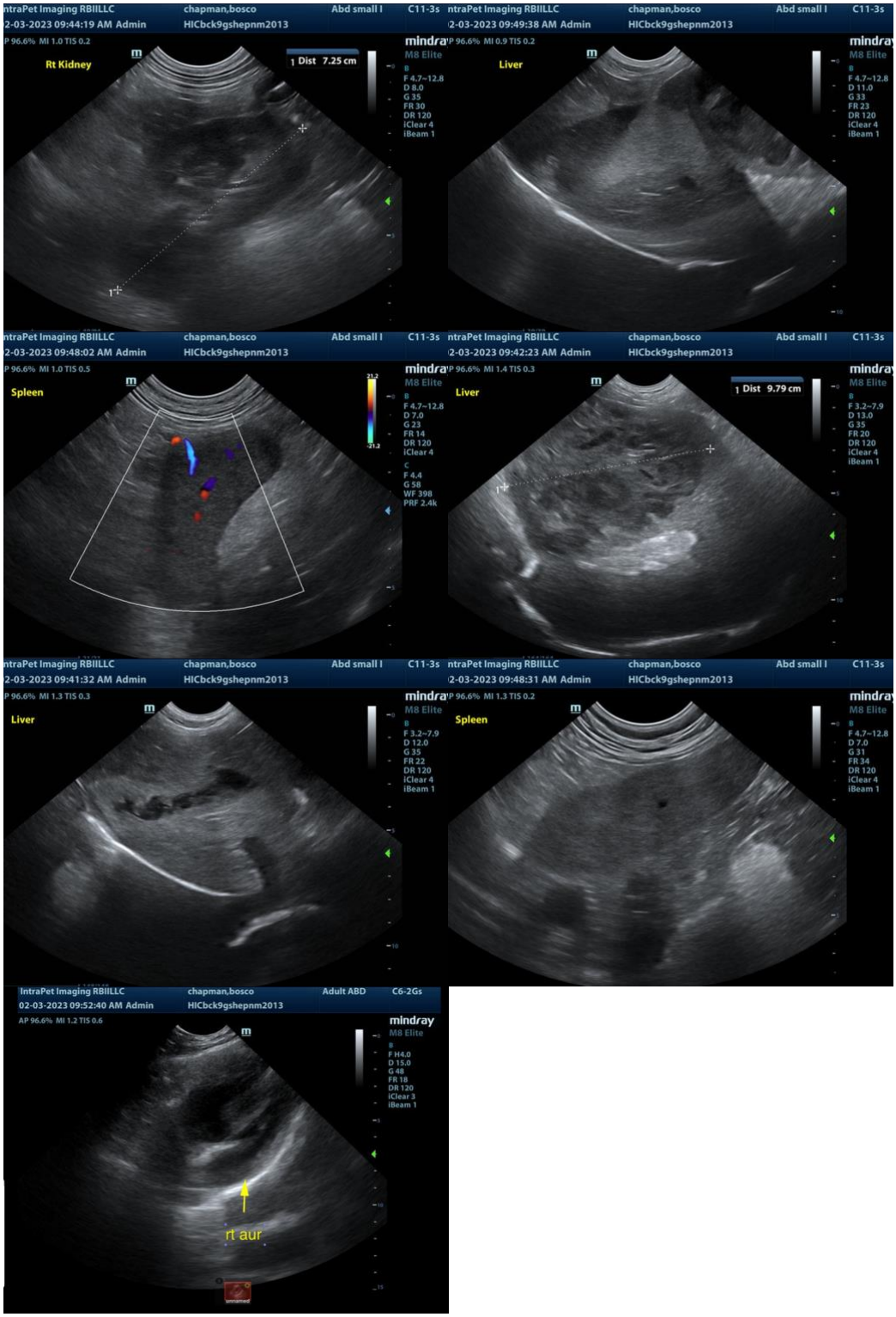

The information and recommendations provided are based on the images presented by the

referring veterinarian. No evaluation can be communicated regarding pathology that was not visible in the image/video clips provided.

Thank you for this referral. If the clinical or image interpretation does not parallel your findings or if I can be of any further assistance please contact me.

Eric Lindquist, DMV, DABVP, Cert. IVUSS, CEO of SonoPath.com
info@SonoPath.com