

**DATE**

2/3/22

PRESENTING CLINICAL SIGNS

History: Urinating blood with no signs of UTI on urinalysis, only blood and epithelial cells seen. Radiographs completed with no signs of stones.

Date of Previous IntraPet Ultrasound: No previous IntraPet scans.

Sedation: Not required to complete full diagnostic ultrasound.

Stat Report: Not requested.

Imaging Performed By: Rachel Brillhart, RDMS.

PATIENT

Rascak Mummey

SPECIES

Canine

ULTRASONOGRAPHIC EXAMINATION OF THE ABDOMEN**Urinary System**

The **urinary bladder** revealed an extensive, undifferentiated, hypoechoic mass that extended 4.67 x 2.16 cm into the cystourethral junction and occupied the trigone and obstructing the right ureter at 0.73 cm.

BREED

Beagle Mix

The prostate was at the upper limits of normal and measured 0.97 cm.

SEX

Neutered male

The **kidneys** revealed normal size and structure, corticomedullary definition and ratio for this age. The cortices presented largely uniform texture with normal echogenic relationship to liver and spleen. Medullary structure differed distinctly from the cortex. The capsules were acceptably uniform without significant irregularities. The right kidney revealed moderate hydronephrosis and hydroureter. Inflammation was noted around the right kidney owing to hydronephrosis and secondary inflammation. The left kidney measured 6.0 cm.

AGE

1/6/15

WEIGHT

36 lbs

Adrenal Glands

Both **adrenal glands** were visualized and recognized as having normal shape, size, position and echogenicity for this breed. The phrenic vasculature, glandular echogenicity and detail were unremarkable. Capsule, cortex, and medullary definition were normal for this age patient. The left adrenal gland was normal and measured 2.39 x 0.73 cm at the cranial pole and 0.73 cm at the caudal pole.

INTERPRETED BY

Eric Lindquist, DMV
DABVP, Cert. IVUSS

Spleen

The **spleen** presented a smooth homogeneous parenchyma hyperechoic to liver and renal cortical parenchyma. The capsule was smooth without noticeable expansion or deviation from within the spleen or adjacent pathology. The splenic vasculature demonstrated normal volume without signs of congestion or thrombosis. No sonographic evidence of acute or chronic inflammatory, neoplastic, or infarctual changes was noted.

HOSPITAL NAME

Animal Hospital at
Southgate

REFERRING VET

Dr. Alexander

Liver

The **liver** images submitted revealed subjectively normal liver size, contour, and structure. Parenchymal echogenicity was naturally coarse and hypoechoic to the spleen. Vascular and biliary tracts were of normal volume with no evidence of congestion. The gallbladder presented acceptably thin walls with primarily anechoic content. The cystic and common bile ducts were normal. No pathological hepatic lymphadenopathy was evident. No overt structural evidence of inflammatory, infiltrative or regenerative pathology was evident.

INVOICE

95801

Gastrointestinal

Examination of the **gastrointestinal tract** revealed a stomach and intestine free of stasis, of normal wall thickness, acceptable curvilinear mural detail, and peristaltic activity. Small and large intestine demonstrated normal luminal chyme and stool consistency respectively. No obstructive or overt infiltrative disease was noted. No associated abnormal lymphatic activity was noted.

Pancreas

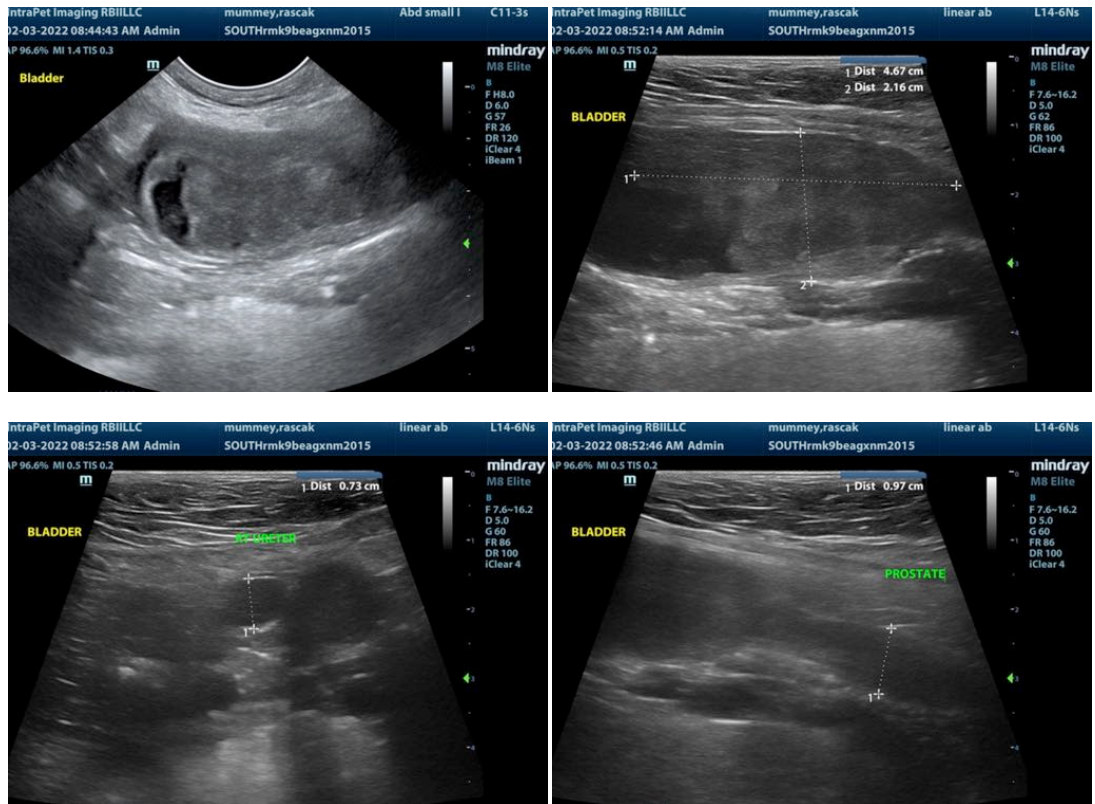
The base and limbs of the **pancreas** were observed to be largely isoechoic to surrounding omental fat. Pancreatic duct and capsular contour were acceptably normal and parenchyma respected normal curvilinear patterns. No overt evidence of active inflammatory or neoplastic disease was noted.

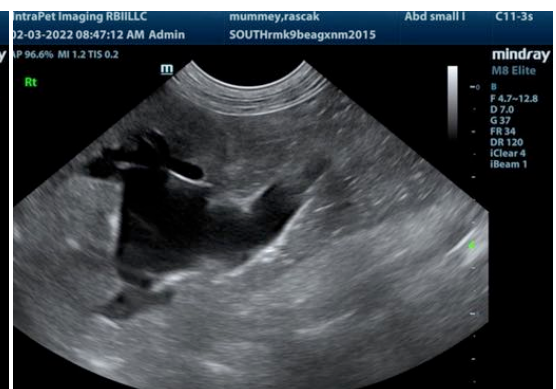
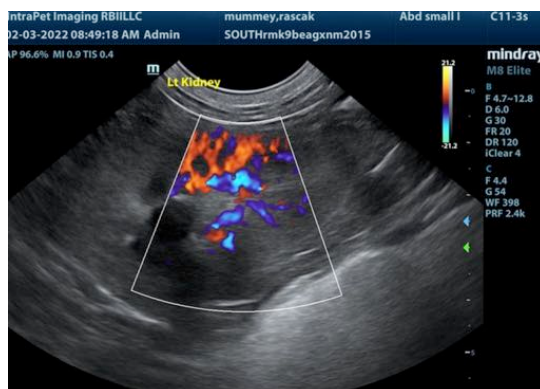
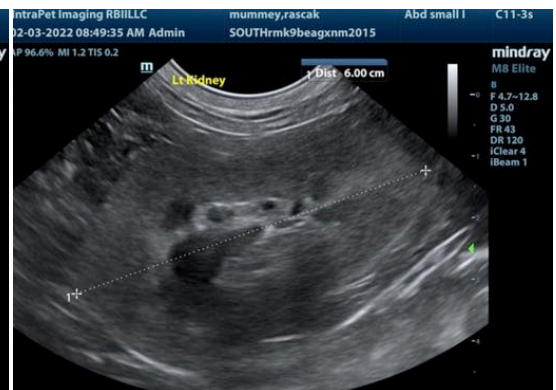
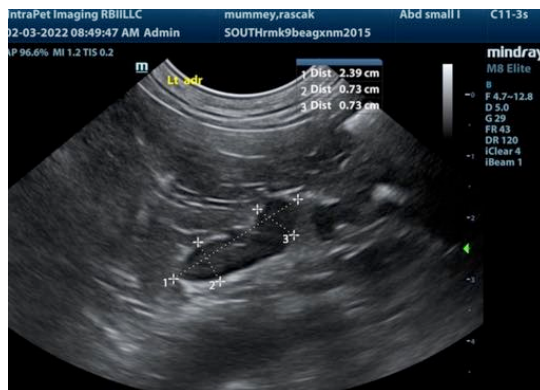
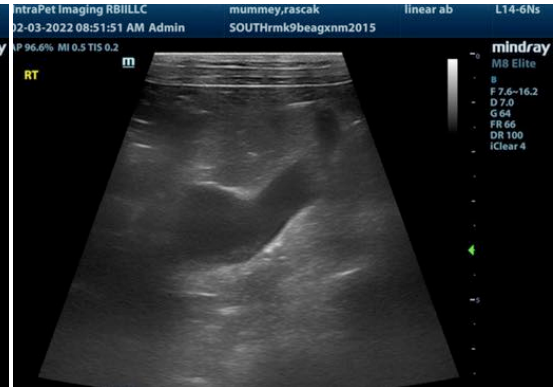
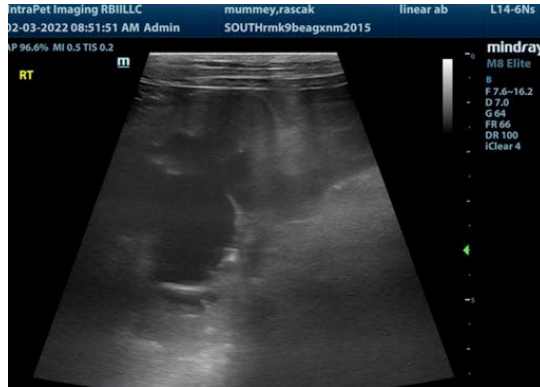
ULTRASONOGRAPHIC FINDINGS

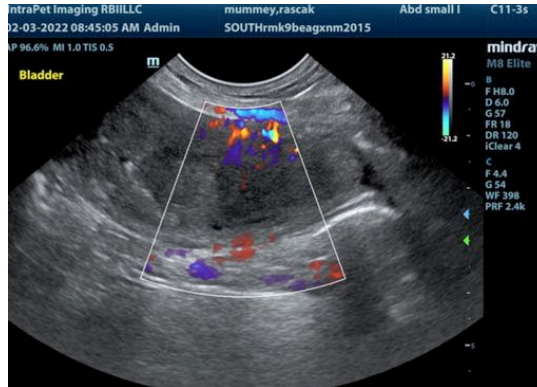
Non-resectable bladder mass with right hydroureter.

INTERPRETATION OF THE FINDINGS & FURTHER RECOMMENDATIONS

The bladder mass involve the trigone, cystourethral junction and proximal urethra. Referral for ureteral and urethral stent placement is recommended at interventional radiology followed by chemotherapy. The changes are consistent with transitional cell carcinoma. There was no evidence of organ metastasis. Chest radiographs are warranted as well.







The information and recommendations provided are based on the images presented by the referring veterinarian. No evaluation can be communicated regarding pathology that was not visible in the image/video clips provided.

Thank you for this referral. If the clinical or image interpretation does not parallel your findings or if I can be of any further assistance please contact me.

Eric Lindquist, DMV, DABVP, Cert. IVUSS, CEO of SonoPath.com
Eric.Lindquist@SonoPath.com