

**DATE**

2/3/22

PRESENTING CLINICAL SIGNS

History: Chronic vomiting. O not great about following up. Pet has been intermittently on and off pred after previously declining AUS. Last given 1/21/22. Was on 1.5 mg q 48 hrs. BW 10/21 showed mature neutrophilia. Has had "stomach issues" since 2019. Gradual weight loss
Current Medications: Pred 1.5 mg q 48 hrs discontinued 1/21/22 in preparation for US.

PATIENT

Oliver Reusing

Lab Results: BW 10/21 revealed mature neutrophilia.

Radiographs: Owner declines rads.

SPECIES

Feline

Date of Previous IntraPet Ultrasound: No previous IntraPet scans.

Sedation: Not required to complete full diagnostic ultrasound.

Stat Report: Not requested.

Imaging Performed By: Rachel Brillhart, RDMS.

BREED

Domestic Shorthair

ULTRASONOGRAPHIC EXAMINATION OF THE ABDOMEN**Urinary System**

The **urinary bladder**, trigone, and pelvic urethra presented normal thicknesses and normal tone. The ureters were not visible which is normal. No uroliths or sediment were visualized and anechoic urine was present. No evidence of inflammatory or neoplastic changes was noted. Ureteral papillae were normal.

SEX

Neutered male

AGE

8/16/06

The **kidneys** revealed largely normal size and structure, corticomedullary definition and ratio (cortex 1/3 of medulla) were essentially maintained with some age-related loss of curvilinear patterns regarding the capsule and C/M junction. The cortices presented largely uniform texture with some increased echogenicity expected for this age patient. Medullary structure differed distinctly from that of the cortex and no evidence of pelvic dilation was present. The right kidney measured 4.14 cm. The left kidney measured 3.65 cm.

WEIGHT

9.75 lbs

Adrenal Glands

Both **adrenal glands** were visualized and recognized as having normal shape, size, position and echogenicity for this breed. The phrenic vasculature, glandular echogenicity and detail were unremarkable. Capsule, cortex, and medullary definition were normal for this age patient. The left adrenal gland measured 0.55 cm.

INTERPRETED BYEric Lindquist, DMV
DABVP, Cert. IVUSS**Spleen**

The **spleen** presented a smooth homogeneous parenchyma hyperechoic to liver and renal cortical parenchyma. The capsule was smooth without noticeable expansion or deviation from within the spleen or adjacent pathology. The splenic vasculature demonstrated normal volume without signs of congestion or thrombosis. No sonographic evidence of acute or chronic inflammatory, neoplastic, or infarctual changes was noted.

HOSPITAL NAME

Alexander AH

REFERRING VET

Dr. Alexander

Liver

The **liver** images submitted revealed subjectively normal liver size, contour, and structure. Parenchymal echogenicity was naturally coarse and hypoechoic to the spleen. Vascular and biliary tracts were of normal volume with no evidence of congestion. The gallbladder presented acceptably thin walls with primarily anechoic content. The cystic and common bile ducts were normal. No pathological hepatic lymphadenopathy was evident. No overt structural evidence of inflammatory, infiltrative or regenerative pathology was evident.

INVOICE

95796

Gastrointestinal

The stomach revealed a minor amount of chyme and fluid. Minor distal small intestine revealed excessive thicknesses. There were minor areas of early detail loss present. There were variable areas of stasis noted. The mesenteric lymph nodes are reactive and measured 1.0 x 0.5 cm. Epigastric lymph nodes are slightly enlarged, reactive and measured 1.12 x 0.6 cm.

Pancreas

The **pancreas** was enlarged, hypoechoic with a dilated duct. The pancreas measured up to 1.0 cm in width. There is no evidence of active inflammation.

ULTRASONOGRAPHIC FINDINGS

Irritable bowel. Minor jejunal thickening.

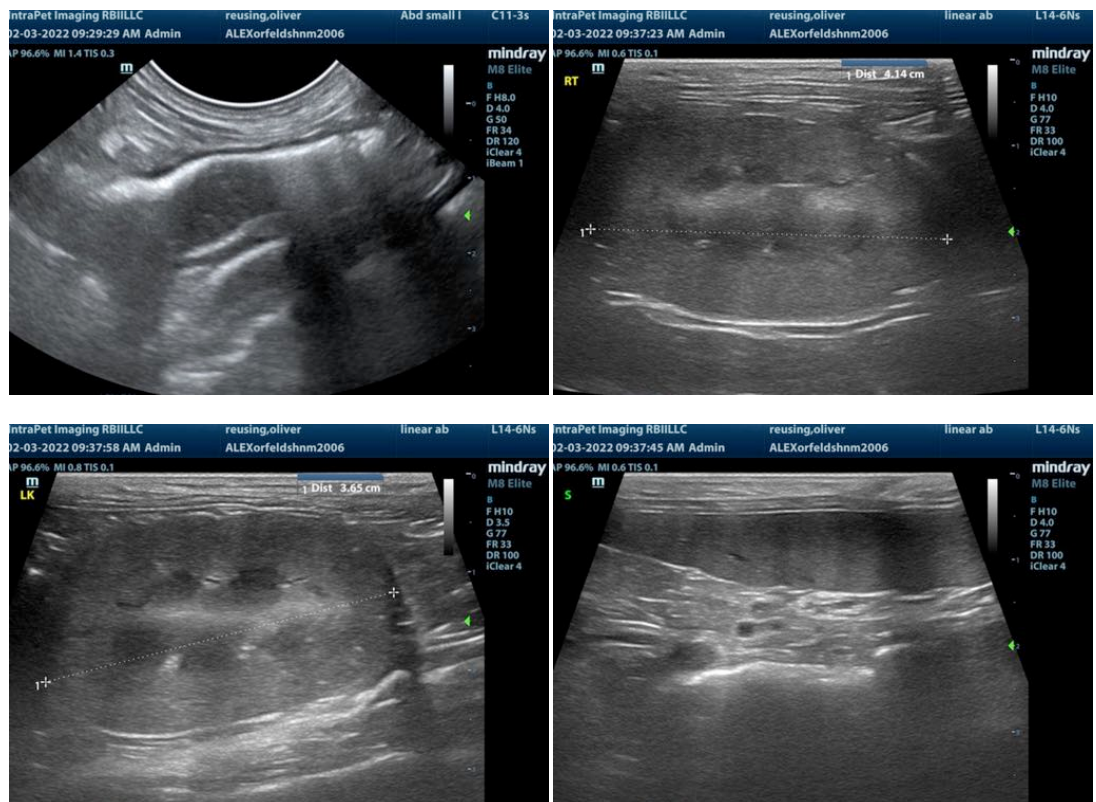
Variable intestinal stasis with minor loss of detail loss in some areas.

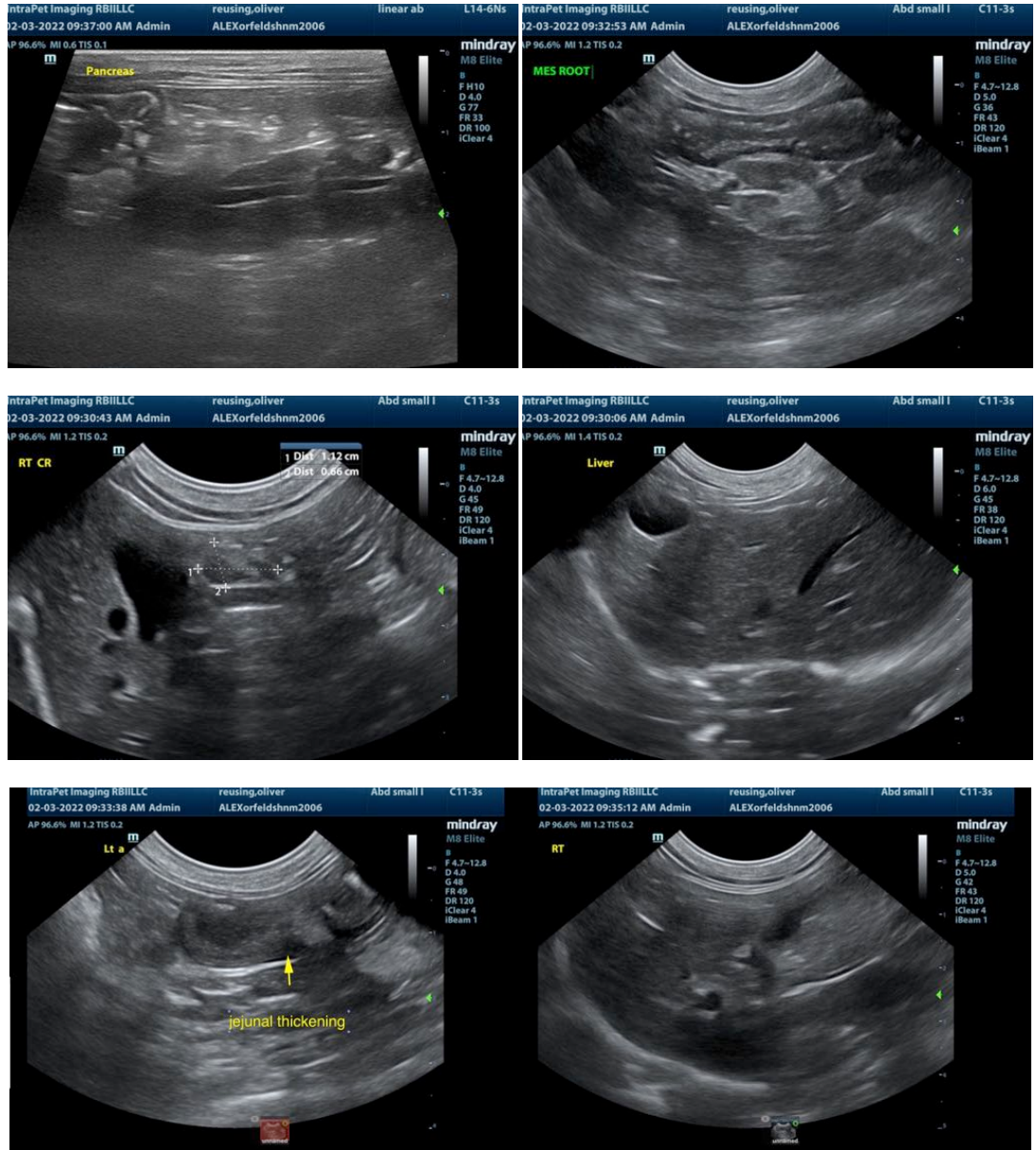
Slight mesenteric and epigastric lymphadenopathy.

Prominent pancreas, possible low grade pancreatitis.

INTERPRETATION OF THE FINDINGS & FURTHER RECOMMENDATIONS

The prednisolone may be suppressing an underlying round cell neoplasia/lymphoma. However, chronic inflammatory bowel with malassimilation and low-grade pancreatitis is also possible. Full thickness GI biopsies guided by intraoperative ultrasound would be ideal in this case. However, further evaluation of weight loss should be considered.





The information and recommendations provided are based on the images presented by the referring veterinarian. No evaluation can be communicated regarding pathology that was not visible in the image/video clips provided.

Thank you for this referral. If the clinical or image interpretation does not parallel your findings or if I can be of any further assistance please contact me.

Eric Lindquist, DMV, DABVP, Cert. IVUSS, CEO of SonoPath.com
 Eric.Lindquist@SonoPath.com