



PATIENT

Murphy Crandall

SPECIES

Canine

BREED

Pitbull Mix

SEX

Spayed Female

AGE

9 Yrs 6 Mos

WEIGHT

44 lbs

INTERPRETED BY

Eric Lindquist, DMV
DABVP, Cert IVUSS

**IMAGING
PERFORMED BY**

Denise Bruno, LVT,
RDMS

HOSPITAL NAME

Brooklyn Heights VH

REFERRING VET

Dr. Venezia

INVOICE

95821

DATE

02/03/22

PRESENTING CLINICAL SIGNS

History: persistent Proteinuria, hypertension.

Kidney values are normal as of right now.

Evaluate for lesions, tumor, infection, inflammation regarding kidneys, liver, etc.

Labs attached

ULTRASONOGRAPHIC EXAMINATION OF THE ABDOMEN

Urinary System

The **urinary bladder**, trigone, and pelvic urethra presented normal thicknesses and normal tone. The ureters were not visible which is normal. No uroliths or sediment were visualized and anechoic urine was present. No evidence of inflammatory or neoplastic changes was noted. Ureteral papillae were normal.

The **kidneys** were normal in size and contour with slightly increased cortical echogenicity. Blood flow to the kidneys was normal on color flow assessment. The right kidney measured 6.75 cm. The left kidney measured 5.76 cm.

Adrenal Glands

Both **adrenal glands** were visualized and recognized as having normal shape, size, position and echogenicity for this breed. The phrenic vasculature, glandular echogenicity and detail were unremarkable. Capsule, cortex, and medullary definition were normal for this age patient. The right adrenal gland measured 3.05 x 0.75 cm at the caudal pole and 0.93 cm at the cranial pole. The left adrenal gland measured 2.4 x 0.56 cm at the caudal pole and 0.47 cm at the cranial pole.

Spleen

The **spleen** presented a smooth homogeneous parenchyma hyperechoic to liver and renal cortical parenchyma. The capsule was smooth without noticeable expansion or deviation from within the spleen or adjacent pathology. The splenic vasculature demonstrated normal volume without signs of congestion or thrombosis. No sonographic evidence of acute or chronic inflammatory, neoplastic, or infarctual changes was noted.

Liver

The **liver** images submitted revealed subjectively normal liver size, contour, and structure. Parenchymal echogenicity was naturally coarse and hypoechoic to the spleen. Vascular and biliary tracts were of normal volume with no evidence of congestion. The gallbladder presented acceptably thin walls with primarily anechoic content. The cystic and common bile ducts were normal. No pathological hepatic lymphadenopathy was evident. No overt structural evidence of inflammatory, infiltrative or regenerative pathology was evident.



PATIENT

Murphy Crandall

SPECIES

Canine

BREED

Pitbull Mix

SEX

Spayed Female

AGE

9 Yrs 6 Mos

WEIGHT

44 lbs

INTERPRETED BY

Eric Lindquist, DMV
DABVP, Cert IVUSS

IMAGING PERFORMED BY

Denise Bruno, LVT,
RDMS

HOSPITAL NAME

Brooklyn Heights VH

REFERRING VET

Dr. Venezia

INVOICE

95821

DATE

02/03/22

Gastrointestinal

Examination of the **gastrointestinal tract** revealed a stomach and intestine free of stasis, of normal wall thickness, acceptable curvilinear mural detail, and peristaltic activity. Small and large intestine demonstrated normal luminal chyme and stool consistency respectively. No obstructive or overt infiltrative disease was noted. No associated abnormal lymphatic activity was noted.

Pancreas

The base and limbs of the **pancreas** were observed to be largely isoechoic to surrounding omental fat. Pancreatic duct and capsular contour were acceptably normal and parenchyma respected normal curvilinear patterns. No overt evidence of active inflammatory or neoplastic disease was noted.

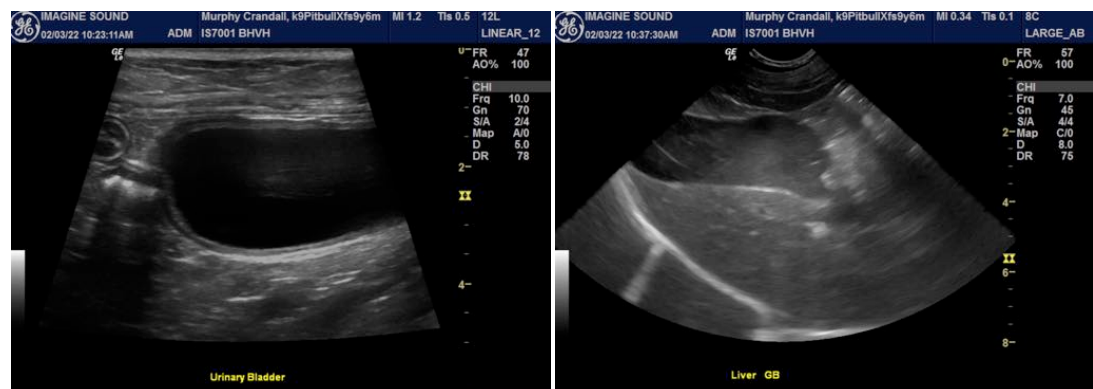
ULTRASONOGRAPHIC FINDINGS

Structurally unremarkable abdomen.

Minor degenerative renal changes, expected for this age patient.

INTERPRETATION OF THE FINDINGS & FURTHER RECOMMENDATIONS

Doxycycline trial should be considered as well as tick borne disease panel if not already performed to rule out and empirically treat underlying disease. Blood pressure measurements are warranted. There was no evidence of significant visceral disease.





PATIENT

Murphy Crandall

SPECIES

Canine

BREED

Pitbull Mix

SEX

Spayed Female

AGE

9 Yrs 6 Mos

WEIGHT

44 lbs

INTERPRETED BY

Eric Lindquist, DMV
DABVP, Cert IVUSS

IMAGING PERFORMED BY

Denise Bruno, LVT,
RDMS

HOSPITAL NAME

Brooklyn Heights VH

REFERRING VET

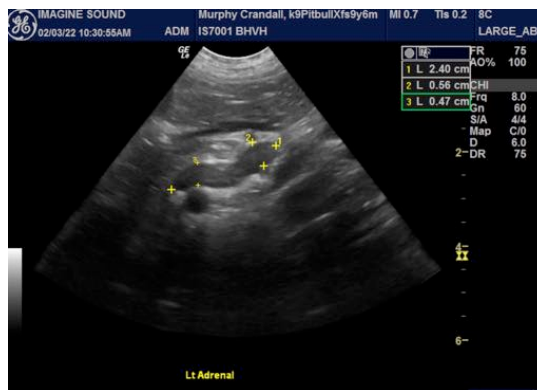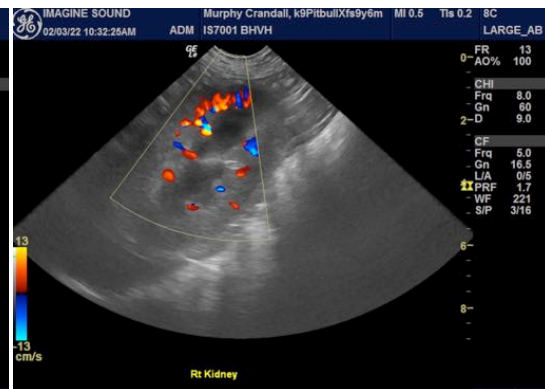
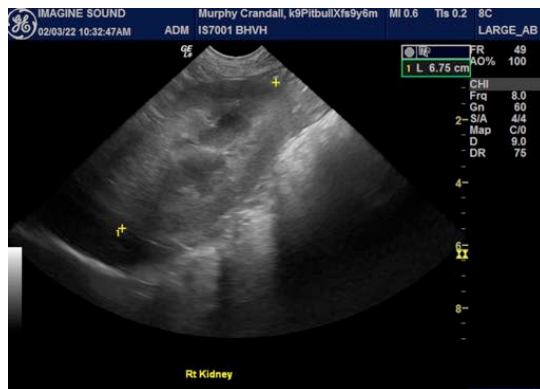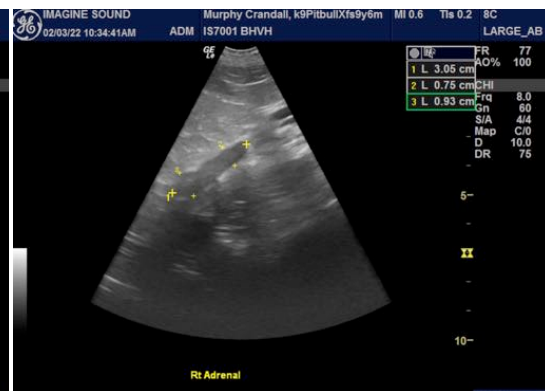
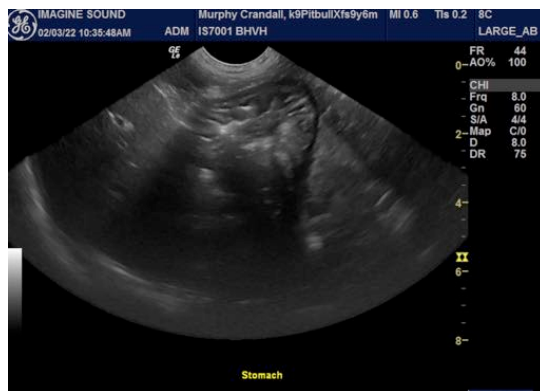
Dr. Venezia

INVOICE

95821

DATE

02/03/22



The information and recommendations provided are based on the images presented by the referring veterinarian. No evaluation can be communicated regarding pathology that was not visible in the image/video clips provided.

Thank you for this referral. If the clinical or image interpretation does not parallel your findings or if I can be of any further assistance please contact me.

Eric Lindquist, DMV, DABVP, Cert. IVUSS, CEO of SonoPath.com
Eric.Lindquist@SonoPath.com