



**PATIENT**

Flip Williams

**SPECIES**

Canine

**BREED**

Shiba Inu

**SEX**

Neutered male

**AGE**

17 years

**WEIGHT**

16 lbs

**INTERPRETED BY**

Eric Lindquist, DMV  
DABVP, Cert. IVUSS

**IMAGING PERFORMED BY**

Dr. Rodriguez

**HOSPITAL NAME**

Foxfield VS

**REFERRING VET**

Dr. Rodriguez

**INVOICE**

95793

**DATE**

2/1/22

**PRESENTING CLINICAL SIGNS**

Chronic cough. DDx heart vs respiratory. Prev vet placed on enalapril, lasix and tem-p. VHS 11. Abnormal PE/Chem/CBC/UA Results: BUN 28, TP: 9.2, Alb: 4.5, Glob: 4.7, RBC: 5.3, HCT: 33.8, WBC: 16.85

**ULTRASONOGRAPHIC EXAMINATION OF THE ABDOMEN**

**Urinary System**

The **urinary bladder**, trigone, and pelvic urethra presented normal thicknesses and normal tone. The ureters were not visible which is normal. No uroliths or sediment were visualized and anechoic urine was present. No evidence of inflammatory or neoplastic changes was noted. Ureteral papillae were normal.

The **kidneys** revealed largely normal size and structure, corticomedullary definition and ratio (cortex 1/3 of medulla) were essentially maintained with some age-related loss of curvilinear patterns regarding the capsule and C/M junction. The cortices presented largely uniform texture with some increased echogenicity expected for this age patient. Medullary structure differed distinctly from that of the cortex and no evidence of pelvic dilation was present. Corticomedullary calculi were noted and non-obstructive. The right kidney measured 4.54 cm. The left kidney measured 4.61 cm with anechoic cysts that measured 0.5 cm at the cranial pole.

**Adrenal Glands**

Both **adrenal glands** were visualized and recognized as having largely normal shape, size, position and acceptable echogenicity for this age group and breed. Some heterogeneity was noted within the adrenal parenchyma without concerning capsular distortion. These changes are likely age related but should be monitored by sonogram should the patient be suspected of having adrenal disease. The right adrenal gland measured 1.95 x 0.61 cm. The left adrenal gland measured 2.0 x 0.56 cm.

**Spleen**

The **spleen** presented a smooth homogeneous parenchyma hyperechoic to liver and renal cortical parenchyma. The capsule was smooth without noticeable expansion or deviation from within the spleen or adjacent pathology. The splenic vasculature demonstrated normal volume without signs of congestion or thrombosis. No sonographic evidence of acute or chronic inflammatory, neoplastic, or infarctual changes was noted.

**Liver**

The **liver** was uniformly swollen with minor, excessive gallbladder debris and over distension with dependent and suspended bile without evidence of overt mucocele formation. However, excessive sludge was present. The liver presented coarse architecture with mildly increased portal markings and subtle, mixed echogenic changes. This is consistent with vacuolar hepatopathy and some level of remodeling and history of inflammatory component. There was no overt suspicion of neoplasia.



**PATIENT**

Flip Williams

**Gastrointestinal**

**SPECIES**

Canine

Examination of the **gastrointestinal tract** revealed a stomach and intestine free of stasis, of normal wall thickness, acceptable curvilinear mural detail, and peristaltic activity. Minor retention of ingesta in the stomach. Small and large intestine demonstrated normal luminal chyme and stool consistency respectively. No obstructive or overt infiltrative disease was noted. No associated abnormal lymphatic activity was noted.

**BREED**

Shiba Inu

**Pancreas**

**SEX**

Neutered male

The base and limbs of the **pancreas** were observed to be largely isoechoic to surrounding omental fat. Pancreatic duct and capsular contour were acceptably normal and parenchyma respected normal curvilinear patterns. No overt evidence of active inflammatory or neoplastic disease was noted.

**AGE**

17 years

**ULTRASONOGRAPHIC EXAMINATION OF THE HEART**

**WEIGHT**

16 lbs

The echocardiogram in this patient demonstrated enlarged **left atrial** size based on 3 different LA measurement methods. Chamber volumes and echogenicity were normal. The cranial and caudal **mitral** valve leaflets presented vegetative thickening consistent with endocardiosis. Prolapse of the anterior mitral valve leaflet was noted. Doppler indicated measurable insufficiency. The **left ventricle** presented thicknesses with linear contour and was not dilated nor restricted. The **myocardium** presented normal echogenicity without subjective evidence of significant fibrotic or ischemic disease. **Contractility** of the ventricular walls was adequate and in normal range for this patient evidenced by the fractional shortening measurement and subjective evaluation of the different regions of the myocardium. The **left ventricular outflow** tract demonstrated normal laminar flow and subjective structural integrity. The **right atrium** and auricle revealed normal size, structure and content. No evidence of masses was noted or chamber overload. **Tricuspid** valvular assessment demonstrated adequate linear morphology. The **right ventricle** was of normal size (1/3 diameter of LV), chordae structure, myocardial echogenicity and thickness. **Pulmonic** tract assessment revealed normal valve structure, laminar flow, and diameter (approx. 1:1 pa/ao ratio). No visible **pericardial** or free pleura fluid was noted. No echographically detectable evidence of infiltrative disease was visible. The cranial **mediastinum and pericardial regions** were free of masses in the visible window.

**INTERPRETED BY**

Eric Lindquist, DMV  
DABVP, Cert. IVUSS

**IMAGING PERFORMED BY**

Dr. Rodriguez

**HOSPITAL NAME**

Foxfield VS

**REFERRING VET**

Dr. Rodriguez

**INVOICE**

95793

**DATE**

2/1/22



**PATIENT**

Flip Williams

**SPECIES**

Canine

**BREED**

Shiba Inu

**SEX**

Neutered male

**AGE**

17 years

CANINE CARDIAC PARAMETERS	MR VMAX (m/s)	TR VMAX (m/s)	LA/AO (Boon method)	LA/AO (Heart Base; Swe)	FS (%)	EF (%)	EPSS (cm)
NORMAL PARAMETER	4.5-5.5	<2.7	1.3	<1.6	28-40	40-100	<0.6
PATIENT		2.5	1.3	1.8	68	95	NM
CANINE CARDIAC PARAMETERS	HR (BPM)	AV VMAX (m/s)	PV MAX (m/s)	BODY WEIGHT	LA 2D short axis Base view (cm)	LVIDd Avg; 2D and m- mode short axis (cm)	LVIDs Avg; 2D and m- mode short axis (cm)
NORMAL PARAMETER	50-100	0.7-1.7	0.7-1.6				
PATIENT			1.1	16 lbs	3.5	2.73	

**WEIGHT**

16 lbs

**ULTRASONOGRAPHIC FINDINGS**

Stage B2 valvular disease.

**INTERPRETED BY**

Eric Lindquist, DMV  
DABVP, Cert. IVUSS

Mitral insufficiency and mild left atrial enlargement.

Moderate degenerative renal changes with non-obstructive calculi.

Benign hepatopathy.

**IMAGING  
PERFORMED BY**

Dr. Rodriguez

Minor, excessive gallbladder debris.

Anechoic cortical left renal cyst.

**HOSPITAL NAME**

Foxfield VS

**INTERPRETATION OF THE FINDINGS & FURTHER RECOMMENDATIONS**

Blood pressure measurements are recommended. Ursodiol therapy can be considered as a preventative. Regarding the cardiac presentation blood pressure measurements are warranted if not already performed. The cough may be owing to left atrial enlargement and mainstem bronchus impingement. Assessment of radiographs are recommended. I recommend continuation of Lasix, Enalapril and add Pimobendan at 0.3 mg/kg b.i.d. Geriatric diet is warranted. Urinary work up is recommended if not already performed. The kidneys appear 50% compromised.

**REFERRING VET**

Dr. Rodriguez

**INVOICE**

95793

**DATE**

2/1/22



**PATIENT**

Flip Williams

**SPECIES**

Canine

**BREED**

Shiba Inu

**SEX**

Neutered male

**AGE**

17 years

**WEIGHT**

16 lbs

**INTERPRETED BY**

Eric Lindquist, DMV  
DABVP, Cert. IVUS

**IMAGING PERFORMED BY**

Dr. Rodriguez

**HOSPITAL NAME**

Foxfield VS

**REFERRING VET**

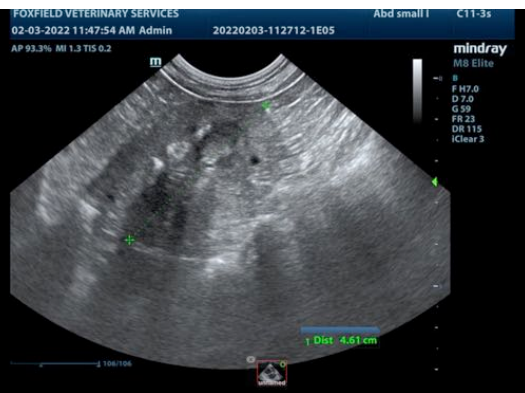
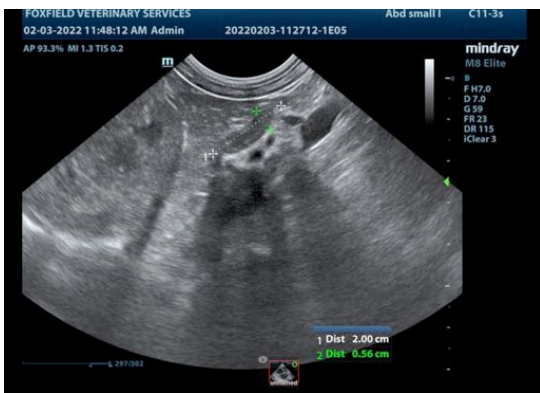
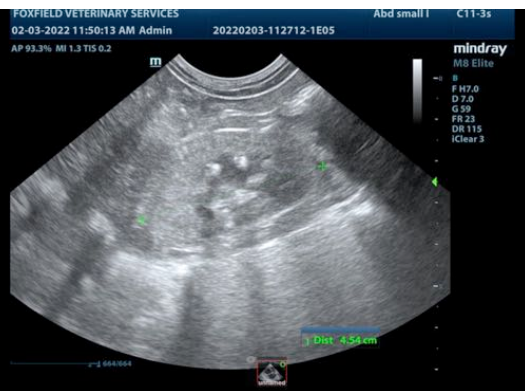
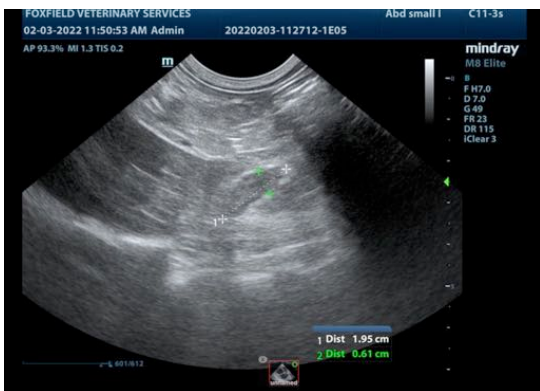
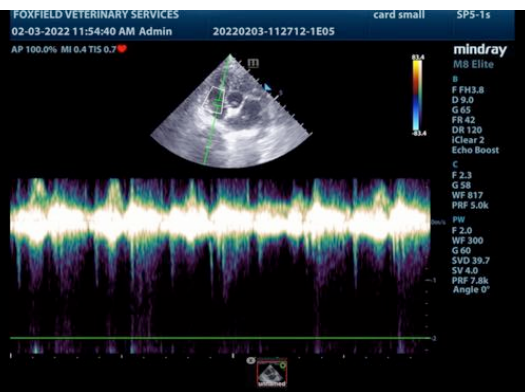
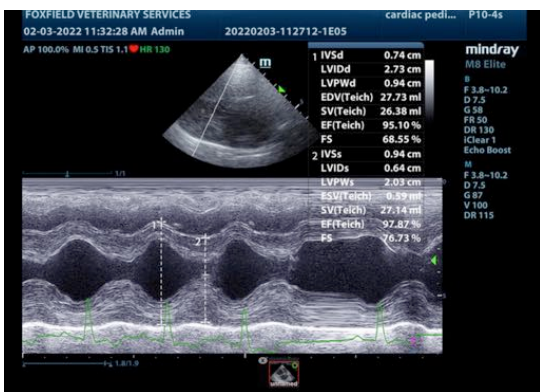
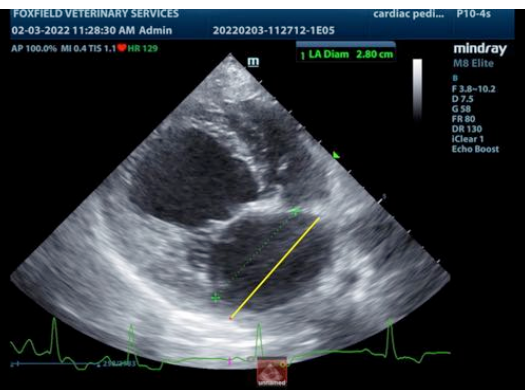
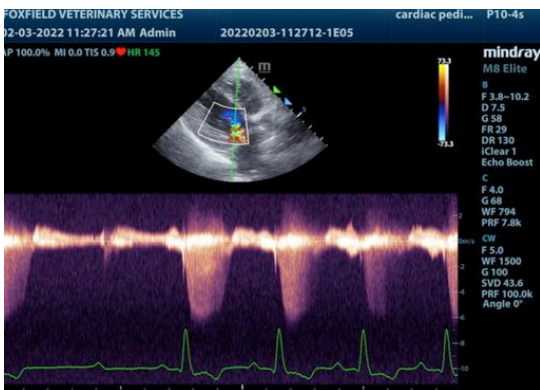
Dr. Rodriguez

**INVOICE**

95793

**DATE**

2/1/22





**PATIENT**

Flip Williams

**SPECIES**

Canine

**BREED**

Shiba Inu

**SEX**

Neutered male

**AGE**

17 years

**WEIGHT**

16 lbs

**INTERPRETED BY**

Eric Lindquist, DMV  
DABVP, Cert. IVUS

**IMAGING PERFORMED BY**

Dr. Rodriguez

**HOSPITAL NAME**

Foxfield VS

**REFERRING VET**

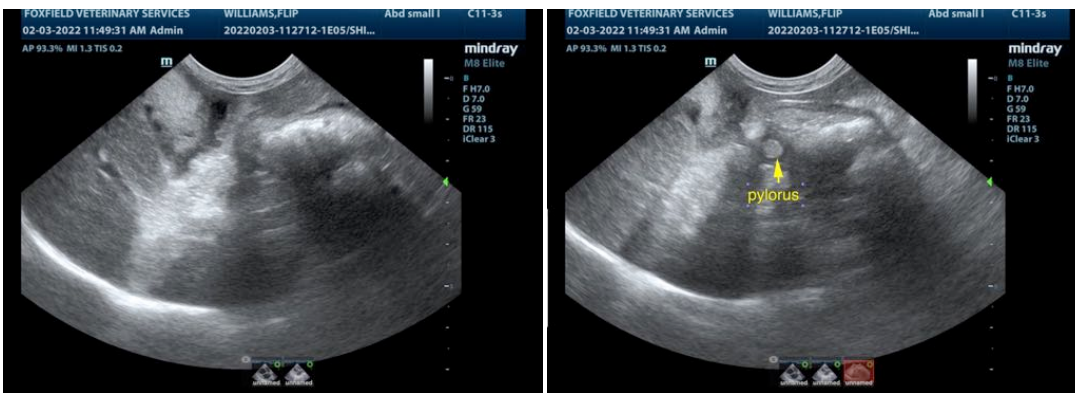
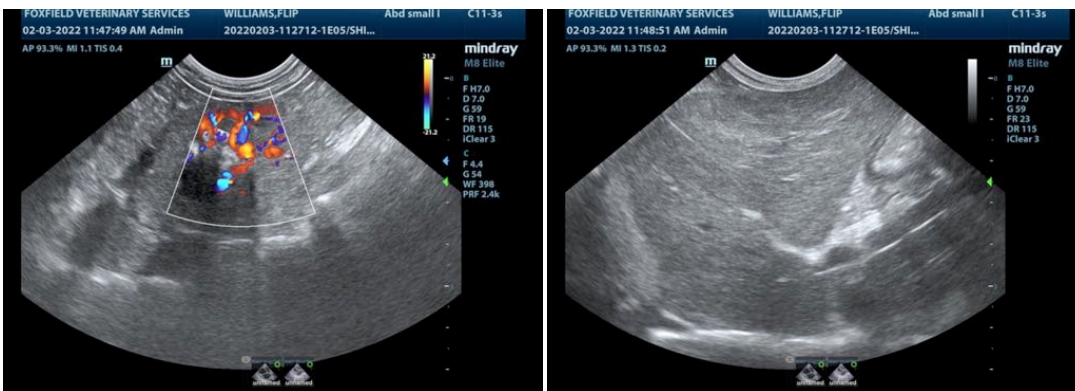
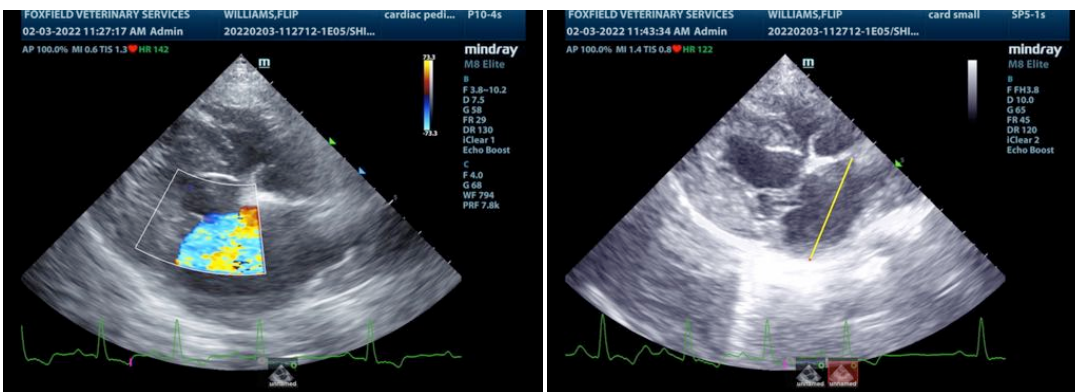
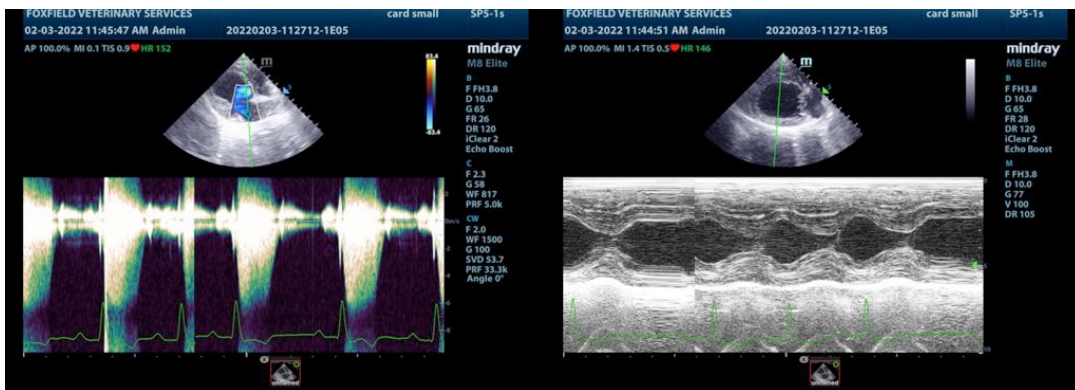
Dr. Rodriguez

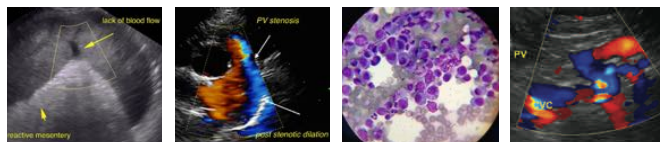
**INVOICE**

95793

**DATE**

2/1/22





**PATIENT**

Flip Williams

The information and recommendations provided are based on the images presented by the referring veterinarian/sonographer. No evaluation can be communicated regarding pathology that was not visible in the image/video clips provided.

**SPECIES**

Canine

Thank you for this referral. If the clinical or image interpretation does not parallel your findings or if I can be of any further assistance please contact me.

**BREED**

Shiba Inu

**Eric Lindquist**, DMV, DABVP, Cert. IVUSS, CEO of SonoPath.com  
info@SonoPath.com

**SEX**

Neutered male

**AGE**

17 years

**WEIGHT**

16 lbs

**INTERPRETED BY**

Eric Lindquist, DMV  
DABVP, Cert. IVUSS

**IMAGING  
PERFORMED BY**

Dr. Rodriguez

**HOSPITAL NAME**

Foxfield VS

**REFERRING VET**

Dr. Rodriguez

**INVOICE**

95793

**DATE**

2/1/22