



**PATIENT**

Brittany Neimi

**SPECIES**

Canine

**BREED**

Labrador

**SEX**

Spayed Female

**AGE**

11 years

**WEIGHT**

37 kg

**INTERPRETED BY**

Eric Lindquist, DMV  
DABVP, Cert. IVUSS

**IMAGING  
PERFORMED BY**

Dr. Belan

**HOSPITAL NAME**

Animal Clinic of  
Downton

**REFERRING VET**

Dr. Waldman

**INVOICE**

95824

**DATE**

2/3/22

**PRESENTING CLINICAL SIGNS**

History of hematuria. Enlarged liver and spleen seen on abdominal x rays. Patient was given short term GA for scan

**ULTRASONOGRAPHIC EXAMINATION OF THE ABDOMEN**

**Urinary System**

The **urinary bladder** and trigone presented normal thicknesses. The urethra is subjectively dilated. The ureters were not visible which is normal. No uroliths or sediment were visualized and anechoic urine was present. No evidence of inflammatory or neoplastic changes was noted. Ureteral papillae were normal.

The **kidneys** revealed normal size and structure, corticomedullary definition and ratio for this age. The cortices presented largely uniform texture with normal echogenic relationship to liver and spleen. Medullary structure differed distinctly from the cortex and no evidence of pelvic dilation was present. The capsules were acceptably uniform without significant irregularities. The left kidney measured 5.82 cm. The right kidney measured 6.3 cm.

**Adrenal Glands**

Both **adrenal glands** were visualized and recognized as having normal shape, size, position and echogenicity for this breed. The phrenic vasculature, glandular echogenicity and detail were unremarkable. Capsule, cortex, and medullary definition were normal for this age patient. The right adrenal gland measured 0.39 cm at the cranial pole and 0.47 cm at the caudal pole. The left adrenal gland measured 0.49 cm at the cranial pole and 0.39 cm at the caudal pole.

**Spleen**

The **spleen** in this patient was mildly enlarged with uniform parenchyma and was folded upon itself cranially. Slight coarse architecture was noted. This is expected for this age patient. This is a positional variant and is not pathological. There was no evidence of significant disease.

**Liver**

The **liver** images from right and left intercostal as well as subcostal views revealed subjectively normal liver size, contour, and structure. Some age-related parenchymal remodeling was noted but likely not clinically significant at this time. Multi-focal, hyperechoic, nodular changes were noted. The largest of which measured 2.3 cm with mild disruption of architecture in the left medial liver and a separate right-sided nodule that measured 2.3 x 0.74 cm. Vascular and biliary tracts were of normal volume and no evidence of congestion was noted. The gallbladder presented some dependent debris with essentially normal contour. The cystic and common bile ducts were normal. No overt evidence of active inflammatory, infiltrative or regenerative pathology was noted but should be paired with current or past LE elevations regarding any clinical significance to this presentation. The hepatic lymph nodes were unremarkable.



**PATIENT**

**Gastrointestinal**

Brittany Neimi

Examination of the **gastrointestinal tract** revealed a stomach and intestine free of stasis, of normal wall thickness, acceptable curvilinear mural detail, and peristaltic activity. Small and large intestine demonstrated normal luminal chyme and stool consistency respectively. No obstructive or overt infiltrative disease was noted. No associated abnormal lymphatic activity was noted.

**SPECIES**

Canine

**BREED**

Labrador

**Pancreas**

The base and limbs of the **pancreas** were observed to be largely isoechoic to surrounding omental fat. Pancreatic duct and capsular contour were acceptably normal and parenchyma respected normal curvilinear patterns. No overt evidence of active inflammatory or neoplastic disease was noted.

**SEX**

Spayed Female

**ULTRASONOGRAPHIC FINDINGS**

**AGE**

11 years

Hepatic remodeling and nodular changes. Primary concerns are pronounced nodular hyperplasia versus carcinoma.

Dilated urethra.

**WEIGHT**

37 kg

**INTERPRETATION OF THE FINDINGS & FURTHER RECOMMENDATIONS**

FNA of the liver is indicated if any weight loss is present or liver enzyme elevations are an issue. Underlying incontinence should be evaluated as well as examination of the vaginal vestibule for predisposing issue given the patient's history.

**INTERPRETED BY**

Eric Lindquist, DMV  
DABVP, Cert. IVUSS

**IMAGING PERFORMED BY**

Dr. Belan

**HOSPITAL NAME**

Animal Clinic of  
Downton

**REFERRING VET**

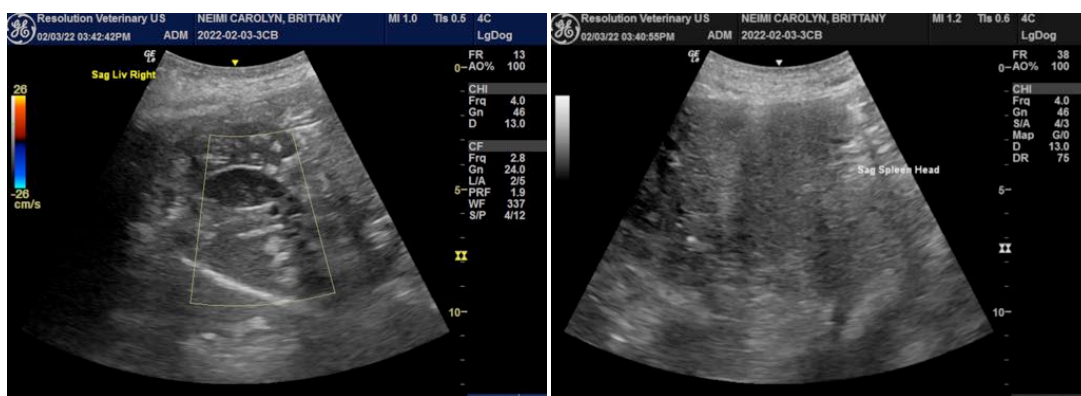
Dr. Waldman

**INVOICE**

95824

**DATE**

2/3/22





**PATIENT**

Brittany Neimi

**SPECIES**

Canine

**BREED**

Labrador

**SEX**

Spayed Female

**AGE**

11 years

**WEIGHT**

37 kg

**INTERPRETED BY**

Eric Lindquist, DMV  
DABVP, Cert. IVUS

**IMAGING PERFORMED BY**

Dr. Belan

**HOSPITAL NAME**

Animal Clinic of  
Downton

**REFERRING VET**

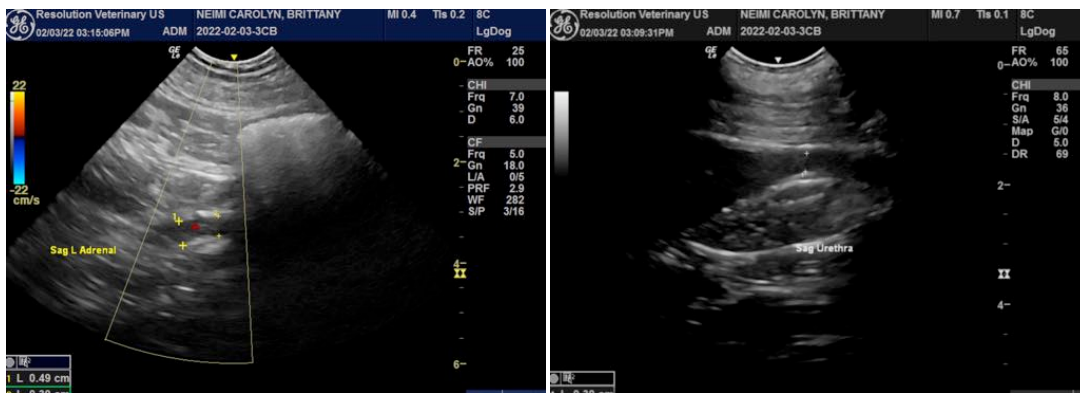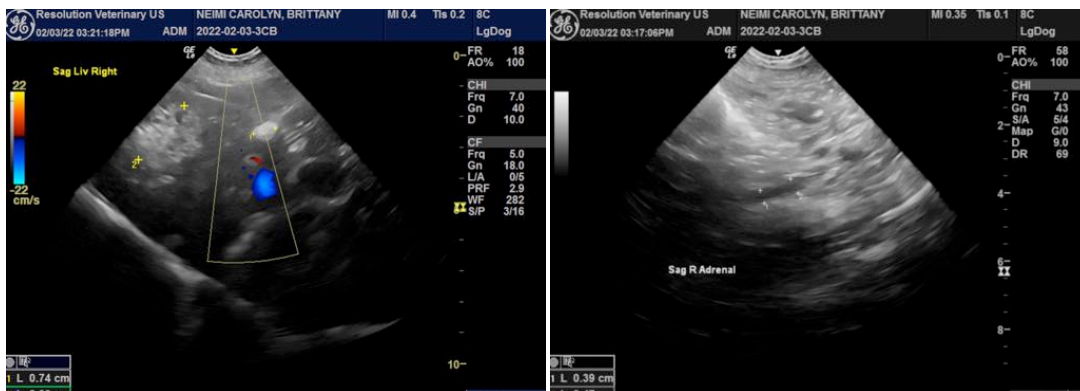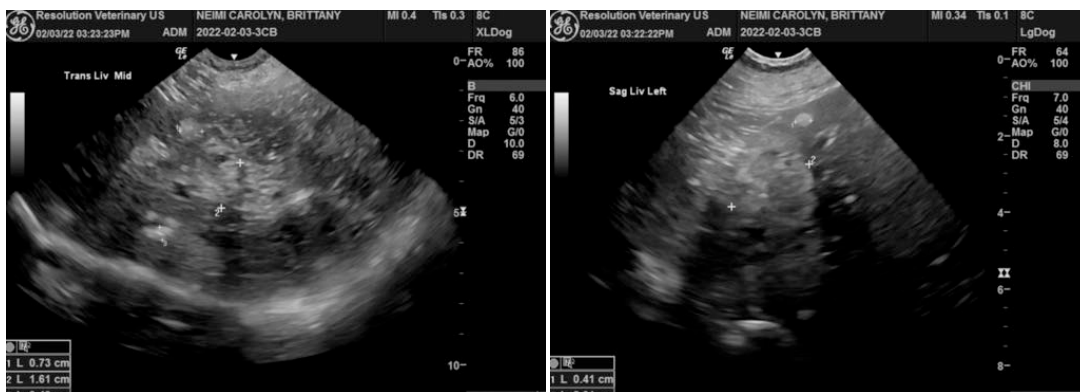
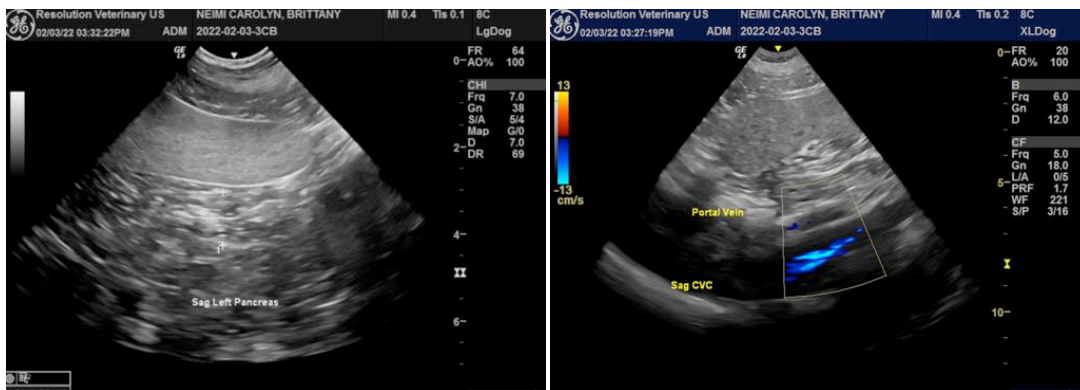
Dr. Waldman

**INVOICE**

95824

**DATE**

2/3/22





**PATIENT**

Brittany Neimi

**SPECIES**

Canine

**BREED**

Labrador

**SEX**

Spayed Female

**AGE**

11 years

**WEIGHT**

37 kg

**INTERPRETED BY**

Eric Lindquist, DMV  
DABVP, Cert. IVUSS

**IMAGING  
PERFORMED BY**

Dr. Belan

**HOSPITAL NAME**

Animal Clinic of  
Downton

**REFERRING VET**

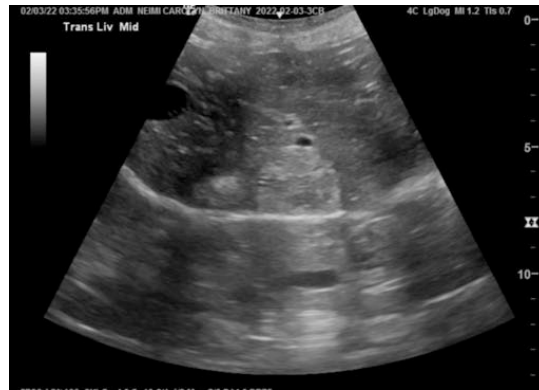Dr. Waldman

**INVOICE**

95824

**DATE**

2/3/22



The information and recommendations provided are based on the images presented by the referring veterinarian/sonographer. No evaluation can be communicated regarding pathology that was not visible in the image/video clips provided.

Thank you for this referral. If the clinical or image interpretation does not parallel your findings or if I can be of any further assistance please contact me.

**Eric Lindquist**, DMV, DABVP, Cert. IVUSS, CEO of SonoPath.com  
info@SonoPath.com