



PATIENT

Ace Crummett

SPECIES

Canine

BREED

Chihuahua

SEX

Neutered male

AGE

12 years

WEIGHT

5.6 lbs

INTERPRETED BY

Eric Lindquist, DMV
DABVP, Cert. IVUSS

**IMAGING
PERFORMED BY**

Diane McFadden, RVT

HOSPITAL NAME

Animal Care Center of
Flanders

INVOICE

95817

DATE

2/3/22

PRESENTING CLINICAL SIGNS

PU/PD; US showed caudate liver mass; FNA 25 g performed; Echo nsf. Cytology results: highly suspicious for liver carcinoma.

Abnormal PE/Chem/CBC/UA Results: 1/13/22 : elevated ALT 334, ALKP 887; on denamarin, metronidazole, lactulose

ULTRASONOGRAPHIC EXAMINATION OF THE ABDOMEN

Spleen

The **spleen** was not visualized as it was previously removed.

Liver

The hepatic mass was moderately vascular and occupied the caudal aspect of the right liver and impinged upon the portal hilus ventrally and upon the diaphragm cranial dorsally and vena cava dorsally. The mass measured 3.4 x 3.3 cm. It is debatable on whether this mass is resectable. CT evaluation with contrast is recommended for potential surgical planning. Irregular contour was noted to the caudate process as well.

Heart

Rapid view of the heart revealed no evidence of pathology.

ULTRASONOGRAPHIC FINDINGS

Right caudal liver mass, potentially resectable; however, it impinges on the vena cava dorsally and portal hilus ventrally and diaphragm cranial dorsally.

No other evidence of metastatic disease.

INTERPRETATION OF THE FINDINGS & FURTHER RECOMMENDATIONS

Clean resection may be difficult. CT for surgical planning is recommended.



PATIENT

Ace Crummett

SPECIES

Canine

BREED

Chihuahua

SEX

Neutered male

AGE

12 years

WEIGHT

5.6 lbs

INTERPRETED BY

Eric Lindquist, DMV
DABVP, Cert. IVUSS

IMAGING PERFORMED BY

Diane McFadden, RVT

HOSPITAL NAME

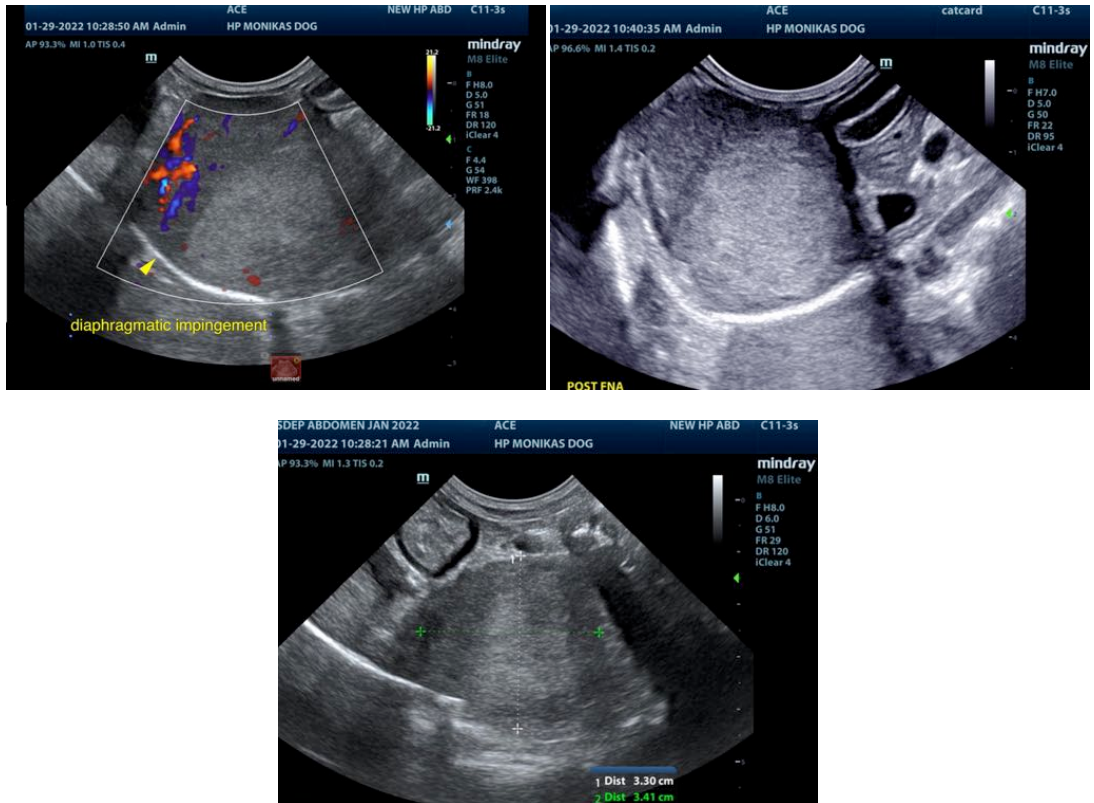
Animal Care Center of
Flanders

INVOICE

95817

DATE

2/3/22



The information and recommendations provided are based on the images presented by the referring veterinarian/sonographer. No evaluation can be communicated regarding pathology that was not visible in the image/video clips provided.

Thank you for this referral. If the clinical or image interpretation does not parallel your findings or if I can be of any further assistance please contact me.

Eric Lindquist, DMV, DABVP, Cert. IVUSS, CEO of SonoPath.com
Info@SonoPath.com