SonoPath
Clinical Sonography & Telecytology

EDUCATIONAL TELECONSULTATION SERVICES™

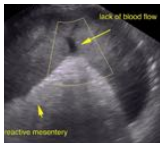

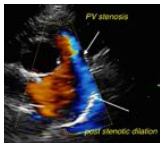

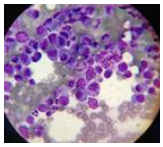
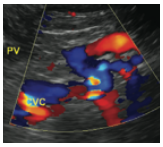

SonoPath.com™
1-800-838-4268 info@sonopath.com

PATIENT
Tigger Essig

SPECIES
Feline

BREED
Bengal

SEX
Neutered male

AGE
2 years

WEIGHT
10.8 lbs

INTERPRETED BY
Eric Lindquist, DMV
DABVP, Cert. IVUSS

IMAGING PERFORMED BY
Dr. Griffin

HOSPITAL NAME
Northside VC

REFERRING VET
Dr. Griffin

INVOICE
43030

DATE
2/28/23

PRESENTING CLINICAL SIGNS

History: Chronic constipation with periodic increased respiratory rate.
Abnormal PE/Chem/CBC/UA Results: Not responding to medical management thus far. Patient was sedated due to temperament. Patient is picky eater.

ULTRASONOGRAPHIC EXAMINATION OF THE ABDOMEN

Urinary System

The **urinary bladder**, trigone, and pelvic urethra presented normal thicknesses and normal tone. The pelvic urethra was imaged 2.0 cm beyond the cystourethral junction and appeared normal. The ureters were not visible which is normal. No uroliths or sediment were visualized and anechoic urine was present. No evidence of inflammatory or neoplastic changes was noted. Ureteral papillae were normal.

The **kidneys** revealed normal size and structure, corticomedullary definition and ratio for this age. The cortices presented largely uniform texture with normal echogenic relationship to liver and spleen. Medullary structure differed distinctly from the cortex and no evidence of pelvic dilation was present. The capsules were acceptably uniform without significant irregularities. The left kidney measured 3.4 cm. The right kidney measured 3.6 cm.

Adrenal Glands

Both **adrenal glands** were visualized and recognized as having normal shape, size, position and echogenicity for this breed. The phrenic vasculature, glandular echogenicity and detail were unremarkable. Capsule, cortex, and medullary definition were normal for this age patient. The left adrenal gland measured 0.33 cm. The right adrenal gland measured 0.37 cm.

Spleen

The **spleen** presented a smooth homogeneous parenchyma hyperechoic to liver and renal cortical parenchyma. The capsule was smooth without noticeable expansion or deviation from within the spleen or adjacent pathology. The splenic vasculature demonstrated normal volume without signs of congestion or thrombosis. No sonographic evidence of acute or chronic inflammatory, neoplastic, or infarctual changes was noted.

Liver

The **liver** revealed slight coarse architecture with mildly increased portal markings. The vascularity was normal. The gallbladder and common bile duct were unremarkable.

Gastrointestinal

The **gastric** lumen was fluid filled. The upper duodenum was mildly thickened. The jejunum was unremarkable. There was no loss of mural detail. Soft stool was noted in the colon.

SonoPath
Clinical Sonography & Telecytology
EDUCATIONAL TELECONSULTATION SERVICES™

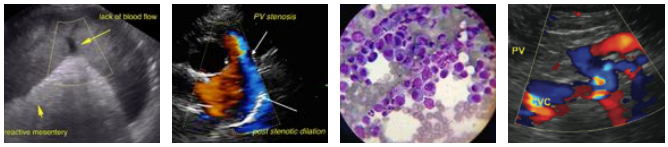

SonoPath.com™
1-800-838-4268 info@sonopath.com

PATIENT

Tigger Essig

SPECIES

Feline

BREED

Bengal

SEX

Neutered male

AGE

2 years

WEIGHT

10.8 lbs

INTERPRETED BY

Eric Lindquist, DMV
DABVP, Cert. IVUSS

IMAGING PERFORMED BY

Dr. Griffin

HOSPITAL NAME

Northside VC

REFERRING VET

Dr. Griffin

INVOICE

43030

DATE

2/28/23

Pancreas

The base and limbs of the **pancreas** were observed to be largely isoechoic to surrounding omental fat. Pancreatic duct and capsular contour were acceptably normal and parenchyma respected normal curvilinear patterns. No overt evidence of active inflammatory or neoplastic disease was noted.

ULTRASONOGRAPHIC FINDINGS

Minor thickened jejunum with gastric fluid.

Coarse hepatic architecture.

INTERPRETATION OF THE FINDINGS & FURTHER RECOMMENDATIONS

The patient likely has a history of gastroduodenitis. Subxiphoid palpation is recommended to assess for any discomfort regarding the stomach and duodenum that may be causing increased respiratory rate owing to pain. Otherwise, the abdomen is unremarkable. Hydrolyzed diet trial can be considered to ensure that hydration status is solid. If pain is solicited upon cranial abdominal digital palpation then pain management and potential antibiotic usage such as Zithromax and Metronidazole combination can also be considered.

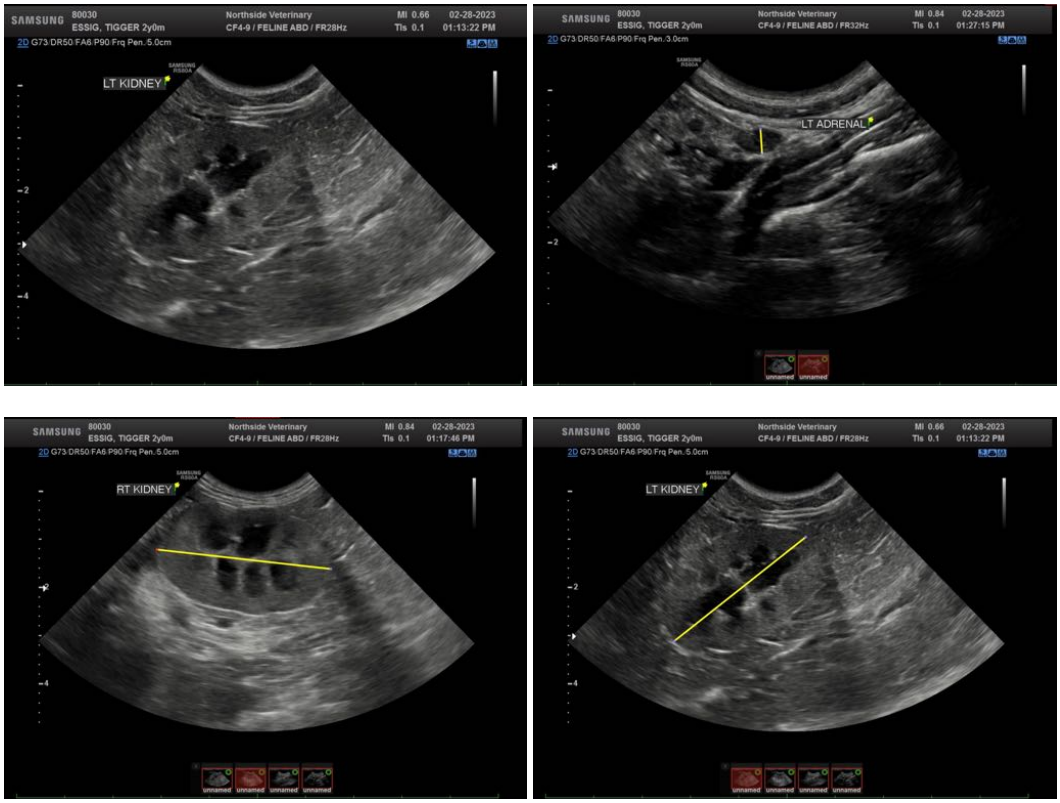

SonoPath

Clinical Sonography & Telecytology

EDUCATIONAL TELECONSULTATION SERVICES™

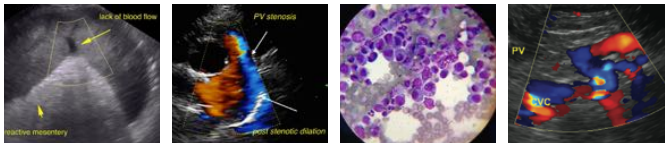

SonoPath.com™
1-800-838-4268 info@sonopath.com

PATIENT

Tigger Essig

SPECIES

Feline

BREED

Bengal

SEX

Neutered male

AGE

2 years

WEIGHT

10.8 lbs

INTERPRETED BY

Eric Lindquist, DMV
DABVP, Cert. IVUSS

IMAGING PERFORMED BY

Dr. Griffin

HOSPITAL NAME

Northside VC

REFERRING VET

Dr. Griffin

INVOICE

43030

DATE

2/28/23

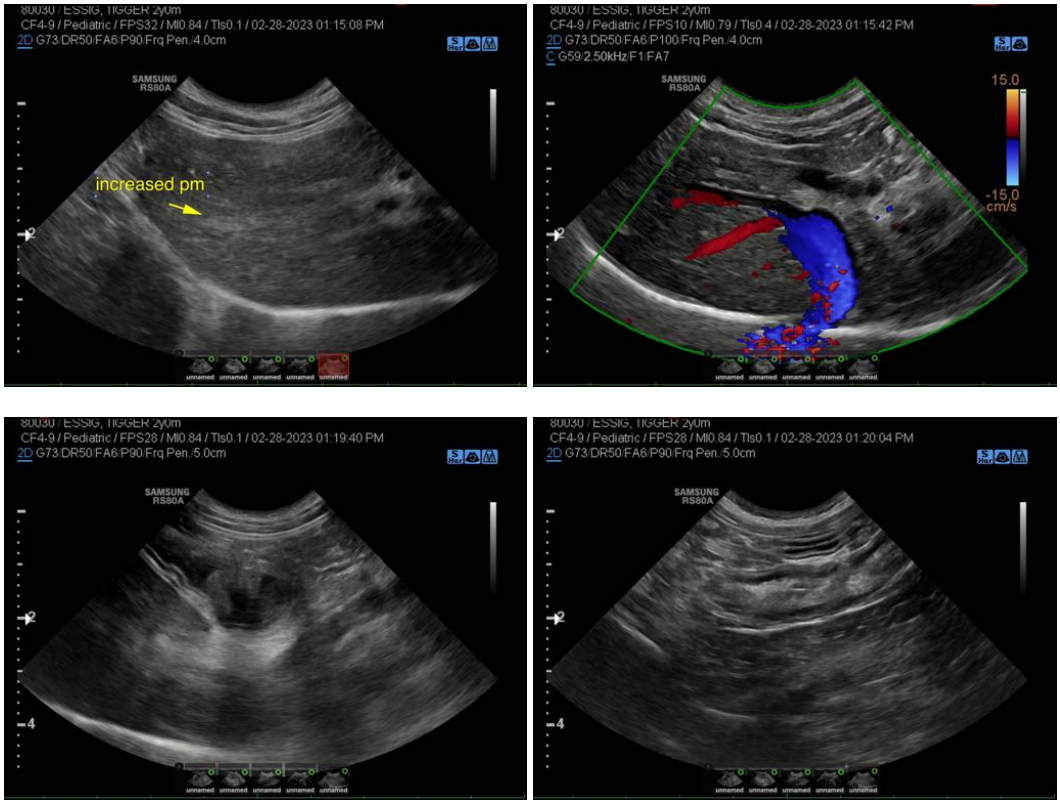

The information and recommendations provided are based on the images presented by the referring veterinarian/sonographer. No evaluation can be communicated regarding pathology that was not visible in the image/video clips provided.

Thank you for this referral. If the clinical or image interpretation does not parallel your findings or if I can be of any further assistance please contact me.

Eric Lindquist, DMV, DABVP, Cert. IVUSS, CEO of SonoPath.com
info@SonoPath.com