



PATIENT PRESENTING CLINICAL SIGNS

Lucky Cupo History: Grade 3/6 heart murmur, lethargy, ascites

SPECIES ULTRASONOGRAPHIC EXAMINATION OF THE HEART

Canine

The cardiac presentation revealed prolapse of the anterior mitral valve leaflet, severe volume overload in the left atrium, left ventricle, right atrium and right ventricle. Contractility was marginal and non-compensatory. Slight pericardial effusion was noted without tamponade effect. Mitral and tricuspid insufficiency was noted. No pleural pathology was noted.

BREED

Cockapoo

SEX

Neutered male

AGE

12 years

WEIGHT

35 lbs

INTERPRETED BY

Eric Lindquist, DMV
DABVP, Cert. IVUSS

CANINE CARDIAC PARAMETERS	MR VMAX (m/s)	TR VMAX (m/s)	LA/AO (Boon method)	LA/AO (Heart Base;)	FS (%)	EF (%)	EPSS (cm)
NORMAL PARAMETER	4.5-5.5	<2.7	1.3	<1.6	28-40	40-100	<0.6
PATIENT	5.0	3.0	3.0	>2.0			0.1
CANINE CARDIAC PARAMETERS	HR (BPM)	AV VMAX (m/s)	PV MAX (m/s)	BODY WEIGHT	LA 2D short axis Base view (cm)	LVIDd Avg; 2D and m- mode short axis (cm)	LVIDs Avg; 2D and m-mode short axis (cm)
NORMAL PARAMETER	50-100	0.7-1.7	0.7-1.6	BELOW	BELOW	BELOW	BELOW
PATIENT			0.6	35 lbs	5.54		

IMAGING PERFORMED BY

Dr. Petrone

HOSPITAL NAME

Long Branch AH

REFERRING VET

Dr. Petrone

INVOICE

43022

DATE

2/28/23

ULTRASONOGRAPHIC EXAMINATION OF THE ABDOMEN

Urinary System

The **urinary bladder**, trigone, and pelvic urethra presented normal thicknesses and normal tone. The ureters were not visible which is normal. No uroliths or sediment were visualized and anechoic urine was present. No evidence of inflammatory or neoplastic changes was noted. Ureteral papillae were normal.

The **kidneys** revealed normal size and structure, corticomedullary definition and ratio for this age. The cortices presented largely uniform texture with normal echogenic relationship to liver and spleen. Medullary structure differed distinctly from the cortex and no evidence of pelvic dilation was present. The capsules were acceptably uniform without significant irregularities. The right kidney measured 6.33 cm. The left kidney measured 5.96 cm.



PATIENT

Adrenal Glands

Lucky Cupo

Both **adrenal glands** were visualized and recognized as having normal shape, size, position and echogenicity for this breed. The phrenic vasculature, glandular echogenicity and detail were unremarkable. Capsule, cortex, and medullary definition were normal for this age patient.

SPECIES

Canine

Spleen

BREED

Cockapoo

The **spleen** in this patient was uniform, yet volume contracted. Hydration status should be assessed.

SEX

Neutered male

Liver

AGE

12 years

The **liver** was uniformly enlarged with mild, heterogenous parenchymal changes. The hepatic veins are dilated. This is consistent with passive congestion owing to right sided failure. The gallbladder presented acceptably thin walls with primarily anechoic content. The cystic and common bile ducts were normal. No pathological hepatic lymphadenopathy was evident. No overt structural evidence of inflammatory, infiltrative or regenerative pathology was evident.

WEIGHT

35 lbs

Gastrointestinal

Examination of the **gastrointestinal tract** revealed a stomach and intestine free of stasis, of normal wall thickness, acceptable curvilinear mural detail, and peristaltic activity. Small and large intestine demonstrated normal luminal chyme and stool consistency respectively. No obstructive or overt infiltrative disease was noted. No associated abnormal lymphatic activity was noted.

INTERPRETED BY

Eric Lindquist, DMV
DABVP, Cert. IVUSS

Pancreas

IMAGING PERFORMED BY

Dr. Petrone

Enhanced mesentery was noted around the **pancreas** owing to the ascites; however, there was no primary disease noted.

HOSPITAL NAME

Long Branch AH

Free Abdomen

A large amount of echogenic ascites was noted.

REFERRING VET

Dr. Petrone

ULTRASONOGRAPHIC FINDINGS

Unremarkable abdomen with ascites owing to passive congestion from right sided heart failure.

INVOICE

43022

End stage D1 valvular disease. Left and right-sided heart failure with secondary pericardial effusion.

DATE

2/28/23



PATIENT

Lucky Cupo

SPECIES

Canine

BREED

Cockapoo

SEX

Neutered male

AGE

12 years

WEIGHT

35 lbs

INTERPRETED BY

Eric Lindquist, DMV
DABVP, Cert. IVUSS

IMAGING PERFORMED BY

Dr. Petrone

HOSPITAL NAME

Long Branch AH

REFERRING VET

Dr. Petrone

INVOICE

43022

DATE

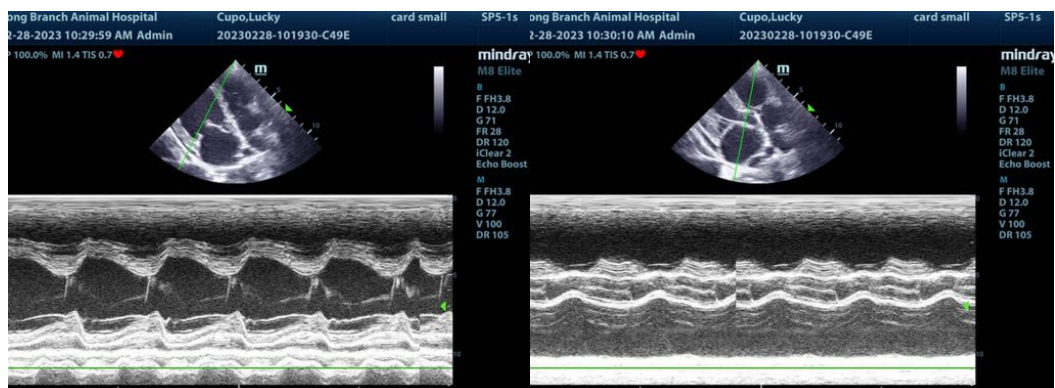
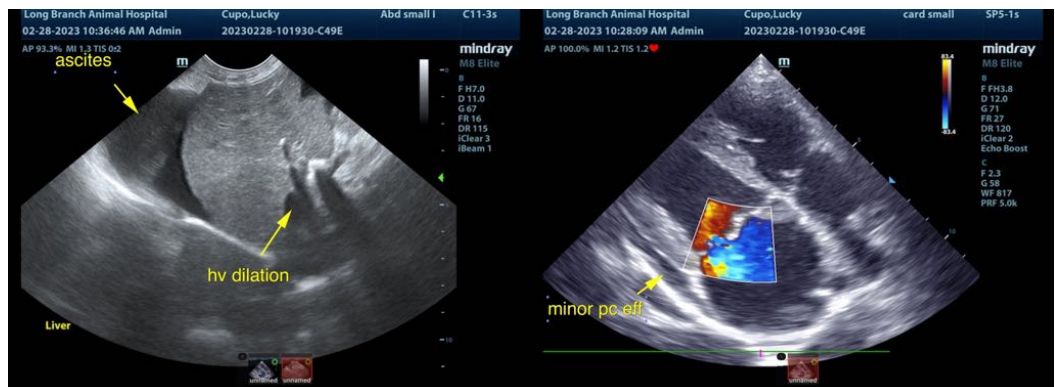
2/28/23

INTERPRETATION OF THE FINDINGS & FURTHER RECOMMENDATIONS

I recommend continuation of Lasix, Pimobendan, Enalapril and Spironolactone. Sildenafil can be considered at 1 mg/kg b.i.d. I recommend increasing Lasix to 2-4 b.i.d. Pimobendan at 0.3 mg/kg b.i.d. and Spironolactone at 1-2 mg/kg b.i.d. Torsemide can be considered. Prognosis is poor. This patient is at risk for sudden death. Therapeutic options are minimal at this point.

Torsemide rescue therapy can be considered with attentive dose management in respect to renal/urinary side effects.

This patient is at high risk for sudden death with severe volume overload and lack of myocardial compensation. Cage rest +/- O2 therapy and limited essential leash walking is recommended. Target respiratory rate is < 20-25 resp/minute after therapy. After initiating therapy, I recommend recheck on the clinical exam, BUN, Creatinine, USG, Chest radiographs & Blood pressure daily to every 3-5 days if stabilizing. Recheck echo in 1-4 weeks depending on clinical progression or regression. This patient should NOT undergo anesthesia unless for a lifesaving event.





PATIENT

Lucky Cupo

SPECIES

Canine

BREED

Cockapoo

SEX

Neutered male

AGE

12 years

WEIGHT

35 lbs

INTERPRETED BY

Eric Lindquist, DMV
DABVP, Cert. IVUSS

IMAGING PERFORMED BY

Dr. Petrone

HOSPITAL NAME

Long Branch AH

REFERRING VET

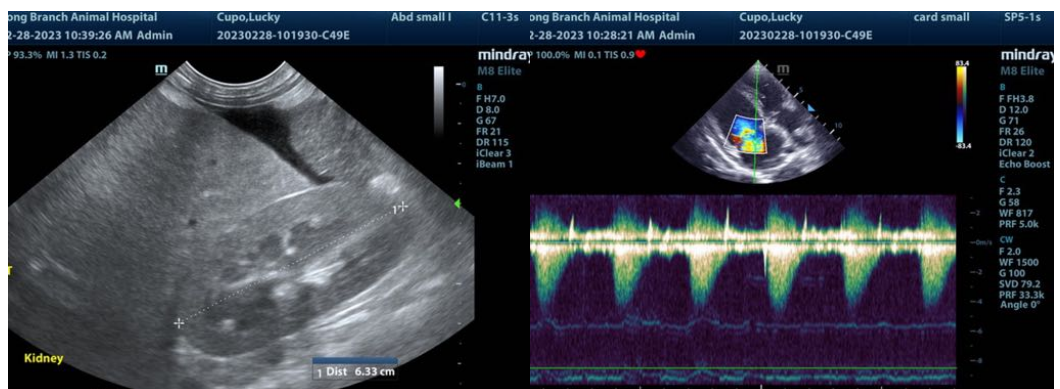
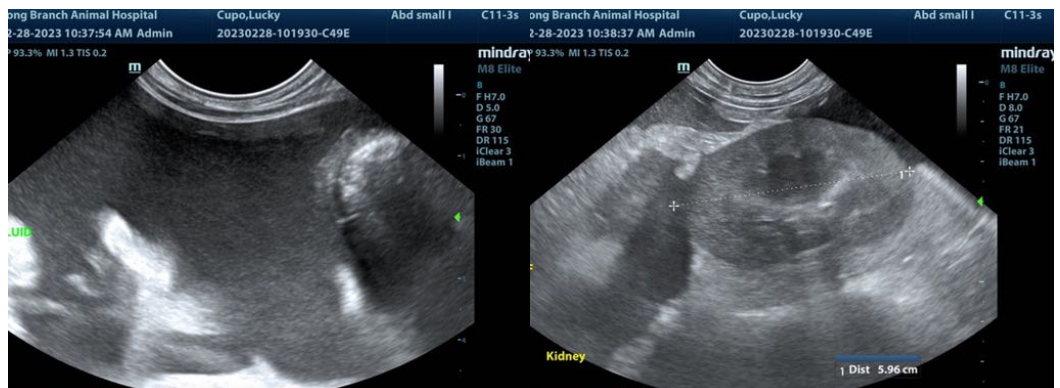
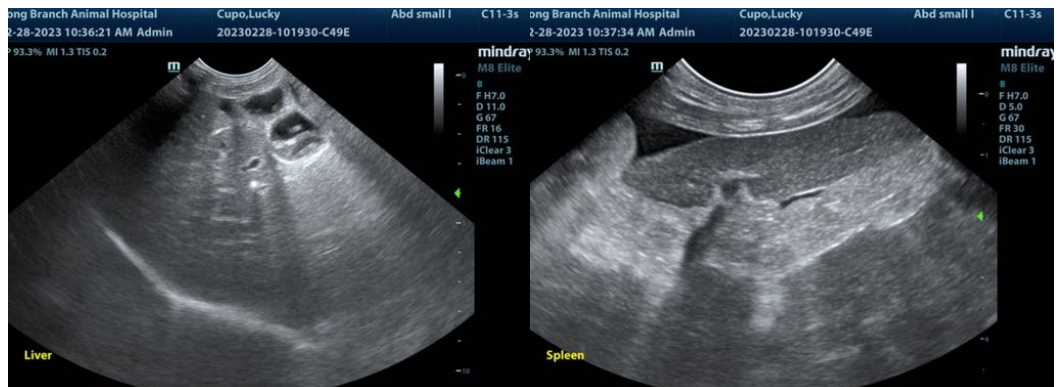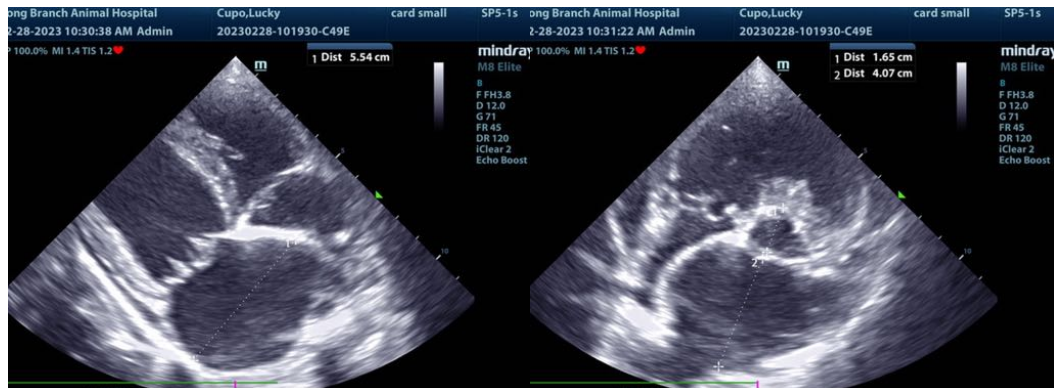
Dr. Petrone

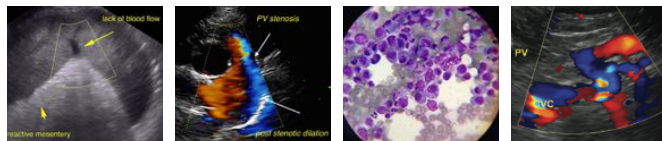
INVOICE

43022

DATE

2/28/23





PATIENT

Lucky Cupo

The information and recommendations provided are based on the images presented by the referring veterinarian/sonographer. No evaluation can be communicated regarding pathology that was not visible in the image/video clips provided.

SPECIES

Canine

Thank you for this referral. If the clinical or image interpretation does not parallel your findings or if I can be of any further assistance please contact me.

BREED

Cockapoo

Eric Lindquist, DMV, DABVP, Cert. IVUSS, CEO of SonoPath.com
info@SonoPath.com

SEX

Neutered male

AGE

12 years

WEIGHT

35 lbs

INTERPRETED BY

Eric Lindquist, DMV
DABVP, Cert. IVUSS

**IMAGING
PERFORMED BY**

Dr. Petrone

HOSPITAL NAME

Long Branch AH

REFERRING VET

Dr. Petrone

INVOICE

43022

DATE

2/28/23