



**PATIENT**

**PRESENTING CLINICAL SIGNS**

Kylie Dietz

History: recheck prev u/s yesterday showed shadowing contents within the gastric lumen

**SPECIES**

**ULTRASONOGRAPHIC EXAMINATION OF THE ABDOMEN**

Canine

**Gastrointestinal**

**BREED**

Stomach revealed approximately 5 cm of soft shadowing persistent material in the stomach. This is non-obstructive but likely irritative. The small intestines and colon were empty and unremarkable.

Boxer

**SEX**

**ULTRASONOGRAPHIC FINDINGS**

Female

Persistent shadowing material in the stomach.

**AGE**

**INTERPRETATION OF THE FINDINGS & FURTHER RECOMMENDATIONS**

1 year

Gastrotomy and gastric bx indicated if the patient was completely n.p.o. and is still clinical. Scope could be considered but may be difficult to remove the material via scope.

**WEIGHT**

64 lbs

**INTERPRETED BY**

Eric Lindquist, DMV  
DABVP, Cert. IVUSS

**IMAGING PERFORMED BY**

Jenn

**HOSPITAL NAME**

Rockaway AH

**REFERRING VET**

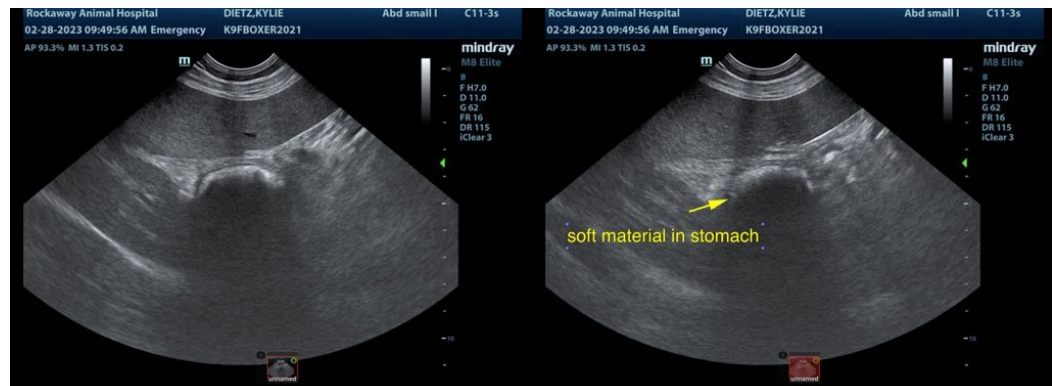
Dr. Maniar

**INVOICE**

42989

**DATE**

2/28/23



The information and recommendations provided are based on the images presented by the referring veterinarian/sonographer. No evaluation can be communicated regarding pathology that was not visible in the image/video clips provided.

Thank you for this referral. If the clinical or image interpretation does not parallel your findings or if I can be of any further assistance please contact me.

**Eric Lindquist, DMV, DABVP, Cert. IVUSS, CEO of SonoPath.com**  
info@SonoPath.com