



PATIENT

Lola Coble

SPECIES

Canine

BREED

Jack Russell X

SEX

Spayed Female

AGE

14 Years

WEIGHT

19 Pounds

PRESENTING CLINICAL SIGNS

6mo Recheck - Chronic valvular insufficiency. Current meds: Furosemide 12.5 BID, Pimobendan 2.5mg BID, Enalapril 5mg SID
Abnormal PE/Chem/CBC/UA Results: ALKP 253, BUN 40, Creat 1.3

ULTRASONOGRAPHIC EXAMINATION OF THE HEART

CANINE CARDIAC PARAMETERS	MR VMAX (m/s)	TR VMAX (m/s)	LA/AO (Boon method)	LA/AO (Heart Base; Swe)	FS (%)	EF (%)	EPSS (cm)
NORMAL PARAMETER	4.5-5.5	<2.7	1.3	<1.6	28-40	40-100	<0.6
PATIENT	5.8	1.54	1.85	1.82	62	91	0.2
CANINE CARDIAC PARAMETERS	HR (BPM)	AV VMAX (m/s)	PV MAX (m/s)	BODY WEIGHT (kg)	LA 2D short axis Base view (cm)	LVIDd Avg; 2D and m-mode short axis (cm)	LVIDs Avg; 2D and m-mode short axis (cm)
NORMAL PARAMETER	50-100	0.7-1.7	0.7-1.6	BELOW	BELOW	BELOW	BELOW
PATIENT	124	1.87	1.05		4.21	4.2	

INTERPRETED BY

Eric Lindquist, DMV
DABVP, Cert. IVUSS

IMAGING PERFORMED BY

Jessica Miller

HOSPITAL NAME

Newton Vet Hospital

REFERRING VET

Dr. Bladek

INVOICE

35963

DATE

2/28/22

Cardiac Presentation

The cardiac presentation revealed progressive volume overload in the left atrium and right ventricle. Prolapse of the anterior mitral valve leaflet noted. Completely filling of the left atrium present. Tricuspid insufficiency noted. Unremarkable right atrium and right ventricle. No pericardial effusion.

ULTRASONOGRAPHIC FINDINGS

- Progressive volume overload compared to prior echocardiogram

INTERPRETATION OF THE FINDINGS & FURTHER RECOMMENDATIONS

Recommend adjustment of medications to Spironolactone at 1-2 mg/kg BID and increasing ACE inhibitor to BID dosing at 0.5 mg/kg. If basal respiratory rate is >20/min, a mild increase in Furosemide could also be considered. Recheck echo in 3 months, earlier if murmur grade increases or clinical signs initiate. Blood pressure measurements indicated as well as monitoring BUN and Creatinine.



PATIENT

Lola Cobley

SPECIES

Canine

BREED

Jack Russell X

SEX

Spayed Female

AGE

14 Years

WEIGHT

19 Pounds

INTERPRETED BY

Eric Lindquist, DMV
DABVP, Cert. IVUSS

IMAGING PERFORMED BY

Jessica Miller

HOSPITAL NAME

Newton Vet Hospital

REFERRING VET

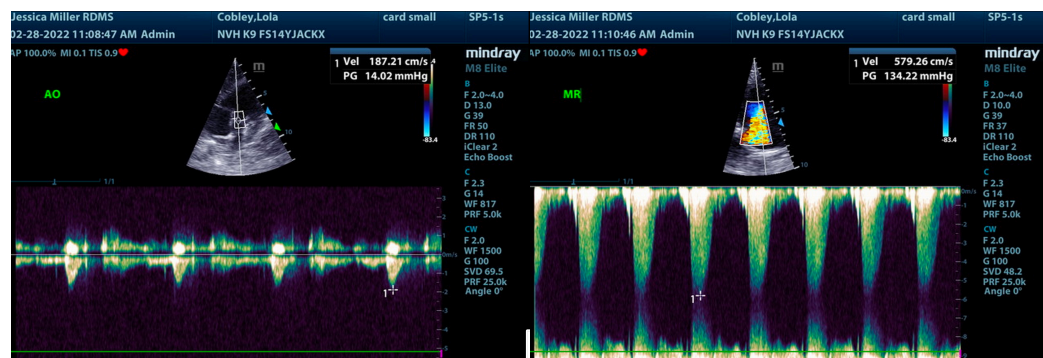
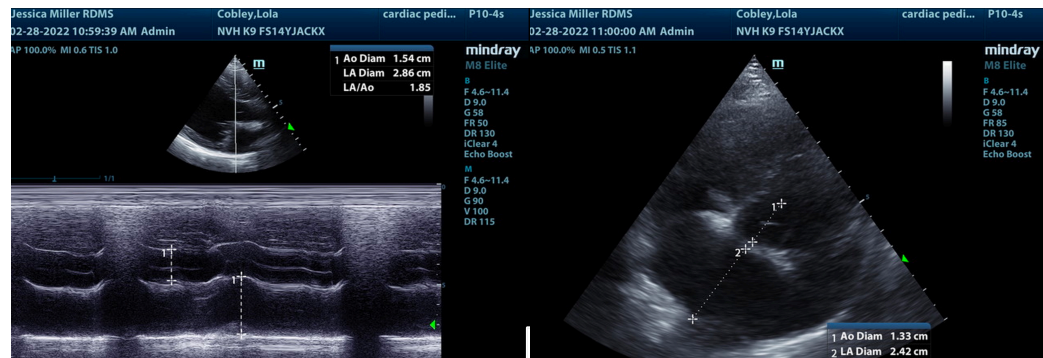
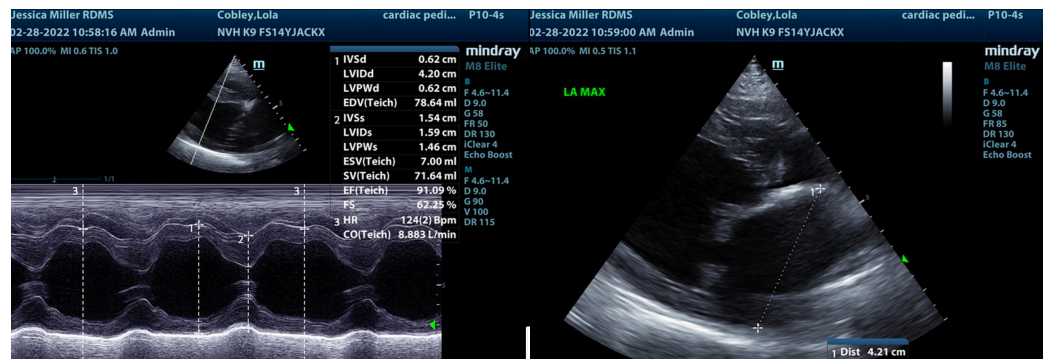
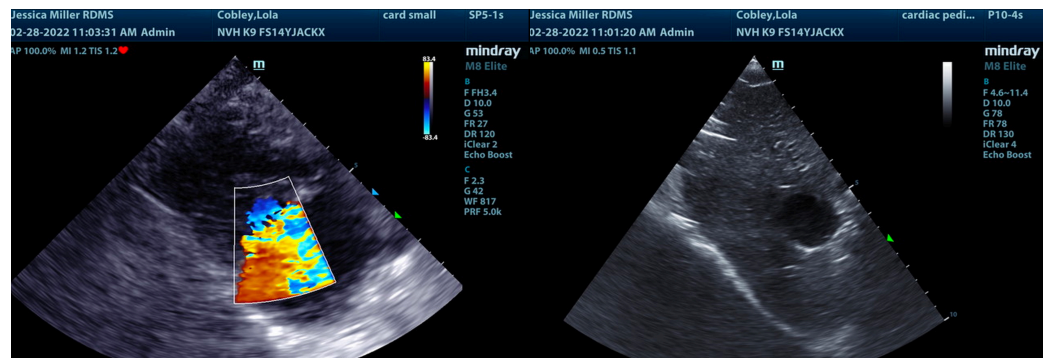
Dr. Bladek

INVOICE

35963

DATE

2/28/22





PATIENT

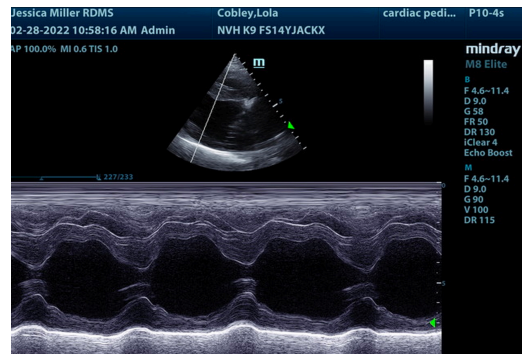
Lola Coble

SPECIES

Canine

BREED

Jack Russell X



SEX

Spayed Female

AGE

14 Years

WEIGHT

19 Pounds

INTERPRETED BY

Eric Lindquist, DMV

DABVP, Cert. IVUSS

IMAGING PERFORMED BY

Jessica Miller

HOSPITAL NAME

Newton Vet Hospital

REFERRING VET

Dr. Bladek

INVOICE

35963

DATE

2/28/22

The information and recommendations provided are based on the images presented by the referring veterinarian/sonographer. No evaluation can be communicated regarding pathology that was not visible in the image/video clips provided.

Thank you for this referral. If the clinical or image interpretation does not parallel your findings or if I can be of any further assistance please contact me.

Eric Lindquist, DMV, DABVP, Cert. IVUSS, CEO of SonoPath.com

info@SonoPath.com