



**PATIENT PRESENTING CLINICAL SIGNS**

Gus Parker x-rays show large irregular liver acute onset head tremors and rear leg paresis

**SPECIES ULTRASONOGRAPHIC EXAMINATION OF THE ABDOMEN**

**Feline Urinary System**

The **urinary bladder** presented a grouping of calculi measuring 1.3 cm. The largest calculus measured approximately 3.0 mm, non-obstructive at the time of the sonogram. However, they are in position to obstruct at any time. The pelvic urethra was imaged 2.0 cm beyond the cystourethral junction.

**BREED**

DSH

The **kidneys** revealed largely normal size and structure, corticomedullary definition and ratio (cortex 1/3 of medulla) were essentially maintained with some age-related loss of curvilinear patterns regarding the capsule and C/M junction. The cortices presented largely uniform texture with some increased echogenicity expected for his age patient. Medullary structure differed distinctly from that of the cortex and no evidence of pelvic dilation was present. The right kidney measured 3.95 cm. The left kidney measured 4.16 cm. Non-obstructive calculi present.

**SEX**

Neutered Male

**AGE**

14 Years

**Adrenal Glands**

The regions of the **adrenal glands** were unremarkable.

**Spleen**

**WEIGHT**

9.9 Pounds

The **spleen** presented a smooth homogeneous parenchyma hyperechoic to liver and renal cortical parenchyma. The capsule was smooth without noticeable expansion or deviation from within the spleen or adjacent pathology. The splenic vasculature demonstrated normal volume without signs of congestion or thrombosis. No sonographic evidence of acute or chronic inflammatory, neoplastic, or infarctual changes were noted.

**INTERPRETED BY**

Eric Lindquist, DMV

**Liver**

DABVP, Cert. IVUSS

The **liver** presented generalized hepatomegaly and was riddled with multiple expansive masses, deviating the stomach caudally and enveloping the gallbladder. Masses were in both the right and left liver, largely consistent with sarcoma, possibility of carcinoma.

**IMAGING PERFORMED BY**

Jenn

**Gastrointestinal**

**HOSPITAL NAME**

Rockaway AH

Examination of the **gastrointestinal tract** revealed a stomach and intestine free of stasis, of normal wall thickness, acceptable curvilinear mural detail, and peristaltic activity. Small and large intestine demonstrated normal luminal chyme and stool consistency respectively. No obstructive or overt infiltrative disease was noted. No associated abnormal lymphatic activity was noted.

**REFERRING VET**

Dr. Ascot

**Pancreas**

The base and limbs of the **pancreas** were observed to be largely isoechoic to surrounding omental fat.

**INVOICE**

35944

Some parenchymal remodeling, however, with mild deviation from curvilinear normalcy was observed. Pancreatic duct and capsular irregularities were present consistent with age related changes. If pain upon imaging (+ Murphy sign) was present or if the patient is focally painful in subxyphoid palpation then low-grade smoldering chronic pancreatitis should be suspected.

**ULTRASONOGRAPHIC FINDINGS**

**DATE**

2/28/22

- Multifocal liver masses



**PATIENT**

Gus Parker

**SPECIES**

Feline

**BREED**

DSH

**SEX**

Neutered Male

**AGE**

14 Years

**WEIGHT**

9.9 Pounds

**INTERPRETED BY**

Eric Lindquist, DMV  
DABVP, Cert. IVUSS

**IMAGING PERFORMED BY**

Jenn

**HOSPITAL NAME**

Rockaway AH

**REFERRING VET**

Dr. Ascot

**INVOICE**

35944

**DATE**

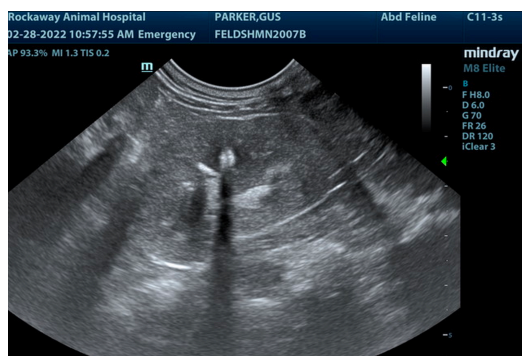
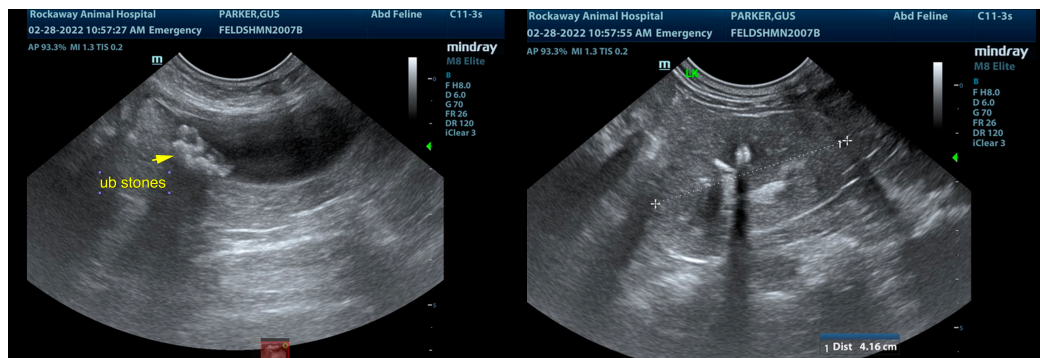
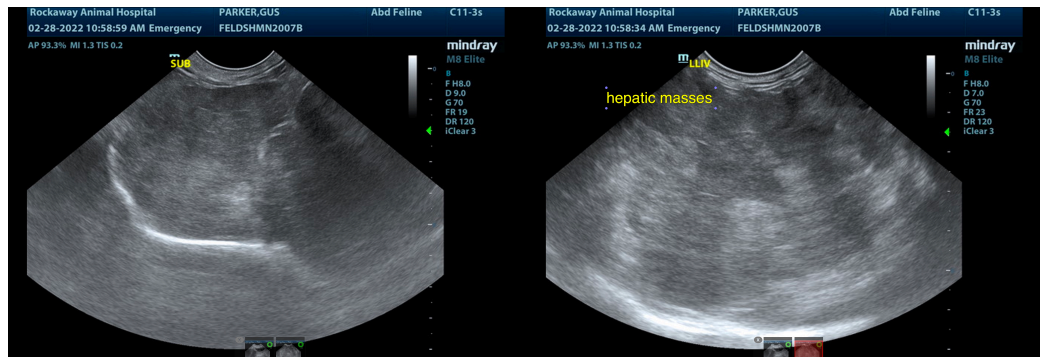
2/28/22

**INTERPRETATION OF THE FINDINGS & FURTHER RECOMMENDATIONS**

FNA indicated for further definition. Prognosis is poor depending upon responsiveness to chemotherapy. Given the head tremors, neoplastic spread to the CNS is a strong potential. CT with contrast would be necessary for further definition of this possible.

**SonoPath CT Services** are offered at the [Blairstown Animal Hospital](https://sonopath.com/resources/sonopath-teleconsultation-services-and-sdep-certification/sonopath-ct-services). Blairstown animal hospital is just a 30-minute drive west on route 80 from the route 80/287 interchange/Parsippany, New Jersey. More information can be found at:

<https://sonopath.com/resources/sonopath-teleconsultation-services-and-sdep-certification/sonopath-ct-services>





**PATIENT**

Gus Parker

The information and recommendations provided are based on the images presented by the referring veterinarian/sonographer. No evaluation can be communicated regarding pathology that was not visible in the image/video clips provided.

**SPECIES**

Feline

Thank you for this referral. If the clinical or image interpretation does not parallel your findings or if I can be of any further assistance please contact me.

**Eric Lindquist**, DMV, DABVP, Cert. IVUSS, CEO of SonoPath.com

[info@SonoPath.com](mailto:info@SonoPath.com)

**BREED**

DSH

**SEX**

Neutered Male

**AGE**

14 Years

**WEIGHT**

9.9 Pounds

**INTERPRETED BY**

Eric Lindquist, DMV

DABVP, Cert. IVUSS

**IMAGING PERFORMED BY**

Jenn

**HOSPITAL NAME**

Rockaway AH

**REFERRING VET**

Dr. Ascot

**INVOICE**

35944

**DATE**

2/28/22