



## PATIENT

Lucky Dremmel

## SPECIES

Feline

## BREED

Domestic Shorthair

## SEX

Neutered male

## AGE

13 years

## WEIGHT

17.9 lbs

## INTERPRETED BY

Eric Lindquist, DMV  
DABVP, Cert. IVUSS

## IMAGING PERFORMED BY

Seth Edgar, DVM

## HOSPITAL NAME

Overpeck Creek AH

## REFERRING VET

Dr. Edgar

## INVOICE

72069

## DATE

2/27/26

## PRESENTING CLINICAL SIGNS

- Lucky is a 13 year old NM DSH presented for abdominal ultrasound as part of work up for possible idiopathic hypercalcemia. Previous lab works have shown a gradual increase in total calcium levels, from 2/9/25 (12.1) to 2/8/26 (13.2). KD diet has failed to resolve the hypercalcemia. Is now on OM. Hypercalcemia of Malignancy panel to Michigan showed iCa (1.55), PTH (< 0.5), Parathormone Related Protein (0). Recheck lab work is pending after being on OM for 30 days.

## ULTRASONOGRAPHIC EXAMINATION OF THE ABDOMEN

### Urinary System

The **urinary bladder**, trigone, and pelvic urethra presented normal thicknesses and normal tone. The ureters were not visible which is normal. No uroliths or sediment were visualized and anechoic urine was present. No evidence of inflammatory or neoplastic changes was noted. Ureteral papillae were normal.

The **kidneys** revealed largely normal size and structure, corticomedullary definition and ratio (cortex 1/3 of medulla) were essentially maintained with some age-related loss of curvilinear patterns regarding the capsule and C/M junction. The cortices presented largely uniform texture with some increased echogenicity expected for this age patient. Medullary structure differed distinctly from that of the cortex and no evidence of pelvic dilation was present. Slight mineralization was noted in the kidneys. The left kidney and right kidney measured 2.8 cm.

### Adrenal Glands

Both **adrenal glands** were visualized and recognized as having normal shape, size, position and echogenicity for this breed. The phrenic vasculature, glandular echogenicity and detail were unremarkable. Capsule, cortex, and medullary definition were normal for this age patient. The right adrenal gland measured 0.5 cm and the left adrenal gland measured 0.33 cm.

### Spleen

The **spleen** presented a smooth homogeneous parenchyma hyperechoic to liver and renal cortical parenchyma. The capsule was smooth without noticeable expansion or deviation from within the spleen or adjacent pathology. The splenic vasculature demonstrated normal volume without signs of congestion or thrombosis. No sonographic evidence of acute or chronic inflammatory, neoplastic, or infarctual changes was noted.

### Liver

The **liver** images from right and left intercostal as well as subcostal views revealed subjectively normal liver size, contour, and structure. Some age-related parenchymal remodeling was noted but likely not clinically significant at this time. Vascular and biliary tracts were of normal volume and no evidence of congestion was noted. The gallbladder presented some dependent debris with essentially normal



## PATIENT

Lucky Dremmel

## SPECIES

Feline

## BREED

Domestic Shorthair

## SEX

Neutered male

## AGE

13 years

## WEIGHT

17.9 lbs

## INTERPRETED BY

Eric Lindquist, DMV  
DABVP, Cert. IVUSS

## IMAGING PERFORMED BY

Seth Edgar, DVM

## HOSPITAL NAME

Overpeck Creek AH

## REFERRING VET

Dr. Edgar

## INVOICE

72069

## DATE

2/27/26

contour. The cystic and common bile ducts were normal. No overt evidence of active inflammatory, infiltrative or regenerative pathology was noted but should be paired with current or past LE elevations regarding any clinical significance to this presentation. The hepatic lymph nodes were unremarkable.

## Gastrointestinal

Examination of the **gastrointestinal tract** revealed a stomach and intestine free of stasis, of normal wall thickness, acceptable curvilinear mural detail, and peristaltic activity. The stomach revealed gastric hairball type density that measured 4.0 cm. Small and large intestine demonstrated normal luminal chyme and stool consistency respectively. No obstructive or overt infiltrative disease was noted. No associated abnormal lymphatic activity was noted.

## Pancreas

The base and limbs of the **pancreas** were observed to be largely isoechoic to surrounding omental fat. Pancreatic duct and capsular contour were acceptably normal and parenchyma respected normal curvilinear patterns. No overt evidence of active inflammatory or neoplastic disease was noted.

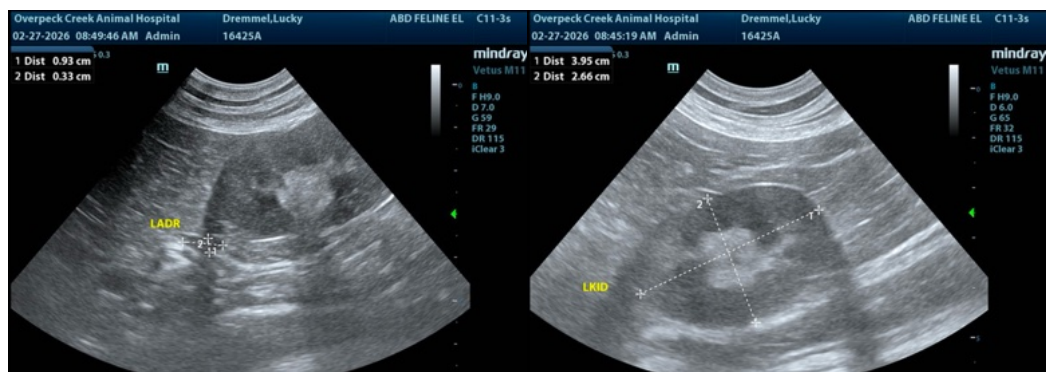
## ULTRASONOGRAPHIC FINDINGS

Hairball density in the stomach.

Geriatric abdomen.

## INTERPRETATION OF THE FINDINGS & FURTHER RECOMMENDATIONS

Hairball therapy is recommended in this patient.





**PATIENT**

Lucky Dremmel

**SPECIES**

Feline

**BREED**

Domestic Shorthair

**SEX**

Neutered male

**AGE**

13 years

**WEIGHT**

17.9 lbs

**INTERPRETED BY**

Eric Lindquist, DMV  
DABVP, Cert. IVUSS

**IMAGING PERFORMED BY**

Seth Edgar, DVM

**HOSPITAL NAME**

Overpeck Creek AH

**REFERRING VET**

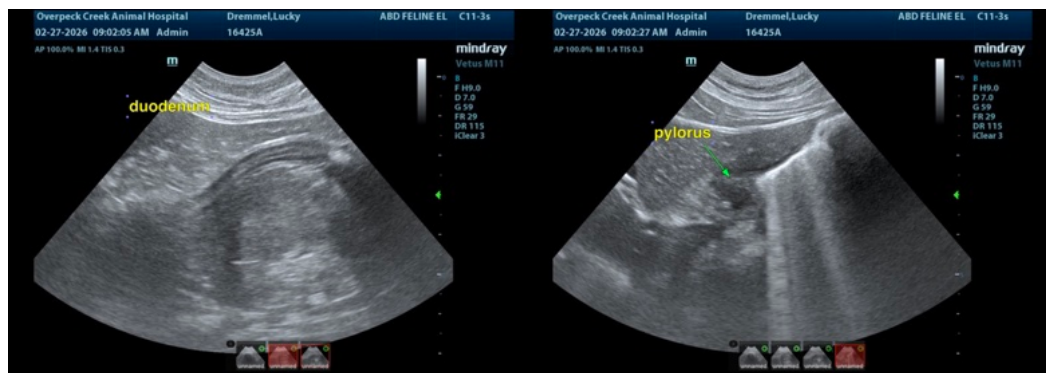
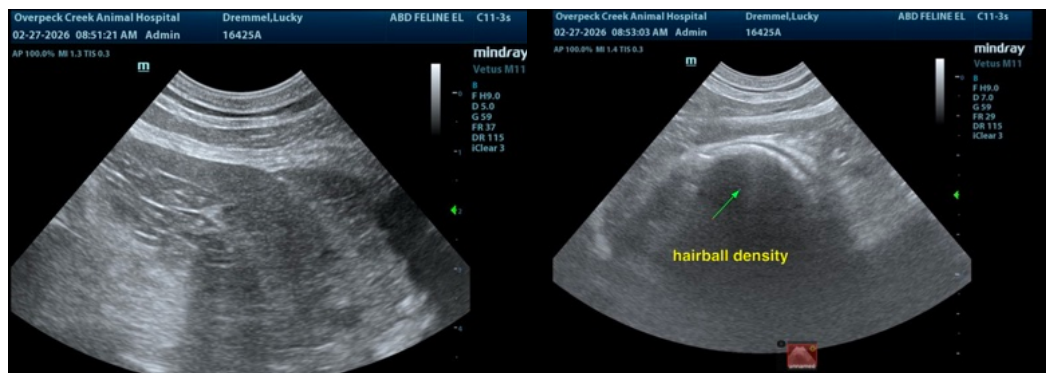
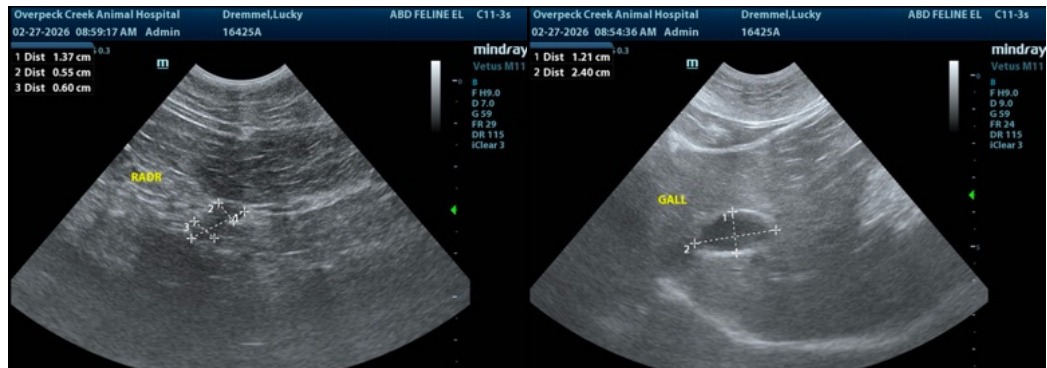Dr. Edgar

**INVOICE**

72069

**DATE**

2/27/26



The information and recommendations provided are based on the images presented by the referring veterinarian/sonographer. No evaluation can be communicated regarding pathology that was not visible in the image/video clips provided.

Thank you for this referral. If the clinical or image interpretation does not parallel your findings or if I can be of any further assistance please contact me.

Eric Lindquist, DMV, DABVP (CFM), Cert. IVUSS, CEO of SonoPath.com

[info@SonoPath.com](mailto:info@SonoPath.com)