



PATIENT

E.B. Mando

SPECIES

Canine

BREED

Tibetan Spaniel

SEX

Neutered Male

AGE

11 Years 4 Months

WEIGHT

20

INTERPRETED BY

Eric Lindquist, DMV,
DABVP(CFM), Cert.
IVUSS

IMAGING PERFORMED BY

Heather

HOSPITAL NAME

Animal Care Clinic of
Flanders

REFERRING VET

Dr. Hargadon

INVOICE

13997

DATE

02/27/26

PRESENTING CLINICAL SIGNS

- louder heart murmur, assessing for potential steroid tx due to back injury
- grade 4 murmur,
- sildenafil 20mg -1/2 BID; clindamycin 75 mg - 1 cup bid - pulse abx; gabapentin 50mg 1 BID prn

ULTRASONOGRAPHIC EXAMINATION OF THE HEART

CANINE CARDIAC PARAMETERS	MR VMAX (m/s)	TR VMAX (m/s)	LA/AO (M-Mode)	LA/AO (Heart Base; Swe)	FS (%)	EF (%)	EPSS (cm)
NORMAL PARAMETER	4.5-5.5	<2.7	1.3	Up to 1.6	28-40	40-100	<0.6
PATIENT	--	--	NM	--	35	90	0.1
CANINE CARDIAC PARAMETERS	HR (BPM)	AV VMAX (m/s)	PV MAX (m/s)	BODY WEIGHT	LAD LA MAX 4 Chamber	LVIDd Avg; 2D and m-mode short axis (cm)	LVIDs Avg; 2D and m-mode short axis (cm)
NORMAL PARAMETER	50-100	0.7-1.7	0.7-1.6				
PATIENT	NM	NM	0.9	20	3.4	2.7	--

Cardiac Presentation

The patient present with mitral and tricuspid insufficiency with mild left atrial enlargement and moderate right atrial enlargement. Flattening of the left ventricular septum was noted consistent with pulmonary hypertension. Volume overload in the right heart was present. No evidence of pericardial or pleural effusion was present. Hepatic veins were not dilated.

ULTRASONOGRAPHIC FINDINGS

- Mitral and tricuspid insufficiency.
- Mild left atrial enlargement.
- Pulmonary hypertension.

INTERPRETATION OF THE FINDINGS & FURTHER RECOMMENDATIONS

Steroid use should be limited to minimal effective dose and oral. I do not recommend injectable cortisones in this patient. I do recommend an addition of an ACE inhibitor at 0.50 mg/kg BID and Pimobendan at 0.30 mg/kg BID. Recheck echo is recommended in 1-3 months depending upon clinical signs.



PATIENT

E.B. Mando

SPECIES

Canine

BREED

Tibetan Spaniel

SEX

Neutered Male

AGE

11 Years 4 Months

WEIGHT

20

INTERPRETED BY

Eric Lindquist, DMV,
DABVP(CFM), Cert.
IVUSS

**IMAGING
PERFORMED BY**

Heather

HOSPITAL NAME

Animal Care Clinic of
Flanders

REFERRING VET

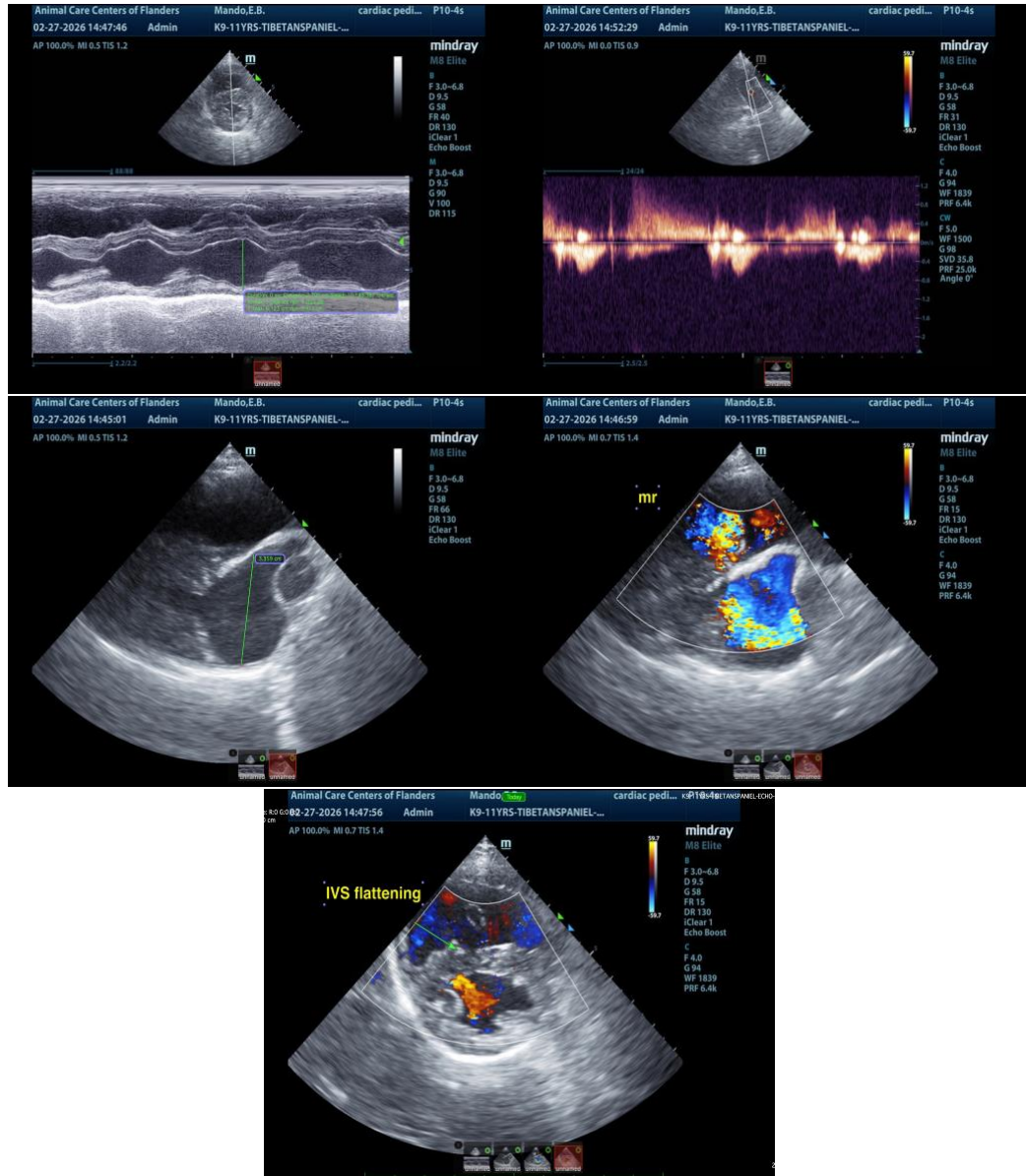
Dr. Hargadon

INVOICE

13997

DATE

02/27/26



The information and recommendations provided are based on the images presented by the referring veterinarian/sonographer. No evaluation can be communicated regarding pathology that was not visible in the image/video clips provided.

Thank you for this referral. If the clinical or image interpretation does not parallel your findings or if I can be of any further assistance, please contact me.

Eric Lindquist, DMV, DABVP(CFM), Cert. IVUSS,

CEO, Owner, Founder -- SonoPath.com

info@SonoPath.com



PATIENT

E.B. Mando

SPECIES

Canine

BREED

Tibetan Spaniel

SEX

Neutered Male

AGE

11 Years 4 Months

WEIGHT

20

INTERPRETED BY

Eric Lindquist, DMV,
DABVP(CFM), Cert.
IVUSS

IMAGING PERFORMED BY

Heather

HOSPITAL NAME

Animal Care Clinic of
Flanders

REFERRING VET

Dr. Hargadon

INVOICE

13997

DATE

02/27/26