



PATIENT

Dante Zubertz

SPECIES

Canine

BREED

Basenji

SEX

Male

AGE

7 years

WEIGHT

22.8 lbs

INTERPRETED BY

Eric Lindquist, DMV
DABVP, Cert. IVUSS

IMAGING PERFORMED BY

Brianna Gaines

HOSPITAL NAME

Healthy Pets VC Boca
North

REFERRING VET

Dr. Gaines

INVOICE

71999

DATE

2/27/26

PRESENTING CLINICAL SIGNS

- Patient presented for chronic diarrhea over the past month. CBC showed mild elevation in WBC. Patient is an intact male

ULTRASONOGRAPHIC EXAMINATION OF THE ABDOMEN

Urinary System

The **urinary bladder**, trigone, and pelvic urethra presented normal thicknesses and normal tone. The ureters were not visible which is normal. No uroliths or sediment were visualized and anechoic urine was present. No evidence of inflammatory or neoplastic changes was noted. Ureteral papillae were normal.

The **kidneys** revealed normal size and structure, corticomedullary definition and ratio for this age. The cortices presented largely uniform texture with normal echogenic relationship to liver and spleen. Medullary structure differed distinctly from the cortex and no evidence of pelvic dilation was present. The capsules were acceptably uniform without significant irregularities. The left kidney measured 5.4 cm. The right kidney measured 4.5 cm.

Adrenal Glands

Both **adrenal glands** were visualized and recognized as having normal shape, size, position and echogenicity for this breed. The phrenic vasculature, glandular echogenicity and detail were unremarkable. Capsule, cortex, and medullary definition were normal for this age patient. The left adrenal gland measured 0.45 cm. The right adrenal gland measured 0.6 cm.

Spleen

The **spleen** in this patient was uniformly enlarged with uniform parenchyma and was folded upon itself cranially. This is a positional variant and is not pathological. There was no evidence of significant disease.

Liver

The **liver** images submitted revealed subjectively normal liver size, contour, and structure. Parenchymal echogenicity was naturally coarse and hypoechoic to the spleen. Vascular and biliary tracts were of normal volume with no evidence of congestion. The gallbladder presented acceptably thin walls with primarily anechoic content. The cystic and common bile ducts were normal. No pathological hepatic lymphadenopathy was evident. No overt structural evidence of inflammatory, infiltrative or regenerative pathology was evident.



PATIENT

Dante Zubertz

SPECIES

Canine

BREED

Basenji

SEX

Male

AGE

7 years

WEIGHT

22.8 lbs

INTERPRETED BY

Eric Lindquist, DMV
DABVP, Cert. IVUSS

IMAGING PERFORMED BY

Brianna Gaines

HOSPITAL NAME

Healthy Pets VC Boca
North

REFERRING VET

Dr. Gaines

INVOICE

71999

DATE

2/27/26

Gastrointestinal

The **stomach** was unremarkable with a minor amount of ingesta. Transit of chyme was noted into the small intestine and appeared to be occurring normally. The wall thicknesses were fairly normal with minor areas of increased submucosal echogenicity.

Pancreas

The base and limbs of the **pancreas** were observed to be largely isoechoic to surrounding omental fat. Pancreatic duct and capsular contour were acceptably normal and parenchyma respected normal curvilinear patterns. No overt evidence of active inflammatory or neoplastic disease was noted.

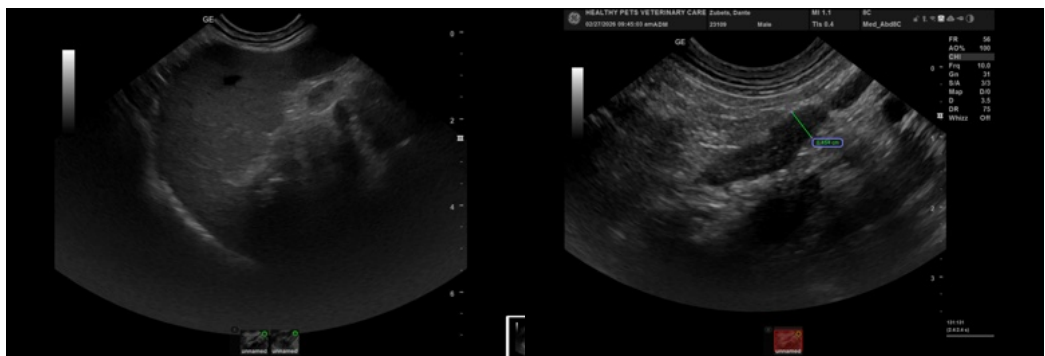
ULTRASONOGRAPHIC FINDINGS

Minor IBD GI pattern, no evidence of foreign bodies.

Otherwise, unremarkable abdomen.

INTERPRETATION OF THE FINDINGS & FURTHER RECOMMENDATIONS

Differentials for diarrhea include occult parasitism. Dietary indiscretion, dietary intolerance, antibiotic responsive colitis, intestinal dysbiosis and occult Addison's should all be considered as causes of diarrhea in this patient. A hydrolyzed diet trial may be in this patient's best interest +/- probiotics. 24-hour NPO and reintroduction of bland diet indicated. I recommend a baseline cortisol or ACTH stimulation test, a fresh fecal smear and fecal floatation analysis if not already performed





PATIENT

Dante Zubertz

SPECIES

Canine

BREED

Basenji

SEX

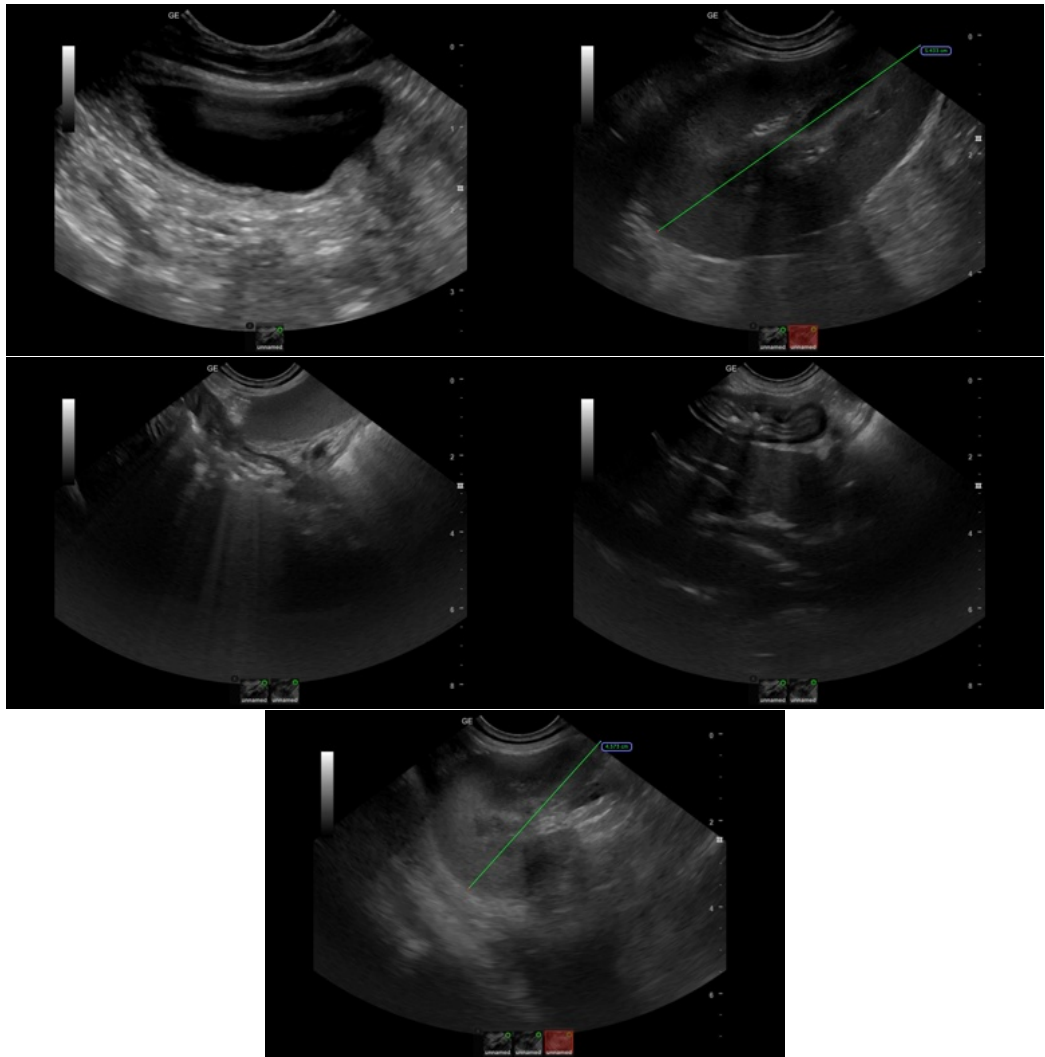
Male

AGE

7 years

WEIGHT

22.8 lbs



INTERPRETED BY

Eric Lindquist, DMV
DABVP, Cert. IVUSS

IMAGING PERFORMED BY

Brianna Gaines

HOSPITAL NAME

Healthy Pets VC Boca
North

REFERRING VET

Dr. Gaines

INVOICE

71999

DATE

2/27/26

The information and recommendations provided are based on the images presented by the referring veterinarian/sonographer. No evaluation can be communicated regarding pathology that was not visible in the image/video clips provided.

Thank you for this referral. If the clinical or image interpretation does not parallel your findings or if I can be of any further assistance please contact me.

Eric Lindquist, DMV, DABVP (CFM), Cert. IVUSS, CEO of SonoPath.com

info@SonoPath.com