



PATIENT

Charlie Muzyka

SPECIES

Feline

BREED

Domestic Shorthair

SEX

Neutered male

AGE

12 years

WEIGHT

7.5 lbs

INTERPRETED BY

Eric Lindquist, DMV
DABVP, Cert. IVUSS

IMAGING PERFORMED BY

Heather

HOSPITAL NAME

Animal Care Clinic of
Flanders

REFERRING VET

Dr. Villari

INVOICE

72065

DATE

2/27/26

PRESENTING CLINICAL SIGNS

- 1/6 systolic - synchronous, parasternal - no cough.
- prednisone for chronic IBD
- WBC 2.9

ULTRASONOGRAPHIC EXAMINATION OF THE HEART

The echocardiogram in this patient demonstrated normal **left atrial** size based on 3 separate LA measurements. The cranial and caudal **mitral** valve leaflets presented normal linear structure and kinetics. The **left ventricle** presented normal thicknesses with linear contour and was not dilated nor restricted. A minor amount of **myocardial** remodeling was noted. **Contractility** of the ventricular walls was adequate and in normal range for this patient evidenced by the fractional shortening measurement and subjective evaluation of the different regions and angles of the myocardium. The **left ventricular outflow** tract demonstrated normal laminar flow and subjective structural integrity. The **right atrium** and auricle revealed normal size, structure and content. No evidence of masses was noted or chamber overload. **Tricuspid** valvular assessment demonstrated adequate linear morphology and kinetics. The **right ventricle** was of normal size (1/3 diameter of LV), chordae structure, myocardial echogenicity and thickness. **Pulmonic** tract assessment revealed normal valve structure, laminar flow, and diameter (approx. 1:1 pa/ao ratio). No visible **pericardial** or free pleura fluid was noted or extra cardiac pathology in the visible planes. The cranial **mediastinum and pericardial regions** were free of masses in the visible window.

FELINE CARDIAC PARAMETERS	BODY WEIGHT	HR (BPM)	IVSd (cm)	LVIDd (cm)	LVWd (cm)	FS (%)	EF (%)
NORMAL PARAMETER	-----	150-240	0.3-0.6	1.0-2.1	0.25-0.6	35-67	80-100
PATIENT	7.5 lbs	200	0.4	1.4	0.4	50	90
FELINE CARDIAC PARAMETERS	LA/AO (M-mode)	LA/AO HEART BASE (Sisson)	LAD LA MAX 4 Chamber		LVOT VEL. (m/s)	RVOT VEL. (m/s)	IVRT (m)
NORMAL PARAMETER	<1.5	1.6	0.7-1.7		<1.6	<1.3	40-60
PATIENT	1.3	1.3	1.4		NM	0.7	NM
Adapted from June Boon, Veterinary Echocardiography, 1998 Sisson D et al. JVIM 1991; 5: 232, Jacobs et al. Am J Vet Res 1985; 46:1705							

ULTRASONOGRAPHIC FINDINGS

Normal echocardiogram.

Otherwise, structurally normal heart.



PATIENT

Charlie Muzyka

SPECIES

Feline

BREED

Domestic Shorthair

SEX

Neutered male

AGE

12 years

WEIGHT

7.5 lbs

INTERPRETED BY

Eric Lindquist, DMV
DABVP, Cert. IVUSS

IMAGING PERFORMED BY

Heather

HOSPITAL NAME

Animal Care Clinic of
Flanders

REFERRING VET

Dr. Villari

INVOICE

72065

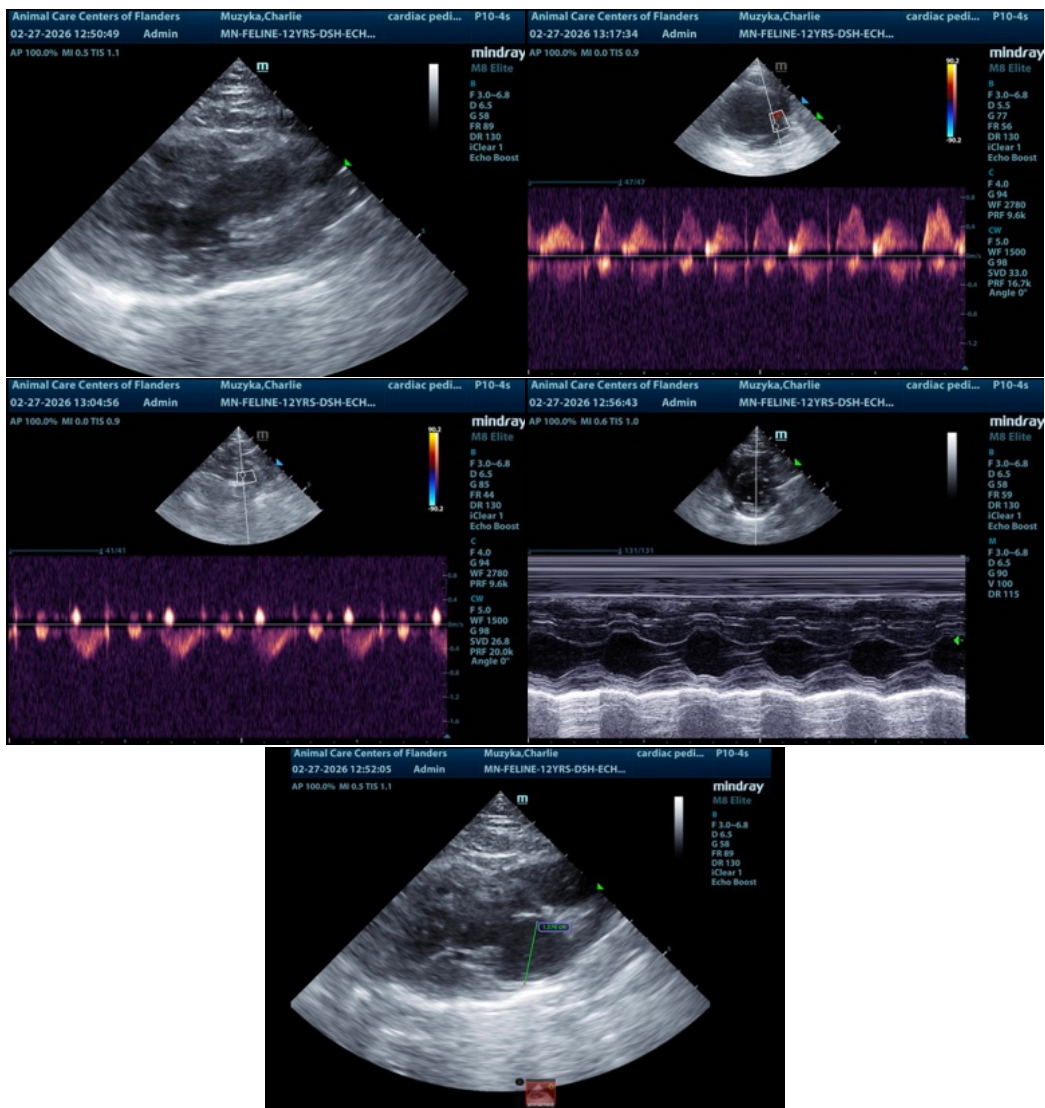
DATE

2/27/26

INTERPRETATION OF THE FINDINGS & FURTHER RECOMMENDATIONS

There was no detectable murmur is noted in this patient; however, it is likely idiopathic flow murmur, not clinically significant. There was no evidence of minor myocardial remodeling.

Benign flow murmurs are common in cats. This may be owing to volume shifts, tachycardia, benign (DRVOTO) right ventricular outflow changes, trivial turbulence in any of the valvular apparatuses, or possibly excessive stethoscope pressure against the chest according to a recent study These are physiologically benign and unrelated to specific pathology.



The information and recommendations provided are based on the images presented by the referring veterinarian/sonographer. No evaluation can be communicated regarding pathology that was not visible in the image/video clips provided.

Thank you for this referral. If the clinical or image interpretation does not parallel your findings or if I



PATIENT

Charlie Muzyka

SPECIES

Feline

BREED

Domestic Shorthair

SEX

Neutered male

AGE

12 years

WEIGHT

7.5 lbs

INTERPRETED BY

Eric Lindquist, DMV
DABVP, Cert. IVUSS

**IMAGING
PERFORMED BY**

Heather

HOSPITAL NAME

Animal Care Clinic of
Flanders

REFERRING VET

Dr. Villari

INVOICE

72065

DATE

2/27/26

can be of any further assistance please contact me.

Eric Lindquist, DMV, DABVP (CFM), Cert. IVUSS, CEO of SonoPath.com

info@SonoPath.com