



**PATIENT**

Zucca Torsiello

**SPECIES**

Canine

**BREED**

Shih Tzu

**SEX**

Spayed female

**AGE**

3 years

**WEIGHT**

13.6 lbs

**INTERPRETED BY**

Eric Lindquist, DMV  
DABVP, Cert. IVUSS

**IMAGING PERFORMED BY**

Marco Lichfield

**HOSPITAL NAME**

Sova

**REFERRING VET**

Dr. Sova

**INVOICE**

42993

**DATE**

2/27/23

**PRESENTING CLINICAL SIGNS**

History: Pet has a history of bladder stones urinary tract infections.  
Abnormal PE/Chem/CBC/UA Results: U/A shows BILI 2+, BLOOD 3+, GLU Trace and S.G 1.055

**ULTRASONOGRAPHIC EXAMINATION OF THE ABDOMEN**

**Urinary System**

The **urinary bladder**, trigone, and pelvic urethra presented normal thicknesses and normal tone. The ureters were not visible which is normal. No uroliths or sediment were visualized and anechoic urine was present. No evidence of inflammatory or neoplastic changes was noted. Ureteral papillae were normal.

The **kidneys** revealed normal size and structure, corticomedullary definition and ratio for this age. The cortices presented largely uniform texture with normal echogenic relationship to liver and spleen. Medullary structure differed distinctly from the cortex and no evidence of pelvic dilation was present. The capsules were acceptably uniform without significant irregularities. The left kidney measured 3.15 cm. The right kidney measured 3.66 cm.

**Adrenal Glands**

Both **adrenal glands** were visualized and recognized as having normal shape, size, position and echogenicity for this breed. The phrenic vasculature, glandular echogenicity and detail were unremarkable. Capsule, cortex, and medullary definition were normal for this age patient. The right adrenal gland measured 1.36 x 0.52 cm at the cranial pole and 0.45 cm at the caudal pole. The left adrenal gland measured 1.54 x 0.56 cm at the cranial pole and 0.62 cm at the caudal pole.

**ULTRASONOGRAPHIC FINDINGS**

Structurally unremarkable urinary tract.

**INTERPRETATION OF THE FINDINGS & FURTHER RECOMMENDATIONS**

There is no evidence of pathology.



**PATIENT**

Zucca Torsiello

**SPECIES**

Canine

**BREED**

Shih Tzu

**SEX**

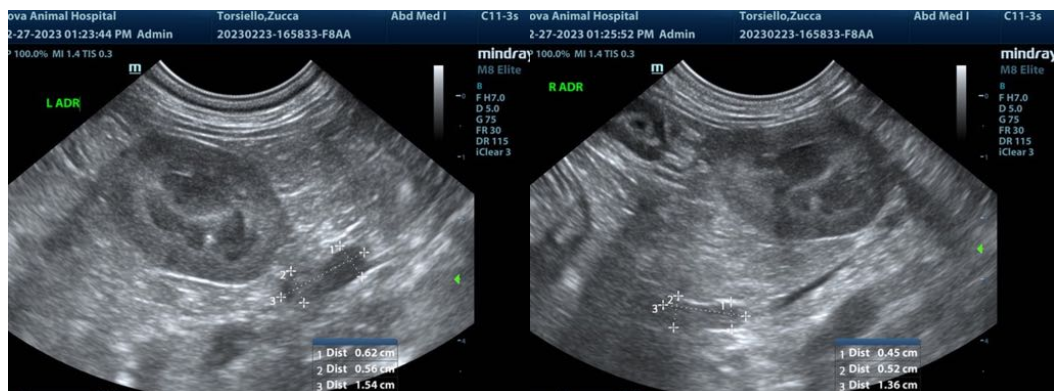
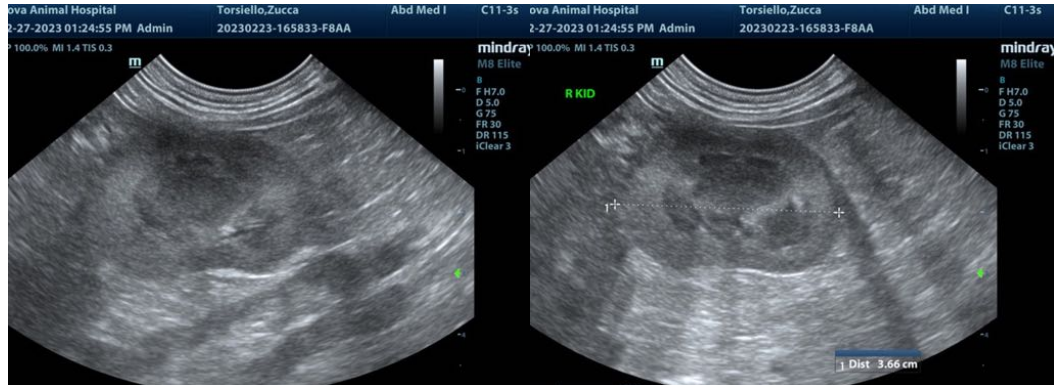
Spayed female

**AGE**

3 years

**WEIGHT**

13.6 lbs



**INTERPRETED BY**

Eric Lindquist, DMV  
DABVP, Cert. IVUSS

**IMAGING PERFORMED BY**

Marco Lichfield

**HOSPITAL NAME**

Sova

**REFERRING VET**

Dr. Sova

**INVOICE**

42993

**DATE**

2/27/23

The information and recommendations provided are based on the images presented by the referring veterinarian/sonographer. No evaluation can be communicated regarding pathology that was not visible in the image/video clips provided.

Thank you for this referral. If the clinical or image interpretation does not parallel your findings or if I can be of any further assistance please contact me.

**Eric Lindquist, DMV, DABVP, Cert. IVUSS, CEO of SonoPath.com**  
info@SonoPath.com